

## Fusion of maxillary primary central and lateral incisors bilaterally

Eliecer Eidelman, Dr Odont, MSD

### Abstract

*A case of bilateral fusion is presented, the definitions of fusion and gemination are reviewed, as well as the diagnostic criteria. The clinical implications of fused teeth include the probability of loss of arch length, caries susceptibility of the fissure, and missing corresponding permanent incisors.*

### Introduction

In 1963 Tannenbaum and Alling,<sup>1</sup> defined gemination as the formation of the equivalent of two teeth from the same follicle, with evidence of an attempt for the teeth to be completely separate, this indicated clinically by a groove or depression which could delineate two teeth. Radiographically, there appears to be only one pulp chamber. They stated that in gemination, if the bifid tooth is counted as one entity, the total number of teeth in the dental arch is otherwise normal.

The same authors<sup>1</sup> defined fusion as a union of two separate tooth buds at some stage in their development. Depending on the stage they are united, one tooth may have only one pulp chamber as a gemination, or there may be two pulp chambers, with union only of the dentin.

Fusion and/or gemination of primary teeth is more frequent than among permanent teeth. Data available for the primary dentition combined the prevalence of fused and geminated teeth, the conditions being relatively frequent, ranging from 0.5 percent to 2.5 percent according to the population surveyed.<sup>2,3,4</sup> Fusion of the lateral incisor and cuspid is the most common of these manifestations in the primary dentition, and symmetrical occurrence is often found.<sup>5</sup> This article reports on a case of bilateral fused primary incisors, with a discussion of clinical implications and further elaboration of the definitions of gemination and fusion.

### Case Report

The patient, R. K., is male aged 2 years and 3 months. The patient's history included the following: "the child had front joined teeth," is mentally retarded and suffers from muscular weakness, these

findings are manifested by ptosis, and inability to chew or speak. Physical examination revealed a ventricular septal defect. Oral examination demonstrated that the maxillary primary central and lateral incisors were joined on both the right and left sides of the arch. The corresponding lateral incisors were missing. From the clinical examination a preliminary diagnosis of fusion was made. The fused left teeth exhibited a small notch in the incisal third, corresponding to the outline of the originating teeth, while the right fused teeth demonstrated a fissure running through the whole length of the original tooth outline (Figure 1).

Radiographic examination (Figure 2) indicated the presence of a separate root canal and root in the right fused teeth. The left fused teeth showed less marked separation of root canal and root which may be the result of the angle that the radiograph was taken. No radiographic evidence of the maxillary permanent lateral incisors could be detected. All other oral findings were within normal limits.

### Discussion

The present case illustrates the frequent confusion of identification between fusion and gemination. In the present report the term fusion is used, in accordance with the definitions used by Levitas<sup>6</sup> who stated that "by appearance it would seem that there is a missing tooth and probably two root canals." However, one could speculate that this report represents an example of gemination of the maxillary primary

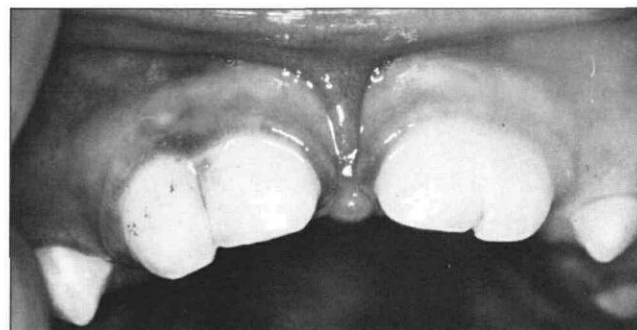
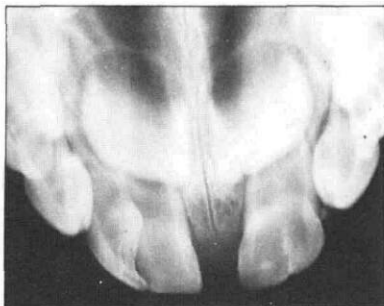


Figure 1. Fusion and/or gemination of the maxillary primary incisors.

**Figure 2.** Occlusal radiograph demonstrating varying degrees of separation of root canals and roots.



central incisors in a case of missing primary lateral incisors. This assumption is strengthened by the fact that the permanent lateral incisors appeared to be congenitally missing, thus increasing the probability of missing primary lateral incisors.<sup>1</sup>

Fused primary teeth present several problems to the clinician. Since exfoliation times are usually different for each tooth involved in the fusion, consideration should be given to the variations in root resorption. In the present case, the exfoliation times for the central and lateral incisors are similar and no special problems are expected. However, fusion of the primary lateral incisor and cuspid might result in early

loss of the cuspid with potential loss of arch length or midline shift. To prevent this complication, preservation of arch space and form should be considered.

---

Dr. Eidelman is acting chairman, department of pedodontics, Hebrew University, Hadassah Faculty of Dental Medicine, P.O. Box 12 000, Jerusalem, Israel. Requests for reprints should be sent to Dr. Eidelman.

---

### References

1. Tannenbaum, K. A. and Alling, E. E. Anomalous tooth development: case reports of gemination and twinning, *Oral Med and Oral Path*, 16:883-887, 1963.
2. Grahnen, H. and Granath, L. Numerical variations in primary dentition and their correlation with the permanent dentition, *Odont Rev*, 12:248-257, 1961.
3. Clayton, J. M. Congenital dental anomalies occurring in 3,557 children, *J Dent Child*, 23:206-208, 1956.
4. Niswander, J. D. and Surijaker, C. Congenital anomalies of teeth in Japanese children, *Amer Phys Anthropol*, 21:569-574, 1963.
5. Pindborg, J. J. *Pathology of the dental hard tissues*, Copenhagen: Munksgaard, 1970, pp 47-54.
6. Levitas, T. C. Gemination, fusion, twinning and concrescence, *J Dent Child*, 32:93-100, 1965.

## Quotable Quote

It is now clear, 31 years later, that low-dose external irradiation to the thyroid is carcinogenic. Hemplemann et al., found 19 carcinomas and 22 benign thyroid tumors in 2878 infants given x-ray treatment for thymic enlargement. Only two benign tumors were noted in their untreated siblings. Numerous other studies conducted since 1950 have documented an increased incidence of benign and malignant neoplasms in children who have received external head and neck irradiation for other benign conditions, such as enlarged tonsils and adenoids, tinea capitis, hemangiomas, and whooping cough. Moreover, these reports span a period of almost 30 years and show that an abnormally high incidence of thyroid tumors continues to occur in patients irradiated more than 25 years earlier.

From Editorial, *The New England Journal of Medicine*, Vol. 303, #4, pp 217-218, July 24, 1980.