

A new preparation for primary incisor jackets

Walter A. Doyle, D.D.S., M.S.D.

In 1968¹ a preparation was introduced which utilized an undercut area around the gingival shoulder for the retention of primary acrylic jackets. An additional aid in retention has been the use of acid etching.² When enough of the clinical crown remains these techniques lead to the retention of the restoration. However, rapid abrasion of the resin can sometimes lead to excessively short crown length and poor esthetics. Thus, the following new preparation is presented.

When the primary incisor (Fig. 1) for an acrylic jacket crown is prepared, all the infected carious areas are removed and a gingival shoulder is prepared with a No. 330 bur which leaves a circumferential undercut. The remaining labial, lingual, and proximal enamel is reduced in thickness, but a thin layer is left wherever possible (Fig. 2). The incisal edge is *not* shortened.

The prepared tooth then receives a pulp dressing and the enamel is acid etched for 15 sec. Primary teeth which present a high caries rate etch very easily. The ideal amount of time and acid concentration for such teeth remains to be determined. It should also be pointed out that all areas which are being etched are prepared, thus the "prismless" layer of enamel is of no concern. After etching, a preformed acrylic jacket crown* is selected (Fig. 3). The jacket should fit well gingivally, but must be excessively long in order to fit over the unreduced incisal edge. A very thin layer of unfilled resin† is painted over the entire stump and allowed to set. This allows the heat from the setting reaction to dissipate and creates an additional buffer to protect the pulp from the exothermic reaction of

the greater bulk of resin later placed in the preformed jacket. The preformed jacket is tried on again to be sure that it will still fit. If it does not fit, the inside of the jacket can be enlarged with a bur, or some of the resin can be removed from the tooth. Next, the jacket

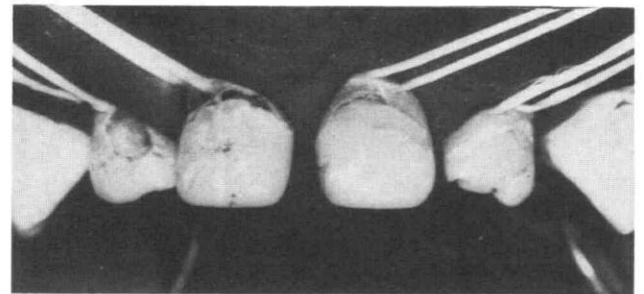


Fig. 1. Preoperative view of previously restored primary maxillary incisors with secondary carious lesions.

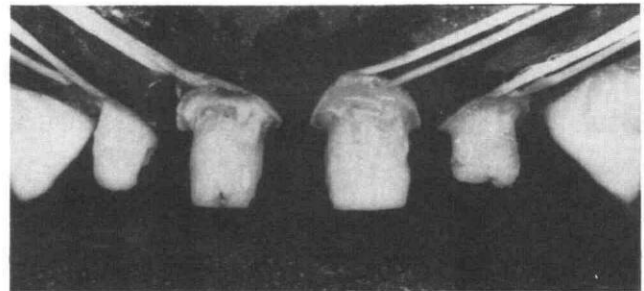


Fig. 2. Primary maxillary incisors prepared for acrylic jacket. Note that the incisal edge has not been shortened, a considerable amount of enamel remains and there is a slight undercut around the gingival margin.

* Medidenta, 39-23 62nd Street, Woodside, New York 11377.

† Bonfil, L. D. Caulk Company, Milford, Delaware 19963.

is filled with either unfilled or composite resin and seated on the stump. The resin is allowed to set. There is now one continuous area of resin extending from the exterior surface to the etched surface. There is no cement.

The jacket is shortened with a bur (Fig. 4) until the original incisal enamel edge is reached. The remaining anatomy is established with a No. 169 L Bur (Fig. 5) at slow speed and the bur and No. 10 and No. 12 scalpels are used to finish the gingival margins. The restoration is polished (Figs. 6 and 7). The type of preformed jacket used is not made of polycarbonate, but is a methylmethacrylate resin which the author has found easier to polish.

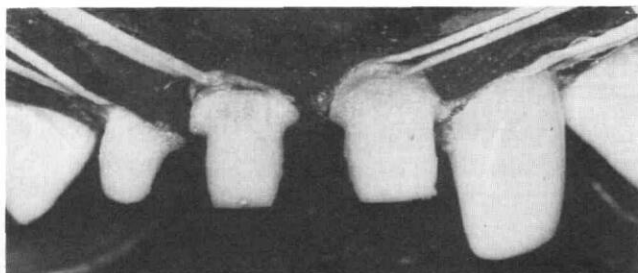


Fig. 3. A thin layer of unfilled resin has been applied to the prepared incisors and a preformed acrylic jacket has been selected for the lateral incisor.




Fig. 4. The preformed jackets have been filled with resin and allowed to cure to the resin previously applied to the stump. The excessive length is reduced with a bur.

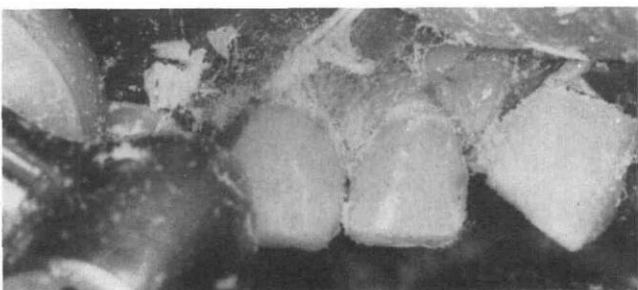


Fig. 5. The proper gingival contour is established with a bur while the dam and gingiva are retracted by pressure on the dental floss.




Fig. 6. The restorations are further contoured and polished.

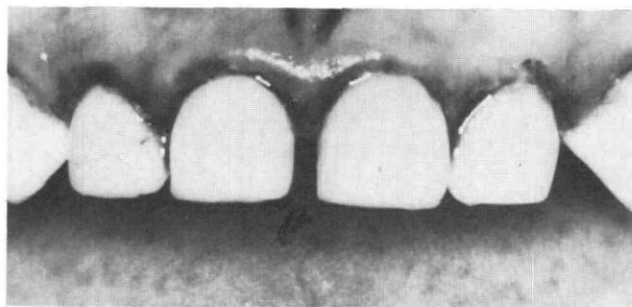


Fig. 7. The immediate postoperative view of four primary acrylic jackets on the maxillary incisors.

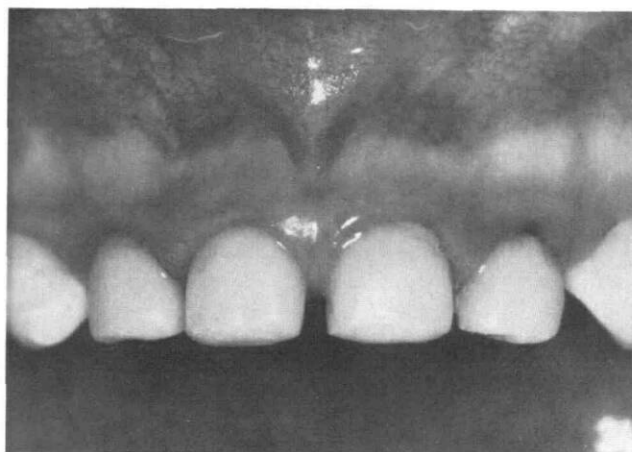

Fig. 8. An 18 month postoperative view of the same four primary acrylic jackets shown in Fig. 7.

The remaining incisal enamel retards later abrasion and provides greater retention. As abrasion occurs, there is no cement to wash out and allow the restoration to be lost. Conversely, the etched resin provides a satisfactory resistance to leakage as abrasion occurs. The use of this technique improves significantly the results (Fig. 8) obtained by the author with the use of preformed primary jackets.

References

1. Doyle, W. A.: "Pedodontic Operative Procedures," In *Current Therapy in Dentistry*, Vol. III, Chap. 38, C. V. Mosby Co., St. Louis, 1968.
2. Doyle, W. A.: "Acid Etching in Pedodontics," *Dent Clin North Am*, 17:93-104, 1973.



Dr. Walter A. Doyle is in full time private practice in Pedodontics and Orthodontics in Lexington, Kentucky, and is also a visiting Professor of Pedodontics at Henry Goldman School of Dentistry, Boston University. Requests for reprints should be addressed to Dr. Walter A. Doyle, 1628 Nicholasville Road, Lexington, Kentucky 40503.

National Academy of Sciences Study Concludes Saccharin to be Carcinogen

Washington—Saccharin may have some value in toothpaste but, according to a National Academy of Sciences (NAS) panel, saccharin can cause cancer in animals and probably in humans.

Though a relatively weak carcinogen, the study said, saccharin's greatest threat to humans may be to children under the age of ten, who the NAS panel says are the heaviest consumers over long periods of time of saccharin-sweetened soft drinks. The study, sought by Congress, increases the likelihood the government will impose new restrictions on use of the artificial sweetener, the only nonnutritive sweetener permitted in the American food supply. Canada has banned the use of saccharin as a food additive.

In addition to acting by itself, saccharin promotes the cancer-causing effects of some other carcinogenic compounds in rats. Saccharin alone, and not any impurities resulting from the way it is made, is the carcinogen.

"Whether an initiator or promoter, saccharin must be viewed as a potential carcinogen in humans, but one of low potency in comparison to other carcinogens," the report said.

"Although saccharin would be expected to be of low potency in humans, even low risks applied to a large number of exposed persons may lead to public health concerns" it added. Because young children are in-

creasingly heavier consumers of the substance, the panel advised that "public health officials should take a prudent course of action" on saccharin.

"This may be particularly important because of the anticipated long latent period between exposure to the potential carcinogen and the manifestation of cancer and because of the recently recognized promoter effects that have been exhibited by saccharin in laboratory tests," the report said.

A second report, due February 1, will address such public policy alternatives as a ban or restrictions on the use of saccharin, or doing nothing. Congress's moratorium on the FDA proposal ends next May 23.

However, the use of saccharin in drugs and toothpastes "presents insignificant risks and possible benefits," the report said. Saccharin may be useful in promoting the use of toothpastes and could have a benefit as a sugar substitute in snack foods or sweet beverages that frequently contact the surface of the teeth, the panel said.

Saccharin has been used as a sugar substitute in the United States for more than 70 years and once before was banned from foods. That happened in 1912, but during World War 1, a reduced sugar supply prompted a lifting of the ban.

—from *ADA News*, November 27, 1978