



Segmental odontomaxillary dysplasia (hemimaxillofacial dysplasia): case report

Michael S. DeSalvo, DMD Maria A. Copete, DDS, MS Robert E. Riesenberger, DDS
Deborah B. Cleveland, DDS Sow-Yeh Chen, PhD

Segmental odontomaxillary dysplasia (SOD) has been delineated from other bone and odontogenic dysplasias, and only recently has been described as a separate entity.^{1,2} This condition was first introduced as hemimaxillofacial dysplasia (HD) by Miles et al. in 1987.¹ Reports have appeared directed primarily at oral and maxillofacial surgeons and oral pathologists, so the condition may be relatively unknown to pediatric dentists.

SOD is characterized by unilateral maxillary enlargement, gingival hyperplasia, facial asymmetry, ipsilateral dental abnormalities, and an unusual radiographic bone pattern.² Immature woven bone forming irregular patterns is seen histologically. To date 10 cases have been reported, and in one patient, ipsilateral facial hypertrichosis was recorded.¹ With one exception, all patients have been children or adolescents.² None of the cases demonstrated a hereditary pattern.

The incidence is unknown. Pediatric dentists and orthodontists who have encountered these patients may have misinterpreted the condition as hereditary gingival fibromatosis because of the maxillary enlargement and thickened gingivae. The poor-quality bone encountered on biopsy may have suggested atypical fibrous dysplasia.

This case is reported in the pediatric dental literature in an effort to encourage the reporting of additional cases and define the range of clinical manifestations of this unusual condition.

Case report

Chief complaint and past medical history

A 7-year-old white female was referred to an oral and maxillofacial surgeon by her pediatric dentist because of an asymptomatic expansion of the left face and maxilla (Fig 1). At age 4, the parents had sought care from a pediatric dentist (R.R.) because the primary molars in the child's left maxilla failed to erupt. The gingival tissue over the unerupted molars was described as excessive and fibrous and was removed surgically to permit molar eruption. Histologic examina-

tion revealed uninfamed gingival tissue with one area of nonspecific fibrosis. Another area of loose basophilic mucoid material and reduced enamel epithelium was observed. A diagnosis of eruption cyst was made.

Physical and radiographic examination

Examination at age 7 by an oral surgeon revealed that the patient's left upper lip was hypopigmented compared with the right side (Fig. 1). A caries-free mixed dentition appropriate for the patient's age was observed. The left maxillary alveolus was markedly expanded compared with the right, with several protuberances visible on the buccal aspect. The degree of expansion was greater than at age 4. The two left primary molars did not appear to be completely erupted and were somewhat malpositioned. The two primary molars on the left side were larger in their mesiodistal measurement (12 mm) than the primary molars on the right (9 mm). The enamel of the primary molars was hypoplastic, appearing yellowish. The first permanent molar was not erupted. The marginal gingiva on the buccal aspect of the left primary canine appeared somewhat thickened. No pain was elicited when the area was digitally palpated.

Periapical and panoramic radiographs revealed an ill-defined, coarse, irregular trabecular bone pattern superimposed over the primary left maxillary molar roots and extending superiorly to the floor of the maxillary sinus (Fig 2). The sinus floor appeared elevated in contrast to the uninvolvement side. The primary molar root images were indistinct. It

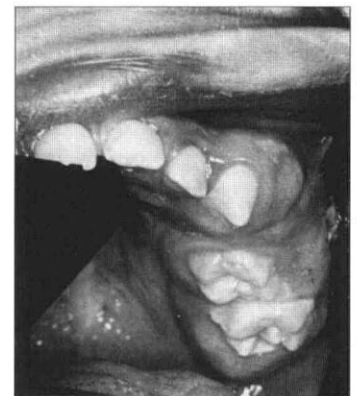

Fig 1. Intraoral photograph showing the left maxillary expansion, gingival thickening, and the depigmented area on the left upper lip.

was difficult to determine whether the premolar tooth buds were present or just hypoplastic. Outlines of the developing maxillary canine and first and second permanent molars could be visualized.

A biopsy of the area was obtained through a buccal approach under general anesthesia concomitant to extracting a primary molar. Histologic examination revealed fragments and trabeculae of immature woven bone forming irregular patterns (Fig 3). Mature lamellar bone was not present. Uninflamed fibrous tissue was present along with a portion of a tooth root. A final diagnosis of segmental odontomaxillary dysplasia was made based on the correlation of the clinical, radiographic, and microscopic findings.

Discussion

The initial problem was establishing a differential diagnosis. The following conditions were considered during the clinical evaluation of the patient:

Monostotic fibrous dysplasia

Fibrous dysplasia or a related fibro-osseous lesion was considered early because of the unilateral maxillary expansion and the atypical bone pattern noted on radiographic examination.³ In fibrous dysplasia the teeth in the area are normal. In large expansions, the teeth can be displaced secondarily. Biopsy, however, did not reveal the typical histologic "Chinese character" pattern encountered in fibrous dysplasia.⁷

Regional odontodysplasia

Clinical and radiographic features were somewhat suggestive of regional odontodysplasia.^{4,5} In that condition, the affected teeth may fail to erupt and exhibit a radiographic pattern described as pale, wispy tooth images with a lack of contrast between dentin and enamel. Soft tissue swelling also has been reported.⁶ The histology, however, did not indicate regional odontodysplasia. The only tooth material seen was a segment of tooth root, and the predominant tissue consisted of immature woven bone.

Gingival fibromatosis

Because of the maxillary enlargement and fibrous gingivae in the canine area, this condition was briefly considered.⁷ Review of the radiographs and histology were sufficient to rule out this condition.

Central hemangioma

Vascular lesions of this type are most often noted in patients between 10 and 20 years of age.⁷ Radiographic imaging may show a honeycomb or soap-bubble appearance, and sometimes resorption of tooth roots in the area. Before biopsying the lesion, aspiration was attempted but no excessive blood flow occurred.

Tumor of bone

A variety of benign tumors that arise primarily within bone were considered.⁷ Included in this list were ossifying fibroma, cementifying fibroma, odontogenic

myxoma, chondroma, developing odontoma, and calcifying epithelial odontogenic tumor. Results of the tissue examination along with the clinical and radiographic findings effectively ruled these lesions out.

The clinical significance of SOD to pediatric dentists involves several factors.

Facial asymmetry is reported in most cases. The maxillary enlargement that causes the asymmetry needs evaluation to rule out fibrous dysplasia or a tumor of maxillary bone. There are a number of reported dental abnormalities such as enamel defects, absence of one or more permanent teeth, and distal displacement of permanent molars that may require consultation with an oral surgeon and orthodontist. Gingival enlargement (fibromatosis) may present esthetic and functional problems. The hypertrichosis reported in one patient,¹ and the area of hypopigmentation reported in this case suggests a systemic or endocrine aberration that needs appropriate evaluation.

The etiology of segmental odontomaxillary dysplasia is not clear at this time because of the few cases reported. In none of the 10 cases reported is a genetic

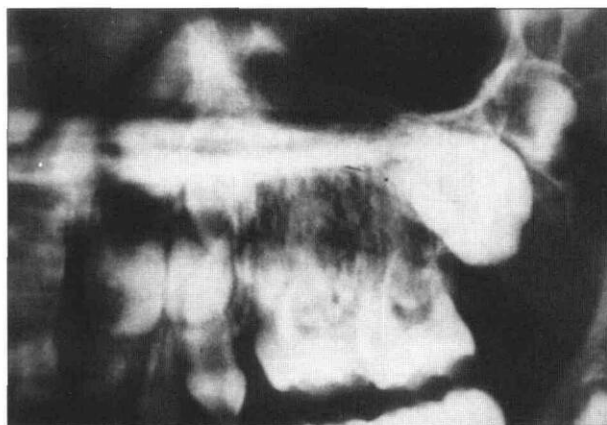


Fig 2. Periapical radiograph of the left maxillary molar region. A coarse, irregular bone pattern is seen. Premolars are absent or extremely hypoplastic.

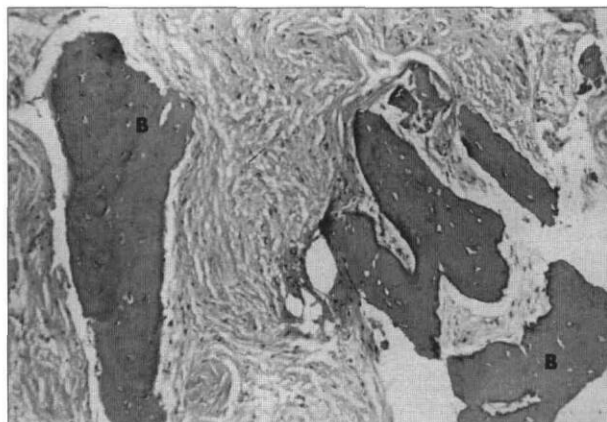


Fig 3. Photomicrograph showing uninflamed fibrous stroma and irregular trabeculae of woven bone (B). There is no osteoblastic rimming of the bone trabeculae (original magnification H&E x33).

predisposition apparent.^{1,2} All appeared isolated with no other family members affected. Gibbard et al.⁴ discussed possible etiologic factors for regional odontodysplasia, which shares some clinical features with SOD and does not appear to be genetically determined. They suggested an abnormal blood supply to the developing maxilla might be the cause but offered no proof. They also suggested that rubella infection during pregnancy might be contributory. Until more cases of SOD are reported, conclusions regarding etiology cannot be drawn.

The incidence of SOD is unknown.^{1,2} Other cases may have gone unrecognized or been misdiagnosed. Since the previous 10 cases were reported in a publication principally aimed at oral and maxillofacial surgeons and oral pathologists, additional case reports should be encouraged to determine the natural history of SOD.

Dr. DeSalvo has a private practice of oral and maxillofacial surgery in Doylestown, Pennsylvania. Drs. Copete, Chen, and Cleveland are involved with the department of pathology, oral pathol-

ogy section, Temple University School of Medicine, Philadelphia. Dr. Riesenberger maintains a pediatric dental practice in Doylestown.

1. Miles DA, Lovas JA, Cohen Jr MM: Hemimaxillofacial dysplasia: a newly recognized disorder of facial asymmetry, hypertrichosis of the facial skin, unilateral enlargement of the maxilla, and hypoplastic teeth in two patients. *Oral Surg Oral Med Oral Pathol* 64:445-48, 1987.
2. Danforth RA, Melrose RJ, Abrams AM, Handlers JP: Segmental odontomaxillary dysplasia. Report of eight cases and comparison with hemimaxillofacial dysplasia. *Oral Surg Oral Med Oral Pathol* 70:81-85, 1990.
3. Waldron CA: Fibro-osseous lesions of the jaws. *J Oral Maxillofac Surg* 43:249-62, 1985.
4. Gibbard PD, Lee KW, Winter GB: Odontodysplasia. *Br Dent J* 135:525-32, 1973.
5. Crawford PJM, Aldred MJ: Regional odontodysplasia: a bibliography. *J Oral Pathol Med* 18:251-63, 1989.
6. Neupert III EA, Wright JM: Regional odontodysplasia presenting as a soft tissue swelling. *Oral Surg Oral Med Oral Path* 67:193-96, 1989.
7. Neville BD, Damm DD, Allen CM, Bouquot JE: *Oral & Maxillofacial Pathology*. Philadelphia: WB Saunders Co, 1995. pp 132, 443, 478.

Stricter standards on children's toys could save lives

BALLOONS CAUSE MORE CHOKING DEATHS IN CHILDREN THAN ANY OTHER NONFOOD PRODUCT

Researchers are urging the U.S. government to regulate balloons and tighten restrictions on other products made for children after finding that many choking deaths are caused by objects that meet government standards, according to a recent article in *The Journal of the American Medical Association*.

Frank L. Rimell, MD, formerly of Children's Hospital of Pittsburgh, now with the University of Minnesota, Minneapolis, and colleagues conducted what is believed to be the first analysis of the shapes, consistencies, and sizes of objects causing choking deaths in children.

The researchers examined the medical records of 165 children who underwent endoscopy for foreign body aspiration or ingestion at Children's Hospital of Pittsburgh from 1989 to 1993. They also examined records from the Consumer Product Safety Commission (CPSC) on 449 children, aged 14 years and younger, who choked to death on nonfood objects between 1972-1992.

They found that conforming objects such as balloons were responsible for the most deaths (29%), followed by round objects such as balls and marbles (19%), and toy products, parts, or characters (20%). The remaining 32% of the deaths were caused by objects not intended for use by young children.

Of the 165 children treated at Children's Hospi-

tal, the items most often recovered were coins and food such as nuts, vegetable or fruit pieces, seeds and popcorn.

The researchers found that in both groups, two-thirds of the children were 3 years of age or younger; however, they found that children older than age 3 were twice as likely to die from balloon asphyxiation than children younger than age 3. In two cases, children died after choking on latex examining gloves given to them in physicians' offices.

"These findings indicate a need for greater public awareness of the dangers balloons pose to children and a search for solutions to the problem. Clinicians should keep examination gloves and similar supplies out of reach of children and caution others caring for or interacting with children about the hazards of these objects," the authors write.

After conforming objects, round objects posed the greatest risk of choking death by a nonfood item. A computer analysis of 101 rigid, three-dimensional objects which had asphyxiated children found that 14 had passed the government's Small Parts Test Fixture (SPFT), which is a cylinder with a diameter of 3.17 cm and a depth between 2.54 and 5.71 cm. Objects that are too large to fit in the cylinder pass the SPFT and are deemed acceptable for young children.

The researchers write: "All 14 of these deaths might have been prevented if the SPFT had been 4.44 cm in diameter and 7.62 cm in length."