

Oral self-mutilation in a child with congenital toxoplasmosis: a clinical report

Pamela K. DenBesten, DDS, MS
F. Thomas McIver, DDS, MS

Abstract

This clinical report involves self-mutilation of the lips and oral mucosa by a child who presented at 18 months with profound retardation secondary to congenital toxoplasmosis. The etiology of self-mutilation, dental management, and the need to individualize treatment are discussed.

Self-mutilation — repetitive acts which result in obvious physical damage to the individual's body — is seen in 7.7-19% of the mentally retarded population.¹⁻⁴ As the severity of mental retardation increases so does the incidence of self-mutilation. Maisto et al. found that approximately 96 per cent of the self-mutilating residents in a state institution were severely or profoundly retarded, with the remaining 4 per cent moderately retarded.²

Etiologies of self-mutilation may include organic or biologic factors not necessarily associated with mental retardation. These include a class of self-mutilative activities occurring with syndromes in which biochemical or enzymatic deficiencies have been identified, such as in Lesch-Nyhan syndrome and de Lange's syndrome.⁵ However, much self-mutilation cannot be attributed directly to biochemical factors. Several interpretations can be made concerning the relationship between self-mutilation and level of intellectual functioning. It may be that biological factors such as conspicuous impairment of sensory apparatus of the nervous system contribute to self-mutilation. Maisto et al. found that residents in a state institution who exhibited self-mutilation were more likely to have brain damage associated with low intellectual functioning.²

Self-mutilation also may be a learned behavior. In a severely or profoundly retarded individual, self-mutilation is one of the few behaviors reliably reinforced (attention is gained).^{2,4} The fact that behavior modification techniques are successful in terminating

self-mutilation adds empirical support to this possibility.^{6,8-10}

Various techniques are used in behavior modification of self-mutilation. These include continuous reinforcement while self-mutilative responses are absent and withdrawal of reinforcement upon self-mutilation,^{7,8} differential reinforcement of other behavior, extinction,⁹ and painful electric shock.⁸⁻¹⁰ No method is routinely successful for all individuals and frequently more than one type of behavior modification is used.

Other methods of treatment for self-mutilation include the use of restraints, protective padding, and sedation. Use of restraints will control direct injury, but will not modify the underlying abusive behavior. There is little evidence to demonstrate that the long-term benefits from medication (primarily neuroleptics) outweigh the risks of these drugs to self-mutilative individuals.^{1,3}

A frequent manifestation of self-mutilation is biting or chewing the lips, buccal mucosa, or tongue. Although the biting behavior may be seen in congenital absence of pain, it is associated more frequently with normal sensation since the person may scream as if in pain when biting. The biting may become so severe that behavior modification techniques are inadvisable due to the amount of damage which may occur if the self-mutilation is ignored. Because of this compulsive biting behavior, a dentist may join the team of professionals attempting to eliminate self-mutilation. A review of the literature describing treatment of these cases indicates that each presents unique challenges—no one treatment is indicated for self-mutilation due to biting of the lips and tongue. Some authors report extraction of all primary teeth in an effort to reduce trauma.^{11,12} Others have suggested extracting only the anterior teeth to prevent chewing of the lip.^{11,13} Budnick reported successful prevention of lip mutilation by covering the dentition with acrylic

splints.¹⁴ In a review of cases involving Lesch-Nyhan syndrome, Dicks suggested a combination of these various treatments dependent on the severity and persistence of the self-mutilative behavior.¹⁵

Clinical Report

An 18-month-old, profoundly retarded, white male was referred to the Department of Pedodontics at the University of North Carolina School of Dentistry for examination and possible treatment. The patient had been biting his tongue since 14 months of age. The mother first noted the problem at 14 months when the child amputated the anterior portion of his tongue with his teeth and engaged in persistent wrist biting.

The past medical history revealed that at age two months the child was diagnosed as having congenital toxoplasmosis. This systemic fetal infection is caused by the parasite *Toxoplasma gondii*. Typical manifestations include chorioretinitis, cerebral calcification, psychomotor retardation, and convulsion. Self-mutilation is not a reported characteristic of congenital toxoplasmosis.

Oral examination revealed lips, cheeks, and oral mucosa within normal limits. However, there was ulceration and laceration of the anterior one-fourth of the tongue. The maxillary and mandibular primary central incisors were erupted and the trauma was caused by the child's scraping his tongue over the mandibular incisor (Figure 1).

At the time of the dental examination, the child was being treated with diazepam to decrease self-mutilation. This, along with other medications (including thioridazine), seemed to have no beneficial effect. After discussion with the child's parents, his physician, and the psychologist working with the family, a decision was made to adopt a conservative mode of dental treatment. The treatment goal was to fabricate an appliance which would prevent tongue biting and allow behavior modification therapy. The behavior modification included withdrawal of attention when self-mutilation occurred. Aversive therapy also was attempted, such as placing lemon juice or dish soap in the mouth after biting occurred. The parents were anxious to avoid tooth extraction and were willing to work with the team in any way pos-

sible to allow conservative treatment.

It had been noted that the child would not chew his tongue when a nipple was placed in his mouth. Therefore, a maxillary acrylic splint with a face-bow embedded in the facial aspect of the splint was fabricated. The face-bow allowed extraoral retention similar to that used in a high-pull headgear appliance. The nipple was retained with wire embedded in the acrylic (Figures 2 & 3).

Initially, the appliance was successful in eliminating tongue biting. However, after two weeks of wear, the child began pushing his lower lip under the appliance and chewing on his lip (Figure 4). The child's father revised the appliance, replacing the nipple with a rubber teething ring wired to the face-bow of the

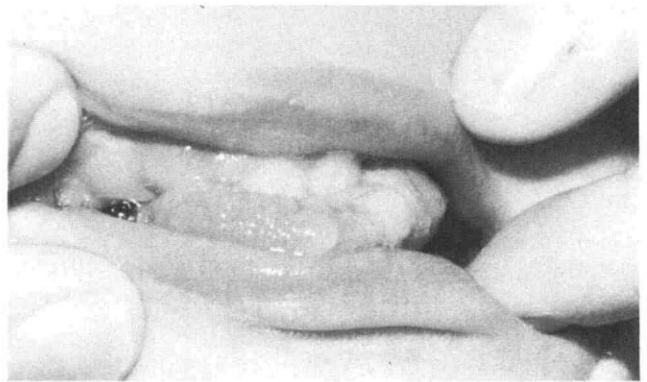


FIGURE 1. The trauma to the anterior one-fourth of the tongue was caused by the child's scraping his tongue over the erupted incisors.

acrylic appliance (Figure 5). It was necessary to restrain the child's arms to prevent him from manually pushing his lower lip under the teething ring and chewing on it.

The modified appliance functioned well. Three months after the initial appointment, there was no tongue biting and the child's lip was healing without further trauma. Since the patient's primary mandibular laterals and first molars had erupted, a lower acrylic splint was fabricated as described by Budnick to eliminate the need for restraining the child's arms.¹⁴

It was at this time that the child was placed in a respite care center for one month. Because the staff

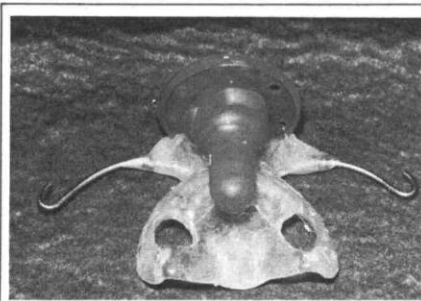
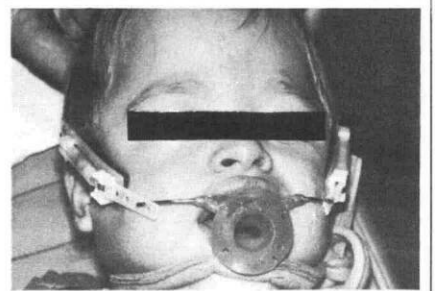


FIGURE 2. (left) Appliance (with the nipple in place) to discourage tongue scraping.

FIGURE 3. (right) Extraorally retained appliance in place.



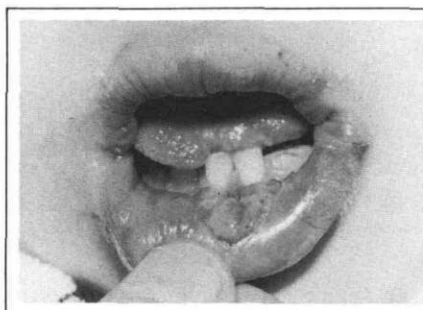


FIGURE 4. (left) Trauma to the lower lip after the child pushed his lip under the appliance; note the healing which has occurred at the anterior portion of the tongue.

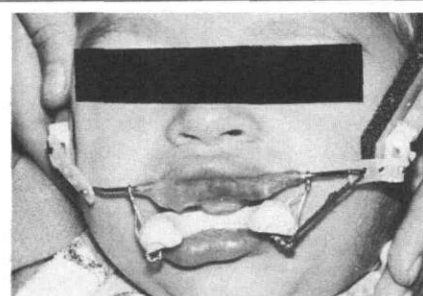


FIGURE 5. (right) Appliance as revised by the child's father with a teething ring in place.

experienced difficulties in removing and reinserting the appliance for feeding, it was not placed in the child's mouth during the day. At the end of the respite care period the patient presented to the dental clinic with a laceration above the vermilion border of the lip and a perforation through the lip below the border (Figure 6). To prevent further tearing of the lip, all primary mandibular incisors were extracted and the lip wound was closed surgically. The appliance no longer fit and was discontinued.

After extraction of the mandibular incisors the child did not engage in self-mutilation for approximately two weeks. Since the child then began chewing on his lower lip with his maxillary incisors, those teeth were extracted. Again, for approximately two weeks the patient did not engage in any self-mutilative behavior. It was no longer possible for the child to bite his lip, but he began biting his tongue, fingers, and cheeks with his molars and canines. Due to the failure of behavior modification techniques and appliance therapy the remaining primary teeth were extracted. Following the extractions, the child showed no further oral trauma. He exhibited some hair pulling which was controlled by restraining his arms.

Discussion

An 18-month-old child with profound mental retardation due to congenital toxoplasmosis presented with a tongue amputation and a persistent oral ulcer due to the patient's scraping his tongue over his lower incisors. Self-mutilative behavior previously has not been reported to be associated with congenital toxoplasmosis. Behavior modification and appliance therapy was instituted with full parental cooperation, but met with limited success. Subsequent episodes of lip and cheek biting necessitated extraction of all primary teeth.

In treating children with self-mutilative behavior, it is important to realize that each case is unique. The final treatment should be based on a team approach after carefully reviewing the circumstances involved in each case. This includes assessment of the physical needs of the child as well as the psychological needs of the family. For children exhibiting self-mutilative behavior involving the oral cavity, the treatment plan

of choice will depend on the relative success of behavior modification for the child, the ability to prevent injury using appliances and restraint, and the cooperation of those directly responsible for the child's daily care.

The authors wish to acknowledge the advice and cooperation of Dr. Jacelyn Wedell-Monnig, staff psychologist at the Division for Disorders in Development and Learning, University of North Carolina, who coordinated treatment of this patient.

Dr. DenBesten is a clinical assistant professor and research fellow, and Dr. McIver is a professor, Department of Pedodontics, University of North Carolina; Chapel Hill, NC 27514. Reprint requests should be sent to Dr. McIver.

1. Ballinger, B.R. Minor self-injury. *Br J Psychiatry* 118:535-38, 1971.
2. Maisto, C.R., Baumeister, A.A., Maisto, A.A. An analysis of variables related to self-injurious behavior among institutionalized retarded persons. *J Ment Defic Res* 22:27-36, 1978.
3. Schroeder, S.R., Schroeder, C.S., Smith, B., Dalldorf, J. Prevalence of self-injurious behaviors in a large state facility for the retarded: a three-year follow-up study. *J Autism Child Schizophr* 8:261-69, 1978.
4. Soule, D., O'Brien, D. Self-injurious behavior in a state center for the retarded: incidence. *Research and the Retarded*. 1:1-8, 1974.
5. Gorlin, R.J., Pindborg, J.J., Cohen, M.M. *Syndromes of the Head and Neck*, 2d ed. New York; McGraw Hill. 1976, pp 433-35.
6. Anderson, L., Dancis, J., Alpert, M. Behavioral contingencies and self-mutilation in Lesch-Nyhan disease. *J Consult Clin Psychol* 46:529-36, 1978.
7. Baroff, G.S., Tate, B.G. The use of aversive stimulation in the

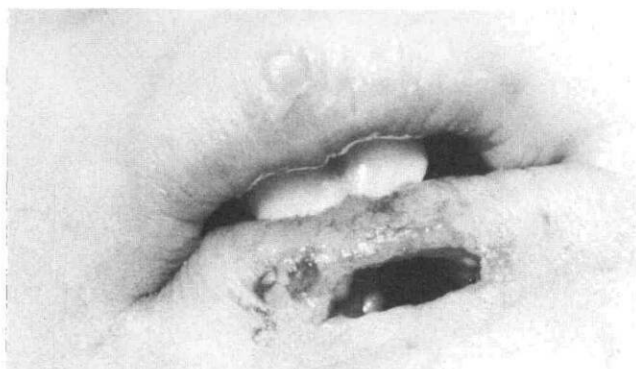


FIGURE 6. Perforation through the lower lip caused by biting.

- treatment of chronic self-injurious behavior. *J Am Acad Child Psychiatry* 7:454-70, 1968.
8. Tate, B.G. Case study: control of chronic self-injurious behavior by conditioning procedures. *Behav Ther* 3:72-83, 1972.
 9. Lovaas, O.J., Simmons, J.Q. Manipulation of self-destruction in three retarded children. *J Appl Behav Anal* 2:143-57, 1969.
 10. Romanczyk, R.G., Goren, E.R. Severe self-injurious behavior: the problem of clinical control. *J Consult Clin Psychol* 43:730-39, 1975.
 11. Hoefnagel, D., Andrew, E.D., Mireault, N.G., Berndt, W.O. Hereditary choreoathetosis, self-mutilation and hyperuricemia in young males. *N Engl J Med* 273:130-35, 1965.
 12. Cudzinowski, L., Perreault, J.G. The Lesch-Nyhan syndrome: report of a case. *J Dent Child* 46:143-44, 1979.
 13. La Blanc, J., Epker, B.N. Lesch-Nyhan syndrome: surgical treatment in a case with lip chewing. *J Maxillofac Surg* 9:64-67, 1981.
 14. Budnick, J. The Lesch-Nyhan syndrome. *J Dent Child* 36:227-80, 1969.
 15. Dicks, J.L. Lesch-Nyhan syndrome: a treatment planning dilemma. *Pediatr Dent* 4:127-30, 1982.
-

Quotable quote: caries vaccine

The development of a successful caries vaccine would be the most significant breakthrough in caries research, especially given the relatively high cost and incomplete protection of other preventive techniques. Dental researchers in the National Caries Program, dental schools, and pharmaceutical firms are working on the development of a caries vaccine.

The prime causative agents in tooth decay are apparently *Streptococcus mutans* bacteria. There are a number of reasons why these particular bacteria cause cavities. According to Michael Cole of the National Caries Program, "Number one, they produce lots of acid when you eat carbohydrates or sugars. Many bacteria do that, but *S. mutans* produce the most. They're also fairly unique in being able to thrive in these acid environments."

At the National Caries Program laboratories, immunization of rats and monkeys has been achieved. According to Cole, rats immunized with an experimental vaccine have shown a 60-70% reduction in new decay.

In early 1984, scientists at Burroughs Wellcome Co. plan to begin testing an injectable caries vaccine in children in England. However, company officials expect that it will be some time before the vaccine would be available in the United States, even if these tests show that it is safe and effective.

From: Preventing tooth decay: results of a four-year national study. The Robert Wood Johnson Foundation, Special Report No. 2, 1983, p 15.

Quotable quote: if nothing ever changed

If we lived on a planet where nothing ever changed, there would be little to do. There would be nothing to figure out. There would be no impetus for science. And if we lived in an unpredictable world, where things changed in random or very complex ways, we would not be able to figure things out. Again, there would be no such thing as science. But we live in an in-between universe where things change, but according to patterns, rules, or, as we call them, laws of nature. If I throw a stick up in the air, it always falls down. If the sun sets in the west, it always rises again the next morning in the east. And so it becomes possible to figure things out. We can do science, and with it we can improve our lives.

From: Sagan, C.: *Cosmos*. New York; Random House, 1980, p 46.