

---

# Ewing's sarcoma of the mandible in a young patient: case report

Marcio A. da Fonseca, DDS, MS Richard B. Abrams, DDS, MRDC(C)

## Abstract

*Ewing's sarcoma, a malignant tumor, rarely occurs in children younger than 5 years of age. Although it may appear in any bone, it is more common in the axial skeleton, rarely involving the jaws (1 to 2% incidence, mostly in the mandible). The most common symptoms are pain and swelling in the affected area. History of trauma often is reported. The case of a 4-year, 10-month-old Caucasian male with a rapidly expanding mass on the right side of his face following an injury to his mandible is reported. (Pediatr Dent 14:402-4, 1992)*

## Introduction

Ewing's sarcoma (ES) was first described by James Ewing in 1921.<sup>1</sup> Its origin is still not clear. Authors debate whether it is of endothelial origin, from immature reticulum cells or primitive mesenchymal cells of bone marrow,<sup>1</sup> or of neural origin.<sup>2</sup>

ES accounts for 1% of all malignancies of children, rarely occurring in children younger than 5 years of age.<sup>2</sup> Some authors<sup>2-4</sup> have described no gender predilection, but Goaz and White<sup>5</sup> reported it to be twice as frequent in males. The incidence is very low in African Americans and Chinese Americans. In Caucasian American children younger than the age of 15 years, the incidence is 1.7 cases per million individuals per year.<sup>2</sup>

Pain and swelling are the usual symptoms, especially in patients with localized disease.<sup>2</sup> However, Wood et al.<sup>1</sup> described four patients with ES in the jaws who did not complain of pain. The pelvic bones, the humerus, and the femur are affected more often, with an associated soft tissue mass.<sup>2</sup> Two-thirds of all lesions occur in the lower skeleton.<sup>1</sup>

The differential diagnosis of ES is one of exclusion, because it has no specific markers.<sup>2</sup> All small, round, blue cell tumors of childhood, such as primary bone sarcomas, rhabdomyosarcomas, lymphomas, neuroblastomas, and primitive neuroectodermal tumors, should be considered. Osteomyelitis frequently is confused with ES, because the tumor may be inflamed. A diffuse mass of tumor cells involving the adjacent soft tissue is seen microscopically, and often there is a biphasic population of clear large and dark small cells. Under electron microscopy, cytoplasmic pools of glycogen are seen.<sup>2-4</sup>

Patients with metastases at diagnosis have poorer prognoses. Treatment is directed toward local control, preserving function, and preventing and treating metastases, which rarely affect the lymph nodes and central nervous system.<sup>2</sup> Treatment usually combines radiotherapy, surgery, and chemotherapy.<sup>6</sup> The most effective drugs to date have been cyclophosphamide and doxorubicin; however, the optimal chemotherapy is unknown.<sup>3, 4, 7</sup>

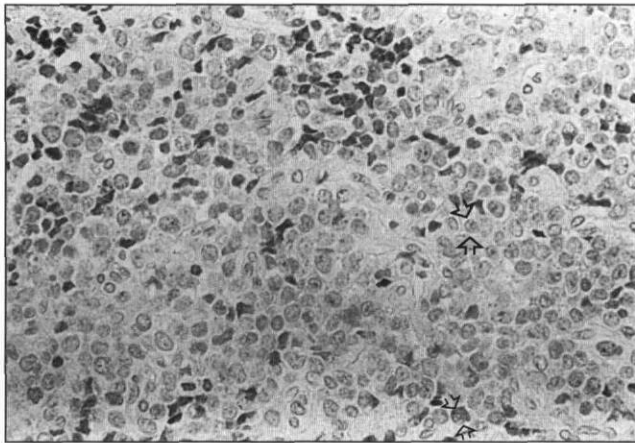
ES of the jaws is relatively rare, with disagreement on its exact occurrence.<sup>1, 3</sup> According to Langman et al.,<sup>7</sup>

the incidence is between 1 and 2%, predominantly in the mandible. Wood et al.,<sup>1</sup> in their review of 105 cases, reported a ratio of 2.1 cases in the mandible for every one in the maxilla, with the posterior parts of the jaws more involved. They also described an average age of 16.4 years (SD = 9.9) for females and 15.6 years (SD = 10.6) for males, which agrees with other studies.<sup>3, 4</sup>

## Case Report

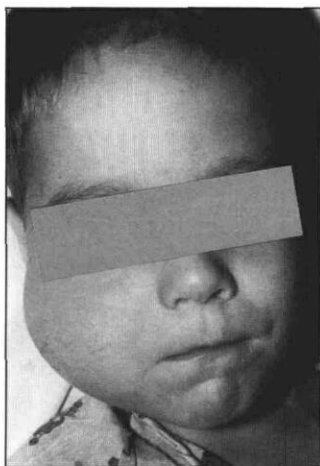
A 4-year, 10-month-old Caucasian male fell on his right mandible and developed a nodule that steadily grew in size. His pediatrician referred him to his family dentist, who believed the swelling was related to the trauma; no treatment was performed and no radiographs were exposed. As the mass still was expanding rapidly, the dentist referred the patient to an otolaryngologist who performed laboratory tests and a site biopsy. The tests, including a complete blood count and urinalysis, revealed no abnormalities. The otolaryngologist subsequently referred the patient to the oncology service at The Children's Hospital, in Denver, Colorado, where the staff pathologist read the biopsy as inconclusive for malignant disease and ordered a new one.

The second biopsy, performed four weeks after the trauma, was positive for Ewing's sarcoma. The hematoxylin and eosin and the periodic acid-Schiff stains showed a tumor infiltrate within the hematopoietic marrow, involving the adjacent soft tissue. Sheets and clusters of uniform, small round tumor cells with clear to faintly eosinophilic cytoplasm and relatively uniform finely stippled nuclear chromatin were seen. Occasional small nucleoli and tumor cell mitoses were found (Fig 1, page 403). The surrounding soft tissue was determined to be primarily loose fibroconnective tissue, with occasional areas of reactive new bone formation. Electron microscopic examination revealed that the neoplastic cells displayed few features of differentiation. In some cells, focal aggregates of cytoplasmic glycogen, which suggest Ewing's sarcoma, were found. Bone scan, computerized tomography of the chest, and bone marrow aspirates and biopsies were negative for metastatic disease.



**Fig 1.** Sheets and clusters of uniform small round cells with occasional small nucleoli (large arrows) and cell mitoses (small arrows) in a diffuse mass (H & E stain, 400 x mag).

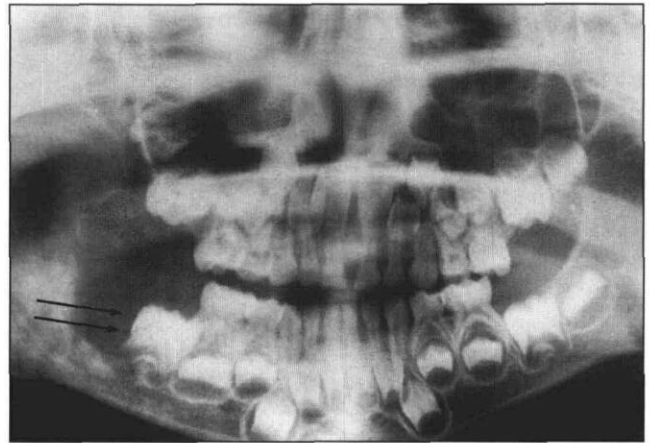
One week after diagnosis, the patient was referred to our dental service for consultation. Extraoral examination revealed facial asymmetry with a large, nontender mass on the right side of his face (Fig 2). A small degree of trismus was present because of the tumor. There were no complaints of pain, numbness, or loose teeth. Intraorally, the soft tissue was within normal limits, except for the biopsy site. All primary teeth were present. Bite-wing and occlusal radiographs revealed interproximal caries, and the panoramic radiograph (Fig 3) showed an extensive radiolucent lesion, with no clear borders, involving most of the right side of the mandible and the condyle. The tooth bud of the mandibular right second permanent molar was floating within the lesion, and was removed during the second biopsy. The first permanent molar was displaced mesially by the tumor. Recommendations were made regarding oral hygiene and treating the interproximal carious lesions during chemotherapy. The patient was followed closely to monitor any morbidity from the chemotherapy.



**Fig 2.** Patient at the initial dental consultation. Extraoral swelling is evident.

The patient received a central venous catheter, and chemotherapy was begun according to the Children's Cancer Study Group Protocol 7881 (vincristine, doxorubicin, cyclophosphamide and dactinomycin, every three weeks). At the end of three cycles of chemotherapy, surgery was performed to remove the tumor completely. Because of his young age, surgery was preferred over radiotherapy to avoid postradiation growth abnormalities. Ten days after treatment was initiated, he was admitted with fever and neutropenia; the mass had decreased noticeably in size.

At the end of three cycles of chemotherapy, the mass had decreased by 85%. The patient then underwent surgical removal of the posterior half of the right side of the mandible, including several primary and permanent teeth. He is receiving chemotherapy (vincristine, cyclophosphamide, and doxorubicin) and radiation (4500 cGy over five weeks). Reconstructive surgery is planned for the future.



**Fig 3.** Panoramic radiograph after the diagnostic biopsy. Note the displacement of the lower right first permanent molar. The second permanent molar bud was removed during the biopsy.

**Discussion**

Dentists play an important role in treating orofacial trauma. Radiographs should be exposed routinely in such cases, especially when signs and/or symptoms are present. In the case reported, the diagnosis of ES of the jaw might have been made earlier if radiographs had been exposed during the patient's initial consultation with the general practitioner. Although the patient did not complain of pain, extraoral swelling was evident and increasing, leading to trismus (Fig 2). A high index of suspicion on the part of the dentist could have led to earlier referral. In cases of ES, history of trauma usually is reported, but its role in the course of the disease is not clear.<sup>2</sup>

A site biopsy is the most important aspect in evaluating ES.<sup>2</sup> The lack of adequate tissue delayed the diagnosis and could easily have led to misdiagnosis. Repeated biopsies increase the chance for pathologic fractures; therefore, it is imperative that the initial tissue sample be representative of the tumor.

The initial panoramic radiograph (Fig 3) showed a poorly defined osteolytic lesion in the right side of the mandible. According to Langman et al.,<sup>7</sup> the ramus often is affected, "possibly because it has the largest amount of marrow in the mandible." This may indicate that the tumor originated from marrow constituent.<sup>1</sup> Some authors<sup>5,6</sup> have reported that radiographs showed an "onion peel" or "sun-ray" pattern, but neither was present in this case. Wood et al.<sup>1</sup> stated that periosteal laminations were difficult to see because of the complex anatomy of the jaws, and therefore, could not be considered a feature of ES. They also pointed out two other radiographic signs seen in this case: a soft tissue mass adjacent to the tumor (Fig 2) and destruction of follicles of unerupted teeth (Fig 3), which is a sign of malignancy. However, Greer et al.<sup>8</sup> stated that soft tissue involvement is usually minimal when the tumor is in the head and neck region.

At diagnosis, the patient did not have fatigue, anorexia, fever, or malaise which often are associated with metastatic disease. Bone scan, computerized tomography of the chest, and bone marrow aspirates and biopsies were negative for metastases. These procedures are part of an appropriate clinical evaluation of patients with ES to determine the extent of the disease.<sup>2,8</sup> Poorer prognosis is related to the presence of metastases, pelvic and sacral disease, and the "filigree" pattern and widespread tumor cell necrosis seen under light microscopy.<sup>2</sup> The maxilla usually has worse prognosis because of sinus and orbital involvement.<sup>3,6</sup> Our patient had none of these problems.

In the case presented, the patient received a central venous catheter and started chemotherapy immediately after the diagnosis was made. No radiation was planned due to the possible effects on jaw growth. Chemotherapy is an important adjuvant in managing metastases, which are the main concern in this malignancy.<sup>1</sup> Its use has increased survival from 10 to 75%.<sup>7</sup>

After chemotherapy, the tumor shrunk by 85% and proved to be resectable. The general philosophy for surgery is to remove the whole entity, obtaining clear margins of healthy tissue and preserving function as much as possible.<sup>2,7</sup> The patient had the posterior half of the right side of the mandible removed and the entire tumor was resected. Although local relapses have occurred in cases of ample resection of the mandible, Mamede et al.<sup>6</sup> obtained satisfactory results (survival

rates of up to seven years) with patients who received radiochemotherapy after surgery. Furthermore, it has been shown that, despite the local changes caused by radiation, the osteogenic potential of the irradiated periosteum is maintained. Ruggiero and Donoff<sup>9</sup> reported two cases in which bone formation occurred in irradiated fields, following extensive resection of the mandible.

Odontogenic infection can lead to significant morbidity and mortality in oncology patients.<sup>10</sup> Therefore, the dental professional has an important role in the multidisciplinary care of these patients. During the course of treatment, the patient was followed closely for any oral infection that could compromise the outcome of the therapy. Chemotherapeutic agents cause bone marrow suppression, decreasing the body's defenses against opportunistic microorganisms, most commonly fungi and viruses.<sup>10</sup> Oral problems associated with chemotherapy, such as mucositis, localized ulcerations, and opportunistic infections, were not seen in this case. Reconstructive surgery is planned for our patient in the future.

Dr. da Fonseca is fellow, Division of Pediatric Dentistry and Dr. Abrams is director of Dental Education, The Children's Hospital, Denver, CO.

1. Wood RE, Nortje CJ, Hesselring P, Grottepass F: Ewing's tumor of the jaw. *Oral Surg* 69:120-27, 1990.
2. Miser JS, Triche TJ, Pritchard DJ, Kinsella T: Ewing's sarcoma and the nonrhabdomyosarcoma soft tissue sarcomas of childhood. In *Principles and Practice of Pediatric Oncology*. PA Pizzo, DG Poplack eds. Philadelphia: JB Lippincott, 1989, pp 659-88.
3. Arafat A, Ellis GL, Adrian JC: Ewing's sarcoma of the jaws. *Oral Surg* 55: 589-96, 1983.
4. Damm DD, White DK, Drummond JF, Ferretti GA: Ewing's tumor of the jaws. *Pediatr Dent* 7: 57-60, 1985.
5. Goaz PW, White SC: *Oral Radiology — Principles and Interpretation*. St. Louis: Mosby, 1982, pp 510-11.
6. Mamede RM, Mello FV, Barbieri J: Prognosis of Ewing's sarcoma of the head and neck. *Otolaryngol Head Neck Surg* 102:650-53, 1990.
7. Langman AW, Kaplan MJ, Matthay K: Ewing's sarcoma of the mandible. *Otolaryngol Head Neck Surg* 100:74-77, 1989.
8. Greer RO Jr, Mierau GW, Favara BE: *Tumors of the head and neck in children: clinicopathologic perspectives*. New York: Praeger, 1983, pp 157-65.
9. Ruggiero SL, Donoff RB: Bone regeneration after mandibular resection: report of two cases. *Oral Maxillofac Surg* 49: 647-52, 1991.
10. Redding SW, Montgomery MT: Neoplastic diseases: dental correlations. In *Internal Medicine for Dentistry*. LF Rose, D Kaye eds. St. Louis: Mosby, 1990, pp 390-99.