



# Use of self-etching adhesive system and compomer for splinting traumatized incisors

Theodore P. Croll, DDS Mark L. Helpin, DDS

*Dr. Croll is in private practice, Doylestown, Pa; Dr. Helpin is chief, Dental Division, Children's Hospital of Philadelphia. Both are faculty members, Department of Pediatric Dentistry, University of Pennsylvania School of Dental Medicine, Philadelphia, Pa. Correspond with Dr. Helpin at helpin@email.chop.edu*

## Abstract

Traumatized teeth that are displaced from their normal alveolar positions need to be repositioned and stabilized so that healing can occur. Orthodontic ligature wire bonded into place with resin-based composite works well for splinting teeth. Using a self-etching adhesive bonding system and compomer material facilitates both the resin bonding and its removal. This clinical report describes a simplified resin/wire splinting procedure. (*Pediatr Dent* 24:53-56, 2002)

**KEYWORDS: SPLINTING, TRAUMA, SELF-ETCHING ADHESIVE**

*Received October 19, 2001 Revision Accepted December 10, 2001*

Traumatically displaced anterior teeth requiring re-plantation and stabilization can pose difficult challenges for the dentist. The bonded resin-based composite/ligature wire splint is an easy and rapid method of stabilizing traumatically injured teeth.<sup>1</sup> Control of sulcular hemorrhage, the need to minimize manipulation of the newly damaged tissues and speed of treatment are all important considerations when applying a resin/wire splint. This brief report demonstrates application of a splint using polyacid-modified resin-based composite (compomer) material and a self-etching adhesive system. These new materials have further simplified splint application.

## Case history

A 13-year-old boy struck his four maxillary incisors on the floor, while in a department store, trying out a hand-held exercise device. The patient was alert, oriented and cooperative and gave no signs of neurological impairment. Medical history reported by the parent was noncontributory. Tetanus immunization was up to date. The mandible moved normally without pain, in the full range of motion. Palpation over the temporomandibular joints elicited no discomfort. The maxillary lateral incisors were both slightly mobile. Those teeth had no obvious coronal fractures and transillumination revealed no internal craze fractures. The diagnosis for the lateral incisor injuries was "Subluxation", according to the classification of Andreasen and Andreasen.<sup>2</sup>

Both central incisors suffered coronal fractures involving the mesial, labial and lingual surfaces and the incisal edges

(Fig 1). Although the fractures included enamel and extended well into the dentin, no pulp exposure was observed. Lingual shearing of enamel extended to the middle of the anatomical crown, on both central incisors.

Transillumination revealed some internal craze fracturing. These central incisors were moderately mobile and sulcular bleeding was evident. The central incisors also were sensitive to gentle digital manipulation. To avoid additional trauma to the displaced teeth, radiographs were not recorded until splint stabilization was completed. The diagnosis for both central incisors was "enamel-dentin fracture (uncomplicated crown fracture)"<sup>2</sup> in addition to "extrusive luxation (peripheral dislocation, partial avulsion)."<sup>2</sup> All other intraoral and dental findings were unremarkable.

## Treatment

Immediate goals of treatment were to stabilize the four maxillary incisors and restore the two fractured central incisors for an interim period of time. Such treatment would insulate exposed dentin tubules for protection of the pulp, and stabilize the teeth, so that normal tissue healing could occur. Appearance of the cosmetically prominent central incisors and allowing the patient's orthodontic retaining appliance to seat properly were also of concern. Future considerations included long-term pulpal and periodontal status of the four injured incisors.

With the above in mind, treatment proceeded as follows:

1. The labial surfaces of the four maxillary incisors were cleaned of debris with a small rotating brush and dentifrice, at 500 rpm, on the slow speed handpiece.

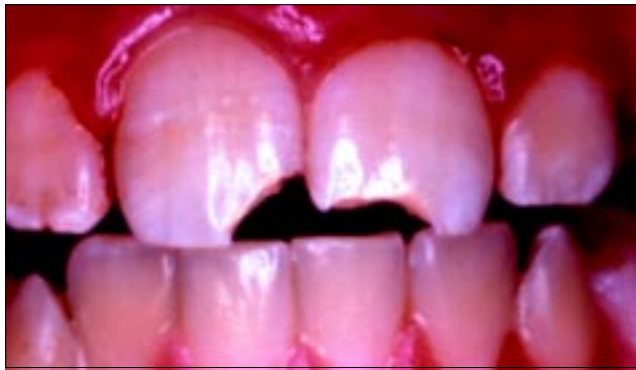

Fig 1. All four maxillary incisors loosened by traumatic blow. Central incisors suffered enamel and dentin fractures of mesio-incisal corners.

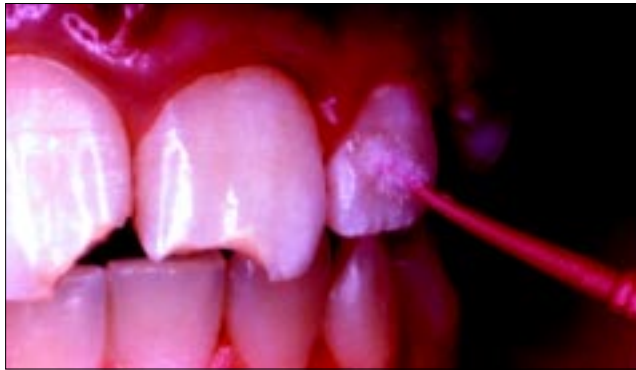

Fig 2. Self-etching adhesive bonding agent applied to the left incisors, and light-cured, after tooth surfaces cleaned

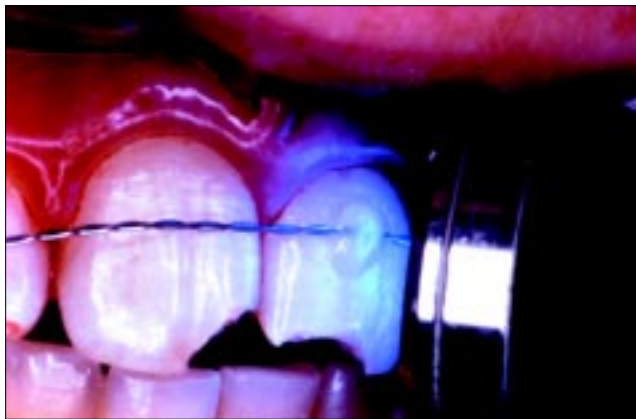

Fig 3. Small increment of compomer material attaches twisted double strand of 0.010" ligature wire to tooth surface at about one-third coronal height

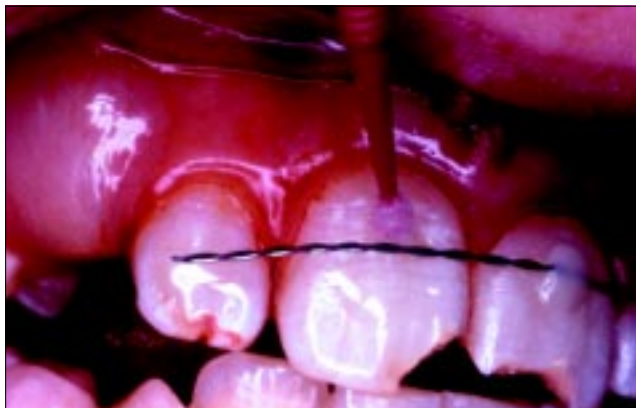

Fig 4. Ligature wire attached to right central and lateral incisors

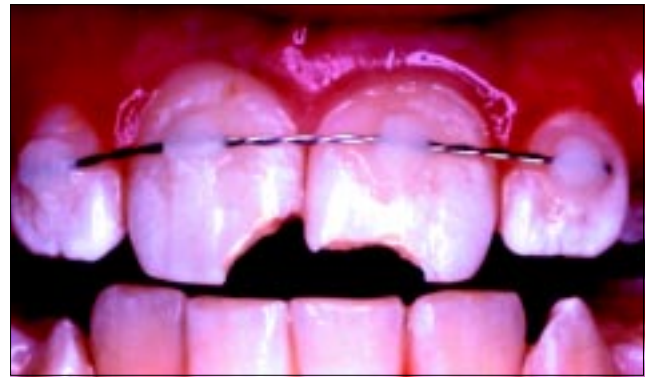

Fig 5. Completed bonded compomer/wire stabilization splint

2. A dead soft 0.010" (.25mm) stainless steel ligature wire, the type used to tie an arch wire into an orthodontic bracket, was twisted upon itself to make a double strand. A self-etching adhesive bonding material (Prompt® L-Pop® 3M ESPE, St. Paul, MN) was rubbed upon the labial surface of the two left incisors for approximately 20 seconds, air thinned and exposed to the curing light beam for 10 seconds (Fig 2).<sup>3</sup>
3. With the position of the labial wire of the boy's removable orthodontic retainer in mind, the splint wire was laid passively against the labial surface of the lateral incisor about one-third up the crown length from the gingival margin. A small increment of compomer material (Hytac, 3M ESPE, St. Paul, MN) was injected over the wire and pressed into place with a hand instrument. The compomer was then polymerized with 40 seconds exposure to the curing light beam. The wire was then bonded to the central incisor in the same manner (Fig 3).
4. With the two left incisors now attached to the wire splint, the wire was then bonded in the same way to the right central and lateral incisors (Figs 4 and 5). Occlusion was evaluated and the injured incisors were found not to be in contact with opposing teeth.
5. Exposed dentin was then covered with a thin layer of light-hardened resin-modified glass-ionomer liner material (Vitrebond, 3M ESPE, St. Paul, MN). Peripheral enamel was reduced slightly with a water-cooled high-speed diamond bur. The patient did not require local anesthetic injections for treatment.
6. Adjacent enamel and liner were coated with the self-etching adhesive bonding agent. It was rubbed into the surface for 30 seconds, using a small applicator (Fig 6).
7. Charisma brand resin-based composite (Heraeus Kulzer, South Bend, Indiana) was used for interim "bandage" restoration of the fracture sites. The wooden wedge, used to stabilize the stainless steel matrix, was placed with minimal pressure, so as not to elicit pain from the patient, or to create lateral forces on the injured central incisors. The injured teeth and the interim restorations would be evaluated in the future, clinically and radiographically. After pulpal healing, long-term

bonded, resin-based composite restorations would be considered.

8. To assist with pulpal and periodontal healing, the patient was provided with a prescription for amoxicillin 250 mg with instructions to take one capsule 3 times a day for 7 days.<sup>4</sup> This dosage was based on the child's weight.
9. After completion of treatment, radiographs (periapical and occlusal views) revealed no root or alveolar fractures (Fig 7). Periodontal spaces appeared normal and no root displacement was evident.
10. The patient was re-evaluated in 8 days. There was no sensitivity to percussion or palpation of the teeth and soft tissue findings were unremarkable. The lateral incisors were not abnormally mobile and the central incisors were only slightly so. The patient reported that he had been wearing his orthodontic retaining appliance daily (Fig 8).
11. Three weeks later, the compomer/wire bonded connectors were cut from the teeth using a slow speed diamond bur and the surfaces polished with superfine aluminum oxide disks (Fig 9). (High speed burs can also be used, but care must be taken to avoid iatrogenic damage to the enamel surface.) The restored central incisors were stable, not sensitive to digital manipulation or light percussion and all other findings were unremarkable (Fig 10).

### Discussion

For cases in which traumatized teeth are dislodged from their alveolar positions, and those in which tooth mobility is a concern, local anesthetic injections and tooth repositioning might be required. If local anesthetic is used, we recommend an agent without a vasoconstrictor in consideration of keeping the injured tissues oxygenated. In such cases, the repositioned teeth can be held in position by the patient occluding on a wax or dental compound bite platform, while the dentist applies the bonded compomer/wire splint.<sup>1</sup>

A dead soft 0.010" ligature wire was used, which provides for sure stability even though it is slightly flexible. Use of such a wire gives the splinted teeth some physiological

mobility within the alveolar socket and is thought to aid in preventing ankylosis.<sup>5</sup> Perhaps this type of wire also makes splint retention time less critical. A splint wire is usually kept in place for 2 to 4 weeks, depending on severity of displacement and assessment of mobility over that period. Some practitioners use a flexible nylon fishing line, bonded with filled resin, for splinting teeth, rather than stainless steel wire.<sup>5</sup>

Combining the self-etching adhesive and compomer material for bonding are minor modifications of the established ligature wire/resin splint procedure, but represent important simplifications of the method. Traditionally,

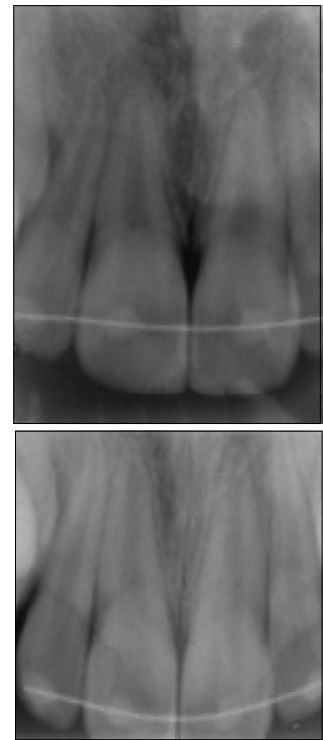


Fig 7. Periapical and occlusal radiographs recorded after splinting and restorations completed

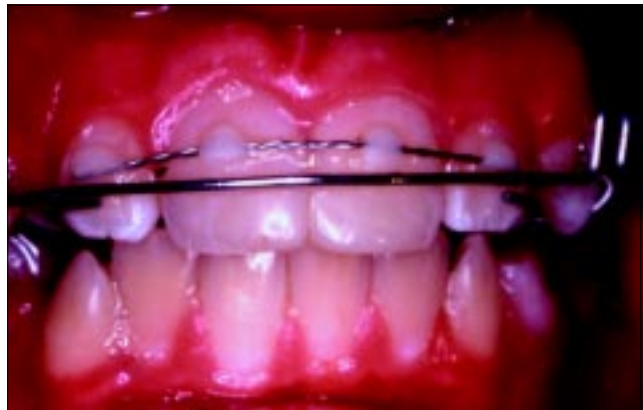

Fig 8. Splint observed 8 days after application. Wire and compomer placement designed to avoid interference with orthodontic retaining appliance.

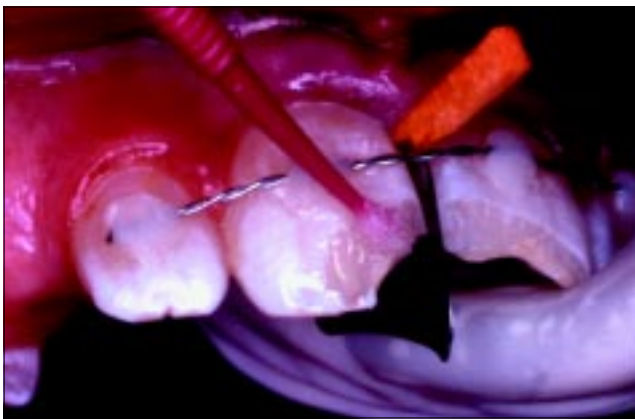

Fig 6. Self-etching adhesive, resin-based composite and matrix strip used to restore fractured incisors. Wooden wedge placed with minimal pressure.

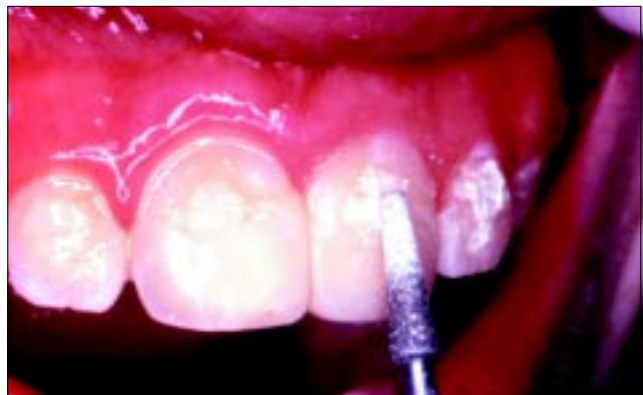

Fig 9. Diamond bur at slow speed used to remove bonded compomer material. Polishing disks then used to finish enamel surface.

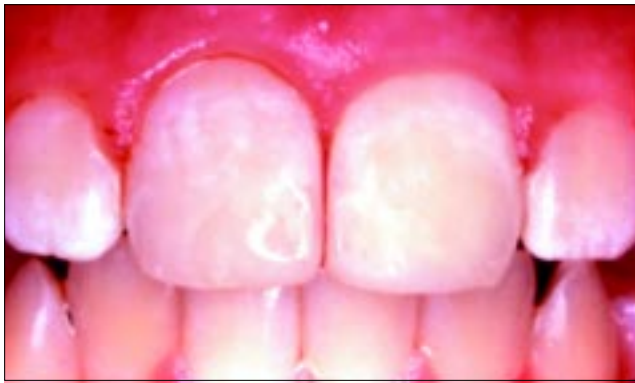

Fig 10. Incisors with interim restorations shown immediately after splint removal

after applying phosphoric acid to etch the enamel, the etched surface is rinsed and dried. Oftentimes, when splinting teeth after traumatic displacement, there exists hemorrhage in the region which, once controlled, can resume with water spray lavage of the etchant solution. In addition, water spray and the sound of high-speed evacuation can be upsetting for some younger patients. Use of self-etching adhesive bonding agent makes splint application easier and faster by eliminating the separate etching and rinsing steps.

Compomer materials are polyacid-modified, resin-based composites. Even though they contain glass filler particles and polyacid components used in glass-ionomer systems,

they still must be photopolymerized for the hardening reaction. Compomers are quite suitable for interim restorations, restoration of certain primary teeth and some orthodontic bonding procedures. Because physical properties of compomers are generally inferior to those of the standard resin-based composites, they are more easily cut away using carbide or diamond instruments after they have served their purpose. However, even in small portions, bonded compomers have sufficient durability, bond strength and cohesive strength to withstand normal forces of mastication that could tend to dislodge a wire splint.

## References

1. Croll TP. Bonded composite resin/ligature wire splint for stabilization of traumatically displaced teeth. *Quintessence Int* 22:17-21, 1991.
2. Andreasen JO, Andreasen FM. Classification, etiology and epidemiology. In: *Textbook and Color Atlas of Traumatic Injuries to the Teeth*. 3rd ed. Copenhagen: Munksgaard; 1994:151-155.
3. Croll TP. Self-etching adhesive system for resin bonding. *J Dent Child* 67:176-181, 2000.
4. Hammarstrom L, Blomlof L, Feiglin B, Andersson L, Lingskog S. Replantation of teeth and antibiotic treatment. *Endod Dent Traumatol* 2:51-57, 1986.
5. Kehoe JC. Splinting and replantation after traumatic avulsion. *JADA* 112:224-230, 1986.

## ABSTRACT OF THE SCIENTIFIC LITERATURE



### NATURAL HISTORY OF CARDIOVASCULAR MANIFESTATIONS IN MARFAN SYNDROME

This study investigated the diagnosis and progression of mitral valve and aortic abnormalities in patients with Marfan syndrome during childhood and adolescence. The study cohort consisted of 52 children with Marfan syndrome who were followed for an average of 7.9 years. Eighty-eight percent of the patients were diagnosed with mitral valve prolapse, 48% with mitral regurgitation, 83% with aortic dilatation and 25% with aortic regurgitation. Sixty-five percent of the subjects showed progression of either mitral valve dysfunction or aortic abnormalities during the follow-up period. Frequently, the progression occurred without symptoms and resulted in significant morbidity and/or mortality. All patients developed mitral valve prolapse by 18 years of age.

**Comments:** Pediatric and general dentists should recognize the importance of having their patients with Marfan syndrome evaluated echocardiographically on a regular basis. Since mitral valve dysfunction in these patients is often "silent" and frequently progresses, a child who initially does not require SBE prophylaxis may develop a cardiac abnormality that does require prophylaxis. RS

Address correspondence to Dr. Offringa, [m.offringa@amc.uva.nl](mailto:m.offringa@amc.uva.nl)

Van Karnebeek CDM, Naeff MSJ, Mulder BJM, Hennekam RCM, Offringa M. Natural history of cardiovascular manifestations in Marfan syndrome. *Archives of Diseases in Childhood* 84:129-137, 2001.

39 references