



Custom Sports Mouthguard Modified for Orthodontic Patients and Children in the Transitional Dentition

Theodore P. Croll, DDS Cosmo R. Castaldi, DDS, MSD

Dr. Croll is a pediatric dentist in private practice, Doylestown, Pa, and adjunctive clinical professor, Department of Pediatric Dentistry, University of Texas Health Science Center at San Antonio (Dental School), Tex; Dr. Castaldi is Professor Emeritus, University of Connecticut School of Dental Medicine, Farmington, Conn.

Correspond with Dr. Croll at willipus@tradenet.net

Abstract

Young athletes with ever-changing transitional dentitions and those wearing fixed orthodontic appliances can benefit from custom-formed protective mouthguards. Modifications of the traditional vacuum-forming method are useful to fabricate mouthguards for such patients and extend the useful life of these devices. The purpose of this case report is to document fabrication of custom-formed protective mouthguards for a 10-year-old boy wearing fixed orthodontic appliances and a 9-year-old girl with a fixed palatal expander in place. (*Pediatr Dent.* 2004;26:417-420)

KEYWORDS: MOUTHGUARD, CUSTOM-FORMED, ORTHODONTIC APPLIANCES, TRANSITIONAL DENTITION

Received October 29, 2003 Revision Accepted April 26, 2004

Traumatic impact to teeth and their supporting structures is common during athletic activities. Custom-fabricated protective mouthguards for people participating in sports and certain recreational activities can minimize or eliminate mouth injuries.¹⁻⁸ Such mouthguards are vacuum-formed on a plaster or stone model of the maxillary dental arch and fit better than the “store-bought” type of mouth protectors. Athletes wearing custom-formed mouthguards report that they: (1) are more comfortable; (2) don’t interfere with breathing or speaking; (3) permit more complete jaw closure; (4) don’t cause soft tissue irritation; and (5) cause less excess salivation.²

Young athletes in the transitional dentition years and patients wearing fixed orthodontic appliances are as much at risk of dental trauma as any athlete. Bonded or cemented orthodontic appliances pose problems when vacuum-formed mouthguards are fabricated. Because teeth shift during the course of orthodontic therapy and permanent teeth continually erupt into position, a custom-formed mouthguard may not fit soon after the initial impression is recorded. In mixed dentition patients, tooth eruption and growth may affect mouthguard fit and limit the useful lifespan of a custom-formed appliance. By incorporating space within a custom-formed mouthguard to accommodate prospective tooth movement and dental development,

a vacuum-formed mouthguard can be produced to withstand several sports seasons in a year, or longer.

This case report describes a method of fabricating custom-fitted protective mouthguards for patients wearing fixed orthodontic appliances and those in the transitional dentition. The methods include modifications of a previously published technique.⁹

Methods

A 10-year-old boy had commenced his orthodontic therapy with bonded and cemented appliances. A custom-fitted, vacuum-formed protective sports mouthguard was fabricated in the following manner:

First, a thin “rope” of utility wax was compressed around the bonded brackets of the maxillary incisors (Figure 1). The wax was just thick enough to cover the brackets. Presence of the wax minimized alginate material tearing when the impression tray was removed.

Next, a dental stone model was poured and trimmed in a horseshoe configuration, with a thin base (Figure 2). Mortite Weatherstrip and Caulking Cord (Mortite Inc., Kankakee, Ill), which is available in hardware stores, was used to cover areas of protruding orthodontic brackets and wires and to fill in regions of prospective tooth development and orthodontic movement (Figure 3). Dental

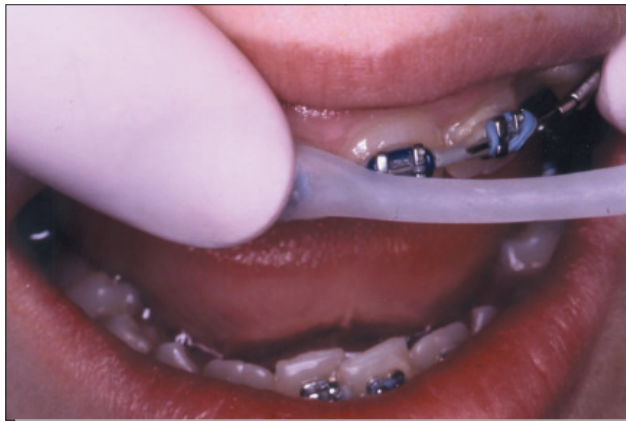


Figure 1. Utility wax strip compressed over bonded brackets prior to alginate impression in a 10-year-old athlete.

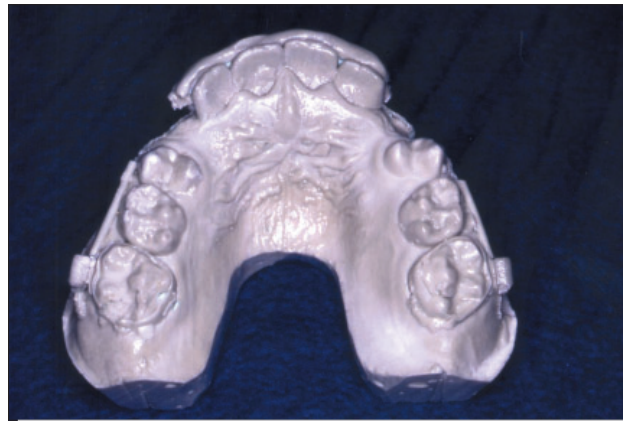

Figure 2. Poured and trimmed dental stone model.

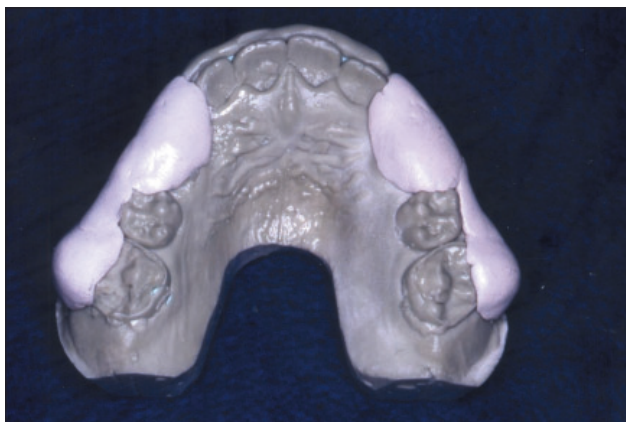

Figure 3. Mortite brand window sealing compound placed over orthodontic fixtures and in regions of prospective tooth movement.

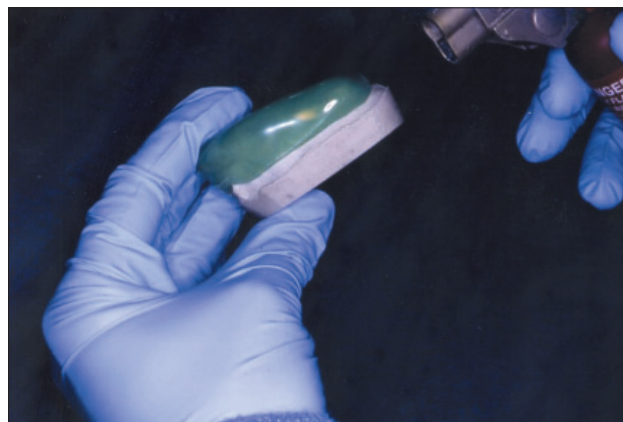

Figure 4. Vacuum-formed, trimmed, and finished mouthguard with margins heat smoothed in the laboratory.

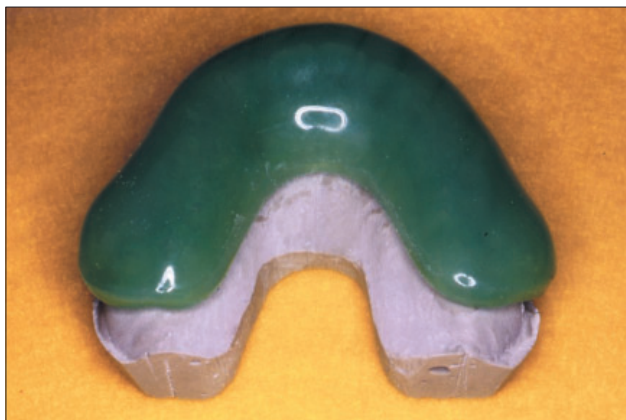

Figure 5. Finished mouthguard—occlusal view.

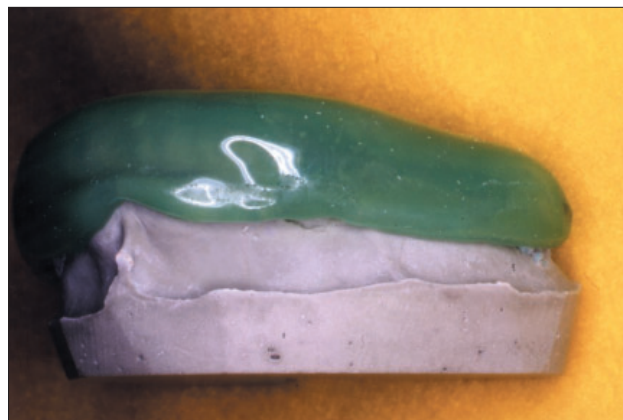


Figure 6. Finished mouthguard—anterior/lateral view.

plaster, stone, or other putty-like materials can also be used for blocking out space, but any such material must be resistant to the heat during vacuum forming.

After the cast and Mortite “filler” material was sprayed with a silicon separating solution, the ethyl-vinyl-acetate (EVA) sheet was heated and vacuum formed in the usual manner.^{2,9} Proform Extra Pro Laminates EVA triple-layered mouthguard material (Dental Resources, Delano,

Minn) is 5-mm thick before vacuum forming. Once vacuum formed, the mouthguard’s thickness thins to about 3 to 4 mm. The extra thickness offers more protection against impact, without opening the bite significantly. Proform brand mouthguard sheets have an embedded bite tab to coincide with the mandibular incisors’ position during mouth closure. If desired, the EVA sheet can be rotated 180 degrees during vacuum forming, allowing the region

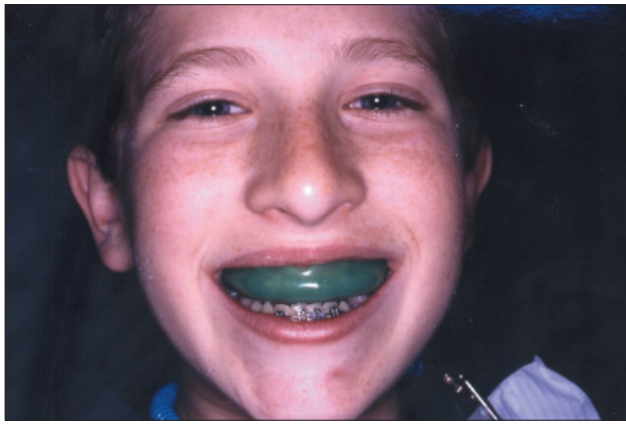

Figure 7. Completed mouthguard in position.

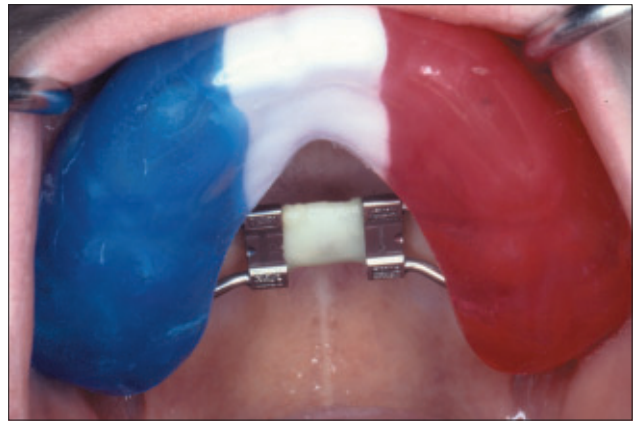


Figure 8A. Nine-year-old girl wearing palatal expander and custom mouthguard.

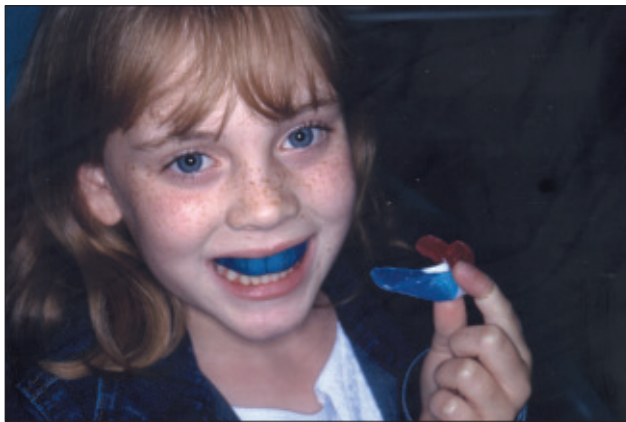

Figure 8B. Patient shows mouthguard design. Note cutout regions for large buccal tubes on permanent first molars.



Figure 8C. Dental stone cast with block-out material in place, used for patient in Figures 8A and 8B.

to be eliminated during the finishing procedures. The 5-mm EVA mouthguard sheets come in various colors, including a patriotic red/white/blue version. Dental Resources and other manufacturers offer mouthguard materials less than 5-mm thick. When these are used, care must be taken during the heat/vacuum-forming process so as not to thin the material excessively.

The mouthguard was cut to form using scissors. A large stone on the dental lathe was used for shaping and smoothing margins. Final smoothing of the entire periphery was completed with a hand-held torch. The flame was applied intermittently to prevent burning the edges (Figure 4).^{2,9} To avoid distortion, the mouthguard should be flame treated only while seated on the dental cast.

The completed mouthguard is shown on the dental cast (Figures 5 and 6) and in the patient's mouth (Figure 7).

A 9-year-old girl who had completed palatal expansion and was expected to wear the fixed expander for another 6 months is shown with her appliance and mouthguard in place (Figures 8A and 8B). Mortite was applied to the cast to accommodate space for erupting permanent lateral incisors, and the mouthguards were trimmed carefully in the regions of the palatal expanding device and the permanent

first molars' large buccal tubes (Figure 8C). Because the dental cast was not damaged during mouthguard fabrication, a spare was made for the child for no additional fee.

Discussion

In the prior report of this method, utility wax was not used across the bonded brackets.⁹ Instead, Mortite was placed on the cast in those regions. The wax makes for a neater impression, and the alginate material does not tear when the impression tray is removed. Also, experience has shown that a cast with a thinner base makes for less stretching and thinning out of the heated material during vacuum forming.

Triple-layered ethyl vinyl acetate material (5 mm) makes for a sturdier and more protective mouthguard. One must consider, however, that if the bite is opened too much, there could be discomfort in the temporomandibular joints. The mouthguard's posterior biting surface can be trimmed flat with an arbor band on the dental lathe to at least partially close the bite, according to the patient's comfort. Some dentists soften the posterior bite region with a flame and have the patient gently bite into the surface. The tooth markings from the mandibular posterior teeth slightly close

the bite and create a comfortable mandibular rest position. Most athletes, however, are quite comfortable with no preparation of the posterior bite surfaces.

Some mouthguard material manufacturers offer anterior straps that can be heat attached during the fabrication process. Certain sports leagues, especially hockey and football, mandate that the mouthguard be attached to the helmet's face protection segment. Directions for attachment of such straps are usually included with the material.

Acknowledgments

The authors have no financial interest in any product or company mentioned in this report.

Consent to use facial photographs was granted to Drs. Croll and Castaldi, and the American Academy of Pediatric Dentistry.

References

1. Stenger JM, Lawson EA, Wright JM, Ricketts J. Mouthguards: Protection against shock to head, neck and teeth. *J Am Dent Assoc.* 1964;69:273-281.
2. Castaldi CR. The protective mouthguard. In: Castaldi CR, Brass GA, eds. *Dentistry for the Adolescent*. Philadelphia: WB Saunders Co; 1980:233-241.
3. Castaldi CR. Sports-related oral and facial injuries in the young athlete: A new challenge for the pediatric dentist. *Pediatr Dent.* 1986;8:311-316.
4. Castaldi CR. Prevention of craniofacial injuries in ice hockey. *Dent Clin North Am.* 1991;35:647-656.
5. Lee-Knight CT, Bell RD, Faulkner RA, Schnider VE. Protective mouthguards and sports injuries. *J Can Dent Assoc.* 1991;57:39-41.
6. Ranalli DN. Preventing mouth injuries during sports. *Pa Dent J.* 1995;62:17-20.
7. Ranalli DN. Prevention of sports-related traumatic dental injuries. *Dent Clin North Am.* 2000;44:35-51.
8. Ranalli DN, Demas PN. Orofacial injuries from sport/preventive measures for sports medicine. *Sports Med.* 2002;32:409-418.
9. Croll TP, Castaldi CR. The custom-fitted athletic mouthguard for the orthodontic patient and for the child with a mixed dentition. *Quintessence Int.* 1989;20:571-575.

ABSTRACT OF THE SCIENTIFIC LITERATURE



TREATMENT OF BUCCAL CROSSBITE WITH DISTRACTION OSTEOGENESIS

Transverse mandibular deficiency has been a difficult orthodontic problem to treat. Orthognathic surgery, dental arch compensations, and extractions have been performed to correct this deficiency. An alternative procedure, distraction osteogenesis, has recently been presented as an effective treatment option. This case report described the treatment of a unilateral buccal crossbite in a 12-year-old girl with distraction osteogenesis using a custom-made hybrid distractor, splint, and elastics. A significant transverse increase of the mandible was noted following mandibular symphyseal distraction with the hybrid distractor.

Comments: A true unilateral buccal crossbite is relatively rare. Deficiency in mandibular width could be the underlying etiology of this transverse problem. The authors presented a unique and minimally invasive procedure with favorable treatment outcomes in this case report. Nevertheless, long-term stability and effectiveness of distraction osteogenesis in correcting transverse mandibular deficiency should be evaluated. **BL**

Address correspondence to Dr. John W. King, 5921 Harbour Lane, Suite 300, Midlothian, VA 23112.

King JW, Wallace JC. Unilateral Brodie bite treated with distraction osteogenesis. *Am J Orthod Dentofacial Orthop.* 2004;125:500-509.

22 references