

## Evaluation of a one-appointment formocresol pulpectomy technique for primary molars

James A. Coll, DMD, MS   Stuart Josell, DMD, MDent Sc  
Jerome S. Casper, DMD

### Abstract

*The purpose of this study was to evaluate the relative amount of root resorption in nonvital primary teeth after treatment with a 1-appointment formocresol pulpectomy.*

*Thirty-seven children ranging in age from 2 years, 10 months to 8 years, 10 months received 41 pulpectomies in nonvital primary molars. At an initial follow-up examination, 6-36 months posttreatment (mean = 21 months), 80.5% (33/41) of the pulpectomies were rated a success based on clinical and radiographic criteria. The age of the patient, the time interval the treated tooth was in place, and the type of tooth, had no significant effect on the success of the pulpectomy. Teeth with successful pulpectomies had root resorption similar to their antimeres. Pulpectomies tended to have root resorption similar to contralateral pulpotomies.*

*A second follow-up evaluation 5 years to 6 years, 10 months postoperatively (mean 70 months), involved 29 of the 41 pulpectomies; 86.1% (25/29) were rated a success. The pulpectomized molars were not overretained and succedaneous premolars had a low incidence of hypoplasia (2/17). In almost one-half of the cases, the root canal filler (zinc-oxide eugenol) was retained in the gingival sulcus after the pulpectomized tooth exfoliated.*

Various authors have expressed the view that endodontic treatment of nonvital primary teeth is contraindicated. Cohen<sup>1</sup> stated that primary teeth were not suitable for proper biomechanical endodontic procedures. Massler<sup>2</sup> felt that only the most dedicated of pediatric dentists should attempt endodontic procedures on primary teeth. Brauer<sup>3</sup> claimed that endodontic procedures were impractical in children.

Several reports have claimed clinical success treating primary teeth with infected or necrotic pulps utilizing techniques essentially limited to the pulp

chamber.<sup>4-7</sup> These reports have discussed 1- or 2-visit procedures wherein the infected primary tooth had a medicament placed in the pulp chamber, but with no attempt to treat the pulp tissue within the root canals. Claims of success have been based on the patient's being free of pain and having no clinical signs of apical abscess formation. Little information was given about radiographic changes nor was mention made as to whether the treated teeth were overretained or exfoliated early as compared to contralateral teeth.

A variety of pulpectomy techniques for primary teeth also have been reported involving mechanical debridement of the pulp chamber and root canals, followed by irrigation, drying of canals, and placement of a resorbable filling material. Rabinowitch published an extensively documented study of 1363 root canals on nonvital primary molars.<sup>8</sup> He reported that an average of 5.5 visits were required for nonperiapically involved teeth and 7.7 visits were required for teeth with periapical involvement.

Starkey<sup>9</sup> utilized 3 appointments to instrument, medicate, and, if asymptomatic, fill the canals with "Oxpara" paste as far apically as possible. He has advocated passing root canal files beyond the apex of molars<sup>10</sup> and other authors have advocated similar pulpectomy techniques.<sup>11-13</sup> Starkey also noted that a primary tooth with a successful pulpectomy usually will be overretained.<sup>14</sup>

A 1-appointment complete pulpectomy technique on 35 primary molars has been reported wherein the canals were filled with zinc oxide and eugenol (ZOE).<sup>15</sup> The investigation judged 29 of the 35 teeth successful from clinical and radiographic interpretations after an average time of almost 16 months. Unfortunately, no specific criteria for success were stated.

Rifkin reported treating 45 abscessed primary molars and incisors in 2 visits with an iodoform camphorated paste.<sup>16</sup> Preoperatively, some teeth had pathologic or physiologic root resorption, while others had perforations of the pulpal floor. In a 2-½ to 4-½ year follow-up report on 38 of these cases he found no enamel or morphologic defects in succedaneous teeth, but 3 cases had 1 mm enamel white spots.<sup>17</sup> In 20 of the 38 cases the teeth exfoliated naturally, but no comparison of exfoliation time was made to that of the contralateral tooth.

The purpose of the present study was to examine the success of a 1-appointment pulpectomy technique on primary molars and follow the treated molars to determine if they exfoliated normally or were overretained; to evaluate their root resorption compared to their contralateral molars; to determine if the ZOE root canal filler was resorbed; and to tabulate the prevalence of enamel defects in succedaneous premolars.

## Methods and Materials

Forty-one nonvital primary molar teeth in 37 children (2 years, 10 months to 8 years, 10 months) were treated in 1976 and 1977 using a 1-appointment formocresol pulpectomy technique similar to that described by O'Riordan and Coll.<sup>18</sup> All teeth were slightly mobile or had a sinus tract. On entrance into the pulp chamber, these teeth demonstrated a purulent exudate throughout the pulp chamber or evidence of severe pulpal degeneration such as purulent exudate extending into one or more canals. Radiographically, approximately 80% of the teeth had evidence of furcation or periapical bone destruction.

Pulpectomies were determined to be contraindicated when:

1. Primary molars were mobile vertically or displayed extensive furcation radiolucencies involving more than one-half of the root
2. Internal resorption or other radiographic signs of pathologic root resorption were present involving any more than the apical tip of the root
3. A firm apical stop resistance point could not be obtained with a size 40 file or smaller
4. The patient had a congenital heart defect or other severe systemic disease.

The pulpectomy procedure involved filing the canals short of the apex to a resistance point with progressive file sizes up to a size 40 or smaller. Prior experience had shown that excessive root canal filler will be extruded beyond the apex when no resistance point is established. After using each size file, sodium hypochlorite was used for canal irrigation. After the final irrigation, paper points were used to dry the

canals. Paper points slightly moistened with Buckley's formocresol then were placed in each canal for 5 min. A thick mix of ZOE was condensed into the canals with root canal pluggers as described by Gorig and Camp.<sup>19</sup> Total treatment time was approximately 30-45 min. All treatments were performed by the same investigator (JAC).

Various clinical and radiographic criteria were used to evaluate the success of the pulpectomies. Clinically, a successful pulpectomy showed no mobility and resolution of a draining sinus tract within a month. In addition, the history was negative for pain, swelling, or redness of the mucosa. Pulpectomies were considered a radiographic success if they exhibited no pathologic bone or root resorption (Fig 1). If there had been a furcation or apical radiolucency, a successful pulpectomy had to show evidence of bone formation (Fig 2).

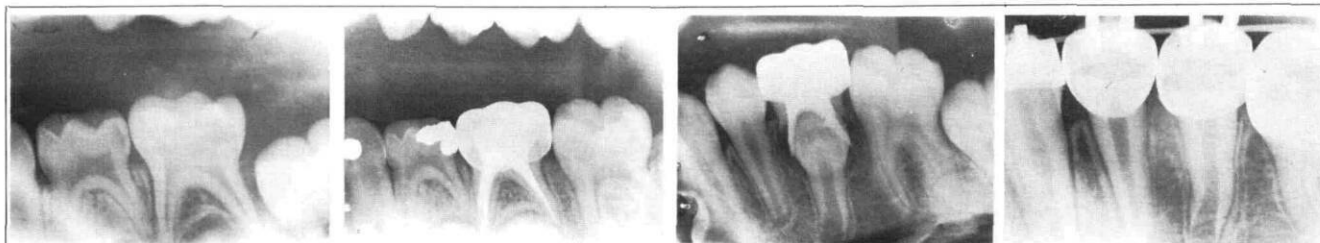
The clinical success of each pulpectomy was judged by one of the investigators (JAC) during routine recall appointments. Pulpectomies were evaluated radiographically by 2 of the investigators (JAC, JSC) viewing the preoperative and postoperative films independently. There was a 92% interrater agreement. In cases of disagreement, the radiographs were reevaluated. If disagreement still existed, the lower of the two ratings was used.

Pulpectomies judged to be radiographic failures showed pathologic bone or root resorption (Fig 3). The presence of a small amount of extruded filling material in a clinically successful tooth, without pathologic bone or root resorption, was not considered a failure.

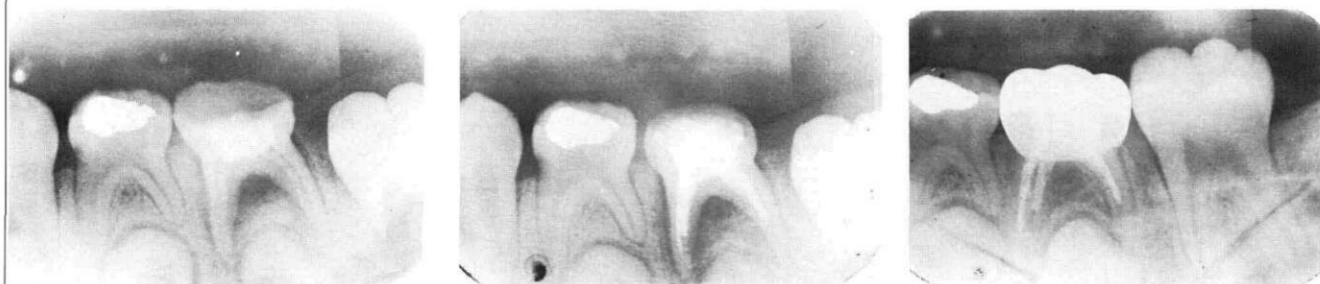From the first posttreatment examination, an evaluation was made to determine if pulpectomized molar roots resorbed faster, slower, or at the same rate as contralateral molars without pulpectomies. In 15 children, the contralateral molar had a carious pulp exposure, but no clinical or radiographic signs of pulpal necrosis, and a 1-step, 5-min formocresol pulpectomy was completed.

The pulpectomy root resorption was evaluated independently by the 2 investigators (JAC, JSC) as having equal, more, or less root resorption than its contralateral molar. In cases of disagreement, the root resorption was rated the lower of the 2 rankings. Various factors including the patient's age and sex, time interval the treated tooth was in place, and type of molar treated were tested using a chi square analysis to determine if they affected the success of pulpectomies. Results were judged significant at  $p = .05$ .

The second posttreatment examination, which occurred 5 years or more following the initial therapy, assessed the exfoliation of the pulpectomized tooth and the success of the procedure. The same criteria for pulpectomy success were used. In addition, fac-



**FIG 1.** An example of a successful pulpectomy in a mandibular second molar showing no pathologic root resorption: **A.** (left) preoperative film, patient age 5 years; **B.** (center left) 16 months postoperative film; **C.** (center right) 5 years, 5 months postoperative film showing exfoliation of pulpectomy; **D.** (right) 6 years postoperative film of erupted premolar. It had no signs of hypoplasia and erupted within a few months of the contralateral premolar.



**FIG 2.** An example of typical bone fill in a successful pulpectomy. The tooth previously had a pulpotomy which had failed. **A.** (left) Preoperative film, patient age 5 years; **B.** (center) Immediate postoperative film; **C.** (right) 8 months postoperative film showing bone fill.

**TABLE 1.** Patient Age of at Time of Pulpectomy Procedure

Rating at Initial Exam	Age				Total
	0-4 yr	4-5 yr	6-7 yr	8+ yr	
Failure	1	5	2	0	8
Success	8	15	8	2	33
Total	9	20	10	2	41

Chi square 1.27 at 3 df. not significant.

tors such as the root resorption of the pulpectomy and its contralateral molar, the incidence of retained

root canal filler, and the incidence of enamel defects in succedaneous premolars were investigated.

## Results

Using the criteria for pulpectomy success, 80.5% of the pulpectomized molars (33/41) were considered to be treated successfully at the first posttreatment evaluation. On reevaluation 5 years or more postoperatively, 86.1% (25/29) were considered successful. The first posttreatment examination was performed 6-36 months after treatment (mean = 21 months).

**TABLE 2.** Root Resorption in Pulpectomy vs Contralateral Molar at Initial Posttreatment Examination

Status of Root Resorption in Pulpectomy Initial Exam	State of Contralateral Molar			Total
	Extracted	Pulpotomy	No Pulp Treatment	
No data available	6	0	1*	7
Pulpectomy resorbing more than contralateral molar	0	4	11	15
Pulpectomy resorbing equally to contralateral molar	0	8	8	16
Pulpectomy resorbing less than contralateral molar	0	3	0	3
Total	6	15	20	41

Chi square 41.22 at 6 df., significant at .01 level.

\* Note that in one case, data were not available due to inadequate radiograph of the contralateral molar.

The second posttreatment examination was performed 60-82 months after treatment (mean = 70 months), in which 9 maxillary and 20 mandibular molars were reevaluated.

The age at the time of treatment had no significant effect on the success of therapy at the initial postoperative examination (Table 1). A chi square analysis comparing the success of pulpectomies in place 6 months and those in place 24-36 months was not significant. A chi square analysis was used to evaluate if maxillary, mandibular, first, or second primary molars tended to have more success than the other molars when treated with a pulpectomy. No significant difference was found between the different primary molar pulpectomy success rates.

At the first postoperative evaluation, 34 of 41 teeth with pulpectomies and their contralateral molars were available for comparison; in the 7 remaining patients, the pulpectomy's contralateral molar was extracted or the radiograph was inadequate. A chi square analysis (Table 2) comparing the root resorption in pulpectomized teeth with their contralateral molar was significant and demonstrated that the pulpectomized molars tended to have equal or more root resorption if their contralateral teeth had no pulp treatment. However, inspection of the results in Table 2 shows pulpectomies and contralateral pulpotomies have similar amounts of root resorption.

At the initial posttreatment examination, the 34 pulpectomies also were assessed to see if failed pulpectomies showed more resorption than those rated successful (Table 3). The chi square test was significant indicating that pulpectomies rated as failures tended to have increased root resorption compared to their contralateral molars, but similar resorption if rated successes.

The second examination 60 or more months postoperatively (mean = 70 months), evaluated 29 of the 41 pulpectomies in 26 patients. The remaining pulpectomy patients were unavailable. At the second examination, 17 of the 29 molar pulpectomies in 16 patients had been replaced by a premolar. Of these 17 teeth, 13 pulpectomies had been rated successes

at the initial examination, and remained successes at subsequent recall exams until eruption of the premolar; 4 were rated failures. Two of the teeth with failed pulpectomies were extracted while the other 2 exfoliated within 1 year of treatment.

Of the 17 premolars which erupted, 2 teeth had small enamel defects, 1 of which required a restoration. There was no statistical difference in the prevalence of enamel defects between the failed and successful pulpectomies.

The frequency of retained ZOE cement also was investigated. In 8 of the 17 patients, small pieces (approximately 1mm × 1mm) of ZOE root canal filler were discovered radiographically in the gingival sulcus at time of premolar eruption (Fig 3). No statistically significant difference in the rate of ZOE retention was found when comparing the successful vs failed pulpectomies.

The 12 of 29 pulpectomies that were reexamined 5 years or more postoperatively but which had not exfoliated were rated successful initially, and continued to be rated successes for the subsequent recall appointments. These 12 pulpectomies were in 10 patients.

The teeth also were evaluated to determine if root resorption and exfoliation occurred earlier or later than the contralateral teeth (Table 4). Inspection of the results showed that teeth with pulpectomies and pulpotomies had similar types of root resorption, but pulpectomized teeth tended to resorb faster and exfoliate earlier than contralateral teeth that had no pulp therapy.

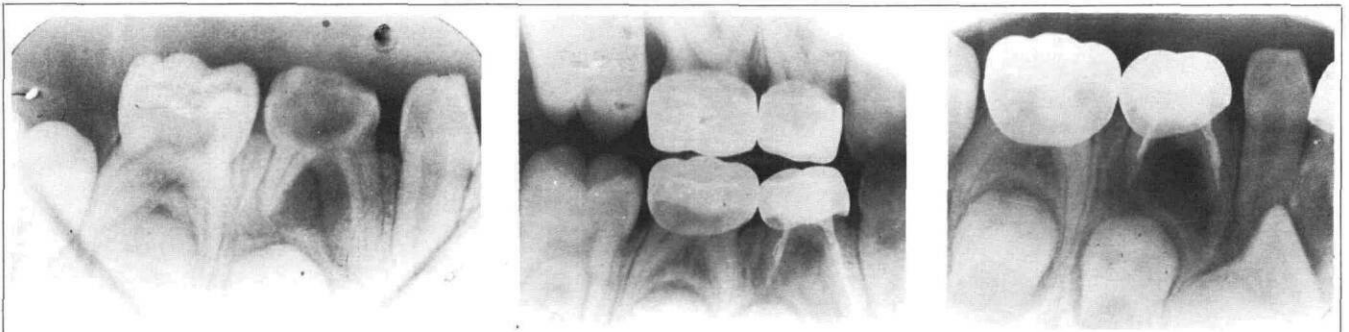
## Discussion

The results of this study show that a 1-appointment pulpectomy was successful in more than 80% of the teeth treated as verified by clinical and radiographic examinations. Successful pulpectomies were clinically asymptomatic and showed no radiographic signs of pathologic bone or root resorption at the time of exfoliation or on follow-up examination 5 years or more postoperatively. The results suggest that this

TABLE 3. Pulpectomy Rating vs Root Resorption at Initial Posttreatment Examination

<i>Pulpectomy Rating Initial Exam</i>	<i>Contralateral Molar Extracted or Inadequate Radiograph</i>	<i>Pulpectomy Resorbing More Than Contralateral</i>	<i>Pulpectomy and Contralateral Molar Resorbing Equally</i>	<i>Pulpectomy Resorbing Less Than Antimere</i>	<i>Total</i>
Failure	0	7	1	0	8
Success	7	8	15	3	33
Total	7	15	16	3	41

Chi square 11.26 at 3 df., significant at .01 level.



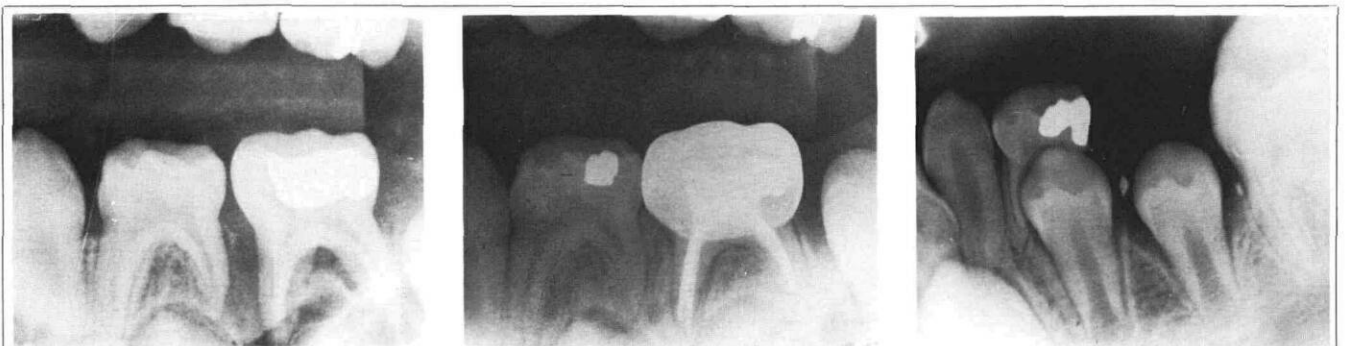**FIG 3.** A mandibular first primary molar treated with a pulpectomy that failed: **A.** (left) Preoperative film - note distal root resorption, patient age 5 years; **B.** (center) 8 months postoperative film; **C.** (right) 10 months postoperative film showing large radiolucency. Tooth was not painful but had a draining fistula and was extracted.

**TABLE 4.** Status of Pulpectomy Root Resorption vs the Contralateral Tooth 70 Months Postoperatively\*

70 months post-operatively; pulpectomy resorbing or exfoliated	State of Contralateral Molar			Total
	Extracted	Pulpotomy	No Pulp Tx	
Earlier than contralateral tooth	3	1	6	10
Same as contralateral tooth	0	8	7	15
Later than contralateral tooth	2	1	1	4
Total	5	10	14	29

$\chi^2 = 10.15$ ; prob. = .04; df = 4; sig. = .01.

\* Mean postoperative time, 70 months.



**FIG 4.** An example of a case wherein the ZOE root canal filler was retained in the gingival sulcus: **A.** (left) Preoperative film, patient age 5 years; **B.** (center) 8 months postoperative film, pulpectomy judged successful; **C.** (right) 5 years, 4 months postoperative film immediately after exfoliation. Note two pieces of ZOE. Premolar erupted without hypoplastic enamel defects.

technique is a viable alternative to extraction and space maintenance. The finding contradicts arguments previously noted that pulpectomies were time consuming, difficult to accomplish, or had questionable success.<sup>1-3</sup> If a pulpectomy failed, it usually showed clinical or radiographic signs of failure in 6 months or less.

More failures were expected in the older patients, than in children under the age of 4 or 5 years because of greater secondary dentin deposition in the older child's root canals. It was felt the older patient's root canals would be harder to debride, and possibly would have less chance of success. However, the success of the pulpectomies was not significantly lower in the

older patient than in the younger patient. Also, the type of tooth treated had no significant effect on the pulpectomy's success. Pulpectomies in first primary molars tended to succeed as well as those in second primary molars, whether it was a maxillary or mandibular tooth.

In evaluating the relative root resorption of pulpectomized molar teeth, it was found that the roots tended to resorb faster when compared to contralateral molars which had no pulp therapy (Tables 2, 4). In those patients with a pulpectomy and a contralateral molar containing a pulpotomy, there tended to be no difference in the relative root resorption between the two. Previous investigators have shown that pulpotomies have increased root resorption.<sup>20</sup> The increased resorption following the pulpectomy may be a result of many factors, one of which could be due to the formocresol medicament. The increased root resorption and earlier exfoliation of pulpectomies shown in Table 4 contradicts the argument that successful pulpectomies tend to be overretained.<sup>14</sup>

Pruhs et al.<sup>21</sup> found a definite relationship between formocresol pulpotomies in primary teeth and enamel defects in the succedaneous premolars. Pulpectomies in the present study did not cause extensive hypoplasia to the permanent successors. Of 17 cases where the premolar had erupted, 2 had small areas of hypoplasia and only 1 of these required a restoration.

In almost half the patients that were followed until premolar eruption (8/17), ZOE was retained in the gingival sulcus area. This retention did not cause any apparent clinical problem and was curetted out of the sulcus in 2 of the 8 cases at the time of tooth exfoliation. Since ZOE is considered resorbable,<sup>22</sup> it is not believed that the retained ZOE will constitute a long-term problem. Since Erausquin and Muruzabal<sup>23</sup> have reported bone destruction and encapsulation of extruded ZOE in rat molars with a resulting resistance to resorption, further long-term investigation is needed regarding ZOE resorption.

## Conclusions

More than 80% of the molar pulpectomies in the present study were successful. The age of the patient at the time of treatment, the time interval the treated tooth was in place, and whether the tooth was a first or second molar in either jaw had no significant effect on the success rate of the pulpectomy.

It was found that successful molar pulpectomies tended to resorb at rates similar to the contralateral molars. Failed pulpectomies tended to have a faster rate of root resorption than contralateral molars. Successful pulpectomies and contralateral pulpotomies tended to resorb at equal rates. The pulpectomies that were followed until exfoliation were not overretained

and showed a low frequency of hypocalcified defects in the succedaneous premolar. In almost one-half the cases, ZOE root canal filler was retained in the gingiva once the bicuspid erupted.

In light of today's concerns about the use of formocresol, more studies should be performed comparing the success rates of various pulpotomy and pulpectomy procedures on nonvital primary teeth to determine the best method of treatment. Further research is needed to determine the best medicament to fill primary tooth root canals, and the effect, if any, that retained ZOE has on the patient's gingiva and alveolar bone. The success of pulpectomies found in the present study justifies the continued use of a 1-appointment pulpectomy procedure for the treatment of nonvital primary molars.

The authors acknowledge F. Richard Elliott, supervisor of medical photography, Baltimore College of Dental Surgery Dental School, University of Maryland at Baltimore.

Dr. Coll is in private practice, York, Pennsylvania and is a clinical assistant professor, and Dr. Josell is an associate professor, pediatric dentistry, Baltimore College of Dental Surgery, Dental School, University of Maryland at Baltimore, Department of Pediatric Dentistry, 666 W. Baltimore St., Baltimore, MD 21201. Dr. Casper is in private practice in Crofton, Maryland. Reprint requests should be sent to Dr. Coll.

1. Cohen MM: Pediatric Dentistry, 2nd ed. St Louis; CV Mosby Co, 1961 p 276.
2. Massler MM: Preventive endodontics: vital pulp therapy. *Dent Clin North Am* 11:663-73, 1967.
3. Brauer JC: Dentistry for Children, 5th ed. New York; McGraw-Hill Book Co, Inc, 1964 pp 480-86.
4. Velling RJ: A study of the treatment of infected and necrotic primary teeth. *J Dent Child* 28:213-17, 1961.
5. Feinglass JC: Pulpotomy technique to save abscessed deciduous teeth. *Dent Surv* 49:34, 1973.
6. Bly PE: One-sitting treatment for pulpless teeth. *Dent Surv* 46:27, 1970.
7. Droter JA: Formocresol in vital and nonvital teeth: a clinical study. *J Dent Child* 30:239-42, 1963.
8. Rabinowitch BZ: Pulp management in primary teeth. *Oral Surg* 6:542-50, 671-76, 1953.
9. Starkey PE: Methods of preserving primary teeth which have exposed pulps. *J Dent Child* 30:219-28, 1963.
10. Starkey PE: Management of deep caries and pulpally involved teeth in children, in *Current Therapy in Dentistry*, Vol 3, Goldman HM, Forrest SP, Byrd DL, McDonald RE, eds. St Louis; CV Mosby Co, 1968 pp 896-932.
11. Spedding RH: Root canal treatments for primary teeth. *Dent Clin North Am* 17:105-24, 1973.
12. McDonald RE, Avery DR: Dentistry for the Child and Adolescent, 3rd ed. St Louis; CV Mosby Co, 1978 pp 160-63.
13. Cartwright HV, Bevans JL: Management of two abscessed primary molars in a four-year child: report of interesting case. *J Dent Child* 37:230-36, 1970.
14. Starkey PE: Pulpectomy and root canal filling in a primary molar: report of a case. *J Dent Child* 40:213-17, 1973.
15. Gould JM: Root canal therapy for infected primary molar teeth — preliminary report. *J Dent Child* 39:269-73, 1972.
16. Rifkin AJ: A simple, effective, safe technique for the root canal

- treatment of abscessed primary teeth. *J Dent Child* 47:435-41, 1980.
17. Rifkin AJ: The root canal treatment of abscessed primary teeth — a three- to four-year follow up. *J Dent Child* 49:428-31, 1982.
  18. O'Riordan MW, Coll J: Pulpectomy procedure for deciduous teeth with severe pulpal necrosis. *JADA* 99:480-83, 1979.
  19. Goerig AC, Camp JH: Root canal treatment in primary teeth: a review. *Pediatr Dent* 5:33-37, 1983.
  20. Morawa AP, Straffon, LH, Han SS, Corpron RE: Clinical evaluation of pulpotomies using dilute formocresol. *J Dent Child* 42:360-63, 1975.
  21. Pruhs RJ, Olen GA, Sharma PS: Relationship between formocresol pulpotomies on primary teeth and enamel defects on their permanent successors. *JADA* 94:698-700, 1977.
  22. Barker BC, Lockett BC: Reaction of dog tissue to immediate filling with zinc oxide cement and gutta percha. *Aust Dent J* 17:1-8, 1972.
  23. Erausquin J, Muruzabal M: Root canal fillings with zinc oxide-eugenol cement in the rat molar. *Oral Surg* 24:547-58, 1967.
- 

### Quotable quote: man in need of help

Living systems have a remarkable capacity to rearrange themselves in the face of any disturbance which threatens their continued existence, but if the destructive forces are severe and unremitting, they begin to deteriorate irreversibly; the various acts of adjustment interfere with one another, and the system becomes incoherent and self-destructive.

The ability to recognize and anticipate this point of no return sets man apart from other animals. A sick creature can lie low, lick its wounds and take the weight off an injured paw, but since it is not fully self-conscious, it is unable to appreciate its status as a threatened individual. Man, on the other hand, is endowed with the capacity to reclassify himself as something in need of help. Knowing that something has gone wrong, he seeks a remedy, either by using recipes which are the common property of the society in which he lives, or by consulting someone who is credited with special mastery of the healing art. Several factors determine how this credit is established. Tradition and precedent are the most obvious, though not necessarily the most important. If a healer already is known to have a large clientele, that in itself may be enough to attract new customers, and since many illnesses get better of their own accord, and the uninformed client is incapable of distinguishing between spontaneous remissions and deliberate cures, even a quack will be able to advertise a list of satisfied sufferers.

Miller, J. *The Body in Question*. New York; Vintage Books. 1978.  
p 56.