

Longitudinal changes in the width of attached gingiva in children

Enrique Bimstein, CD Eliezer Eidelman, DrOdont, MSD

Abstract

The width of the attached gingiva of 54 children 12-14 years old was measured and compared with its width measured five years before. The width of the attached gingiva of 96 mandibular permanent central incisors at the second examination was grouped according to its width at the first examination. In addition, the width of the attached gingiva of 67 mandibular central incisors, at both examinations, was grouped according to the width of the attached gingiva of the mandibular primary molars at the first examination. Eighty-four per cent of the incisors with less than 1 mm of attached gingiva at the first examination, showed an increase in width of the gingiva with time. A similar increase was evident in 30% of the incisors which had 1 mm or more of attached gingiva at the first examination; only 12% showed a decrease. No correlation was found between the width of the attached gingiva of the permanent incisors and that of the mandibular primary molars. These findings should be taken into consideration when mucogingival surgery in children is considered.

Longitudinal and cross-sectional epidemiologic studies have demonstrated that during the transition from the primary to the permanent dentition, a decrease in the width of the band of attached gingiva takes place.¹ After this initial decrease, with tooth eruption, a gradual increase takes place leading to a band of attached gingiva which is wider in adults than in the primary dentition.² Because of these developmental changes, the clinician often faces situations in which a narrow band of attached gingiva is present in the mandibular incisor area of children, and he is required to determine the prognosis and the possible need for surgical intervention. To solve this question the available epidemiological data may be helpful but insufficient since they indicate general tendencies only. The purpose of the present study is to examine the possibility of prediction of the

future width of the attached gingiva of the mandibular permanent central incisors from its width in the early mixed dentition period or from the width of the attached gingiva of the mandibular primary molars.

Materials and Methods

A total of 54 children (12-14 years of age), who participated in a previous study (Bimstein and Eidelman 1983), were available for re-examination five years after the baseline examination. The criteria for selection of cases required that no more than one tooth was missing in any posterior or anterior segment and that no advanced gingivitis or pulpal pathosis were evident.

Two measurements were completed at the midline of the buccal aspect of each tooth: the probing depth of the gingival sulcus and the width of the keratinized gingiva. The latter was established by measuring the distance from the margin of the free gingival margin to the mucogingival junction (Figure). In young children, stippling is extremely fine, and the greater vascularization gives the attached gingiva a reddish color, making it difficult to distinguish it from the alveolar mucosa. Therefore, we used the jiggle method to delineate the mucogingival junction (Oschenbein and Maynard 1974). The measurements were carried out with a periodontal probe calibrated in millimeters and all fractionated measurements rounded to the nearest millimeter.

The width of the attached gingiva was calculated by subtracting the probing depth from the width of the keratinized gingiva.³ Ninety-six mandibular permanent central incisors were present at both examinations; for 67 of them the width of the attached gingiva of the mandibular primary molars at the first examination was available. The mean widths of the band of attached gingiva at the mandibular permanent central incisors at the second examination were grouped according to their mean in the first examination. The mean widths of the attached gingiva at the mandibular permanent cen-

¹ Bimstein and Eidelman 1983; Tenenbaum and Tenenbaum 1986; Bimstein et al. 1986.

² Bowers 1963; Rose and App 1973; Vincent et al. 1976.

³ Rose and App 1973; Vincent et al. 1976; Hall 1977.

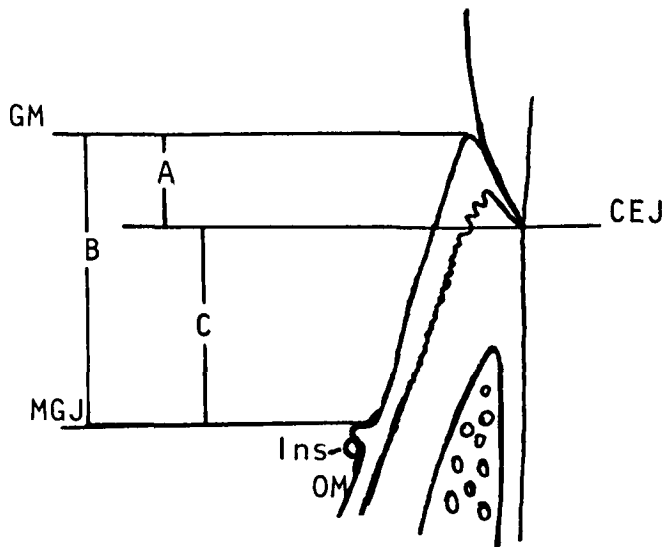


FIGURE. Schematic drawing showing the location of the measurements: probing depth (A) from the free gingival margin (GM) to the cemento-enamel junction (CEJ); width of keratinized gingiva (B) from the GM to the mucogingival junction (MGJ) which was delineated by jiggling the oral mucosa (OM) with a blunt instrument (Ins). The width of the attached gingiva (C) was obtained by deducting A from B.

tral incisors at both examinations were grouped according to the mean width of the attached gingiva of both mandibular primary molars in the first examination.

Results

When the width of the attached gingiva in the mandibular permanent central incisors was less than 1.0 mm in the first examination, an increase in width was observed in 84% of the teeth. Eight-eight per cent of the mandibular permanent central incisors with 1 mm or more of attached gingiva at the first examination showed a similar or wider attached gingiva at the second examination whereas only 12% of them showed a decrease in width (Table 1).

Chi square statistical examination failed to show dependence between the measurements at both examinations ($X = 4.42$). However, in the group of mandibular permanent central incisors which had less than 1 mm of attached gingiva in the first examination, the 88% of teeth that showed an increase in width with time proved to be significant (test for significance of a proportion, $Z = 14.07$, $P < 0.001$). Furthermore, in the group of permanent incisors with 1 mm or more of attached gingiva at the first examination, a significant difference was found between the 12% of teeth which had a decrease in attached gingiva and the 30% which had an increase (test for significance between proportions, $Z = 2.66$, $P < 0.01$). In children who had, in the mandibular primary molars, a band of attached gingiva of more than 2 mm, (Table 2), the width of the attached gingiva of the

mandibular permanent central incisors at both examinations was not significantly larger (Student's t -test, $P > 0.05$).

Discussion

Mucogingival surgery in children has been recommended based on the assumption that if an inadequate band of attached gingiva is not rectified in childhood, it may lead to an advanced mucogingival defect in adulthood (Oschenbein and Maynard 1974; Ashrafi et al. 1985). However, the clinician should be aware that in children: (1) due to the reduction in width of the attached gingiva during the transition from the primary to the permanent dentition, areas with less than 1 mm of attached gingiva are normal (Bimstein et al. 1986); (2) there is an improvement potential of isolated gingival recession when gingival inflammation is controlled (Powell and McEmery 1982), and due to developmental changes (Persson and Lennartsson 1986).

The present findings confirm that with tooth eruption an increase in the width of attached gingiva takes place (Smith 1982; Tenenbaum and Tenenbaum 1986) and in addition, they indicate that in the majority of the mandibular permanent central incisors, the width of the attached gingiva found in the early permanent dentition remains the same or increases in the next few years.

The fact that correlations in tooth size are used for orthodontic space analysis (Sim 1977) led us to the hypothesis that the width of the attached gingiva of the primary molars could correlate to the width of the attached gingiva of the permanent incisors. However, the present findings failed to demonstrate the hypothesis that the width of the attached gingiva at the mandi-

TABLE 1. Mean Width of the Band of Attached Gingiva at the Mandibular Incisor Area at Second Examination, Based on Its Mean Width at the Base-line Examination

Width at the First Examination	Width at the Second Examination							
	0-0.9 mm		1.0-1.9 mm		≥2.0 mm		Total	
	N	%	N	%	N	%	N	%
0-0.9 mm	7	26	16	59	4	15	27	100
1 mm or more	8	12	40	58	21	30	69	100

TABLE 2. Mean Width of the Band of Attached Gingiva at the Mandibular Permanent Incisors at the First Examination and after 5 Years, According to the Width of Attached Gingiva at the Mandibular Primary Molars at the First Examination*

Width at Mandibular Primary Molar at First Examination	Width at the Permanent Incisors			
	First		Second	
	\bar{x}	SD	\bar{x}	SD
<2 mm	0.79	0.61	1.10	0.67
>2 mm	0.84	0.54	1.23	0.54

* Average width of both first and second molars.

bular primary molars in the early mixed dentition period can be used as an indicator of the future width of attached gingiva at the mandibular permanent central incisors in the early permanent dentition.

Dr. Bimstein is a senior lecturer and Dr. Eidelman is a professor and chairman, pediatric dentistry, Hebrew University, Jerusalem, Israel. Until July 15 reprint requests should be sent to: Dr. Enrique Bimstein, Dept. of Pediatric Dentistry, University of Texas Dental School, Health Science Center at San Antonio, 7703 Floyd Curl Dr., San Antonio, TX 78284. After July 15 requests should be sent to him at Hebrew University, Hadassah Faculty of Dental Medicine, PO Box 1172, Jerusalem, Israel.

Ashrafi MA, Meister M Jr, Meister RC: Mucogingival problems in children: three surgical techniques. *Gen Dent* 33:425-28, 1985.

Bimstein E, Eidelman E: Dimensional differences in the attached gingiva and gingival sulcus in the mixed dentition. *J Dent Child* 70:264-67, 1983.

Bimstein E, Machtei E, Eidelman E: Dimensional differences in the attached and keratinized gingiva and gingival sulcus in the early permanent dentition: a longitudinal study. *J Pedod* 10:247-53, 1986.

Bowers GM: A study of the width of attached gingiva. *J Periodontol* 34:201-9, 1963.

Hall WB: Present status of soft tissue grafting. *J Periodontol* 48:587-97, 1977.

Oschenbein C, Maynard JG: The problem of attached gingiva in children. *J Dent Child* 41:263-72, 1974.

Persson M, Lennartsson B: Improvement potential of isolated gingival recession in children. *Swed Dent J* 10:45-51, 1986.

Powell RN, McEmery TM: A longitudinal study of isolated gingival recession in the mandibular central incisor region of children aged six to eight years. *J Clin Periodontol* 9:357-64, 1982.

Rose ST, App GR: A clinical study of the development of the attached gingiva along the facial aspect of the maxillary and mandibular anterior teeth in the deciduous transitional and permanent dentition. *J Periodontol* 44:131-39, 1973.

Sim JM: Four methods of arch space analysis, in *Minor Tooth Movement in Children*, 2nd ed, Sim JM, ed. St Louis; CV Mosby Co, 1977 pp 74-81.

Smith RG: A longitudinal study into the depth of the clinical gingival sulcus of human canine teeth during and after eruption. *J Perio Res* 17:427-33, 1982.

Tenenbaum H, Tenenbaum M: A clinical study of the width of the attached gingiva in the deciduous, transitional, and permanent dentition. *J Clin Periodontol* 13:270-75, 1986.

Vincent JW, Machen JB, Levin MP: Assessment of attached gingiva using tension test and clinical measurements. *J Periodontol* 47:412-14, 1976.

Nationwide glove shortage

Fear of AIDS is creating a glove shortage as everyone from policemen to prison guards to athletic trainers seeks protection from the disease.

To meet the unprecedented demand, nearly every major U. S. manufacturer of gloves for medical use is expanding production, but spokesmen for the manufacturers predict the shortage will worsen before the supply catches up to demand.

The gloves in shortest supply are examination gloves — the generally nonsterile variety that are lower in quality but less costly than procedure or surgical gloves. Exam gloves protect patients as well as doctors, nurses, technicians, therapists, and other staff from contamination during brief examinations or dressing changes.

Made of latex, or in some cases vinyl, exam gloves are sold to hospitals for about 7-10 cents each.

The American Dental Association recommends that gloves as well as a mask and protective eyewear be worn when treating all patients.