

## Glanzmann's thrombasthenia: prevention of bleeding complications using microfibrillar collagen and oral stints

William C. Berlocher, DDS  
Paul M. Zeltzer, MD

### Abstract

*Glanzmann's thrombasthenia is a rare coagulation disorder characterized by impaired platelet function during hemostasis. The management of bleeding in individuals with the disease is difficult because treatment options are few and in many instances only partially effective. The management of a patient with Glanzmann's thrombasthenia who had unremitting gingival hemorrhage is described. A microfibrillar collagen used in combination with oral splint therapy resulted in an immediate improvement in the patient's overall condition.*

The thrombasthenias are a group of rare coagulation disorders characterized by mucosal surface bleeding from the gingiva, nose, vagina, and anus. Laboratory investigations demonstrate a normal platelet count, but a prolonged bleeding time, poor clot retraction, and absence of platelet aggregation. The pathophysiologic process involves a failure to form the primary hemostatic plug with abnormalities of both primary and secondary platelet aggregation phenomena.<sup>1</sup> In Glanzmann's thrombasthenia (GT) platelets are of normal size, morphology, and number but have decreased amount of two specific membrane glycoproteins which may be related to impaired platelet function during hemostasis.<sup>2-4</sup> The disease is considered to be inherited according to an autosomal recessive pattern with equal incidence in both sexes, little or no bleeding in parents, and evidence of consanguinity in a number of reported cases.<sup>5</sup>

Currently, there is no specific treatment for GT. Oral iron supplements and packed red blood cell transfusions are used in patients with chronic hemorrhage. Palliative measures to control bleeding are at best only occasionally effective. Epsilon-aminocaproic acid, a commonly used drug in the treatment of a number of bleeding disorders because of its antifibrinolytic action on the blood clot, has no scientific rationale in treatment because GT is a platelet defect affecting the primary platelet plug and not the fibrin deposition mechanism. Platelet

transfusions are capable of managing acute hemorrhage, but carry the potential for stimulating the production of antibodies which suppress the effectiveness of further platelet therapy.<sup>6</sup>

Hemorrhage has been controlled during oral surgery without the infusion of blood or blood products using a microfibrillar collagen preparation as a local hemostatic agent.<sup>7</sup> We describe the successful use of this latter approach in combination with oral stint therapy in a patient with GT who had unremitting gingival hemorrhage.

### Case Report

#### Medical Evaluation

A 12-year-old, 75-pound caucasian male was referred to the Pediatric Dental Center by the Department of Pediatrics. The medical assessment indicated chronic gingival bleeding and iron deficiency anemia secondary to GT. The medical history revealed that GT had been suspected since the patient was less than one year of age, but the diagnosis of GT had not been confirmed by laboratory studies until age 10 when polyacrylamide gel analysis of platelet surface proteins became available.<sup>8</sup> The diagnostic criteria for GT are listed in Figure 1.

The patient had periodic episodes of epistaxis and oral hemorrhage since early childhood; this usually required hospitalization and treatment for severe anemia secondary to the chronic bleeding. Blood loss had been managed with whole blood, platelet transfusions, and iron supplements. Also, packed red blood cell transfusions had been given unsuccessfully to maintain a hemoglobin greater than 10 g/dl.

#### Dental Evaluation

A dental evaluation consisting of a visual and radiographic examination revealed the patient to have a transitional dentition. The teeth were well aligned and the arches well occluded. Carious lesions were found in the occlusal surfaces of the four first permanent molars and the lingual surface of the maxillary left permanent cen-

DIAGNOSTIC CRITERIA FOR GLANZMANN'S THROMBASTHENIA	LITERATURE	PRESENT CASE
Prolonged Bleeding Time	+	+
Abnormal Clot Retraction	±	-
Platelet Aggregation in the Presence of:		
Collagen	-	-
Epinephrine	-	-
ADP	-	-
Ristocetin	+	+
Normal Platelet Count & Morphology	+	+
Normal Prothrombin Time & Partial Thromboplastin Time	+	+
Consanguinity/Autosomal Recessive	+	+
Radioisotopic Analysis of Platelet Surface Glycoproteins on Polyacrylamide Gel	+	+

**Figure 1.** Diagnostic criteria for Glanzmann's thrombasthenia.

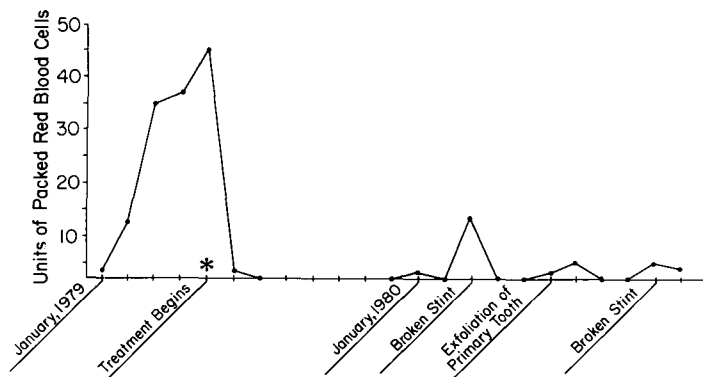
tral incisor. The mandibular second primary molars exhibited considerable root resorption and mobility. The maxillary second primary molars had moderate root resorption but the teeth were not yet mobile. Oral soft and hard tissues were otherwise healthy. The child's oral hygiene was poor and the gingival tissues were erythematous and edematous. Continuous gingival marginal hemorrhage was found in the maxillary and mandibular left posterior quadrants and slight marginal bleeding was evident around the remainder of the dentition. During the three months prior to the dental examination the patient required eight to 12 units (1600-2400 cc) of packed red blood cells every week for the management of anemia resulting from oral hemorrhage (Figure 2).

### Treatment

Subsequent to the dental evaluation, a consultation with the patient's pediatric hematologist resulted in a recommendation for dental treatment. The hematologist advised against local anesthetic injection because of the patient's compromised hemostatic mechanism.

On the day of the dental appointment, the patient received two units (400 cc) of packed red blood cells, raising his hemoglobin from eight to 10 g/dl. One hour prior to treatment a syrup containing meperidine (50 mg) and promethazine (25 mg) was given orally. During the dental procedure a mixture of 40% nitrous oxide/60% oxygen was administered. The teeth were isolated carefully with rubber dam, and restored with amalgam. Teeth were cleaned thoroughly with hand instruments, and maxillary and mandibular alginate impressions for study models were made. An acidulated phosphate fluoride gel (1.23% F ion) was applied to the teeth using styrofoam trays. At the completion of treatment, the patient was allowed to breathe 100% oxygen for five minutes and was then observed for one hour. At a 24-hour postoperative appointment, gingival bleeding was evident but no worse than prior to treatment.

Maxillary and mandibular soft, custom-adapted acrylic stints (mouthguards), fabricated from the study models, were inserted 24 hours after completion of the



**Figure 2.** Units of packed red blood cells necessary pre- and postoperatively for the management of patient's anemia secondary to oral hemorrhage.

restorative procedure (Figure 3). A microfibrillar bovine collagen<sup>a</sup> was placed on the tissue surface of the stints prior to placement. Moderate pressure was used to hold the mouthguards in place until bleeding had ceased.

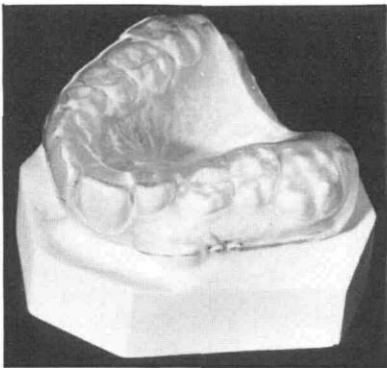
After an observation period to ensure that hemorrhage had stopped, the amalgams were polished carefully. The patient and parents were given oral hygiene counseling which stressed extremely gentle but thorough removal of oral plaque and debris. They were instructed to wear the mouthguards initially without the collagen whenever gingival bleeding was encountered and to use the collagen with the stints only if hemorrhage persisted.

The patient reported using the stints without collagen for spontaneous hemorrhage approximately once a week over a 17-month postoperative evaluation period. With the oral stint therapy and improved oral hygiene, continuous gingival bleeding was reduced to only periodic episodes (Figure 2). The patient was not hospitalized for his disease during the postoperative period and the need for transfusions was substantially reduced. Postoperative bleeding episodes were associated with the patient's loss of the stints and the exfoliation of primary teeth, and were treated successfully with new stints in combination with the collagen.

### Discussion

The treatment plan was twofold. First, pathosis was treated while causing as little additional hemorrhage as possible. Second, an attempt was made to control the chronic gingival bleeding using a local hemostatic agent and protective oral stints. A major concern in restoration therapy was the stimulation of additional bleeding. Conventional dental restorative therapy often involves trauma to oral tissues from the local anesthetic injection and manipulation. Injury to medium- to small-sized blood vessels precipitates the rapid formation of platelet plugs which form effective seals in the vessels within minutes.<sup>9</sup> In the oral and perioral regions of the face, where small diameter vessels predominate, the ability of platelets to aggregate properly is extremely important. If

<sup>a</sup> Avicon, Inc., Fort Worth, TX.



**Figure 3.** Example of soft, custom-adapted acrylic stent used in treatment.

platelets do not function effectively, as in the thrombasthenias, any treatment in the oral cavity must be accomplished acknowledging that a vital portion of the coagulation mechanism is absent.

Conscious sedation technics have been developed which produce levels of analgesia sufficient to accomplish a number of dental procedures in children, avoiding local anesthesia.<sup>10, 11</sup> These are unusual approaches that require substantial training and experience on the operator's part. A procedure of this nature seemed particularly applicable to this case since injections were to be avoided. A mixture of equal parts of meperidine elixir (50 mg/5 cc) and promethazine syrup (25 mg/5 cc) administered as 1 mg of the mixture per pound body weight provided adequate analgesia for tooth preparation when combined with nitrous oxide-oxygen sedation. Placement of a rubber dam minimized the danger of accidental injury to the oral tissues. The rubber dam clamp was carefully placed, using a cotton gauze pad which reduced impingement of the gingival tissues adjacent to the clamp.

There have been no reports concerning the management of chronic gingival bleeding in children with GT. Fresh whole blood, platelet-rich plasma and platelet concentrates are effective treatments for bleeding. Unfortunately, platelet transfusion carries the risk of hepatitis B infection. In addition these patients, who lack the PI<sup>A1</sup> antigen, may develop antibodies to normal platelet antigens and become unresponsive to further platelet therapy.<sup>8</sup>

Spontaneous gingival hemorrhage in persons with other forms of bleeding disorders has been minimized through the maintenance of good oral hygiene.<sup>12</sup> While recognizing the potential value of oral hygiene for this patient, it was felt the initiation of hygiene measures should be delayed until hemorrhage had been controlled. At the time of treatment, the patient was receiving between 1600 and 2400 cc of packed red blood cells every week for the management of anemia secondary to blood loss from his oral cavity. The implementation of immediate hygiene procedures would have aggravated this condition and stimulated more hemorrhage.

The principle behind using microfibrillar collagen for the management of the bleeding is sound. In persons

with GT, platelet aggregation in the presence of collagen is usually absent. However, it has been demonstrated that thrombasthenic platelets will adhere in normal numbers to a microfibrillar collagen extract.<sup>13</sup> The material can be used to reduce bleeding in patients with GT. Although this patient's laboratory studies failed to demonstrate platelet aggregation with collagen, treatment with the extract material was effective in obtaining hemostasis. It had the added benefit of eliminating hepatitis risk and the possibility of antibody development, because the patient was not infused with a blood product.

Oral stints usually are not indicated in the treatment of bleeding disorders because, unless a stint is correctly designed and constructed, it can easily initiate more bleeding or camouflage existing bleeding. The primary purpose of stints was to act as a means for placing and retaining the collagen material along the gingival marginal area. The stints also provided the added benefit of creating an environment at the wound site that seemed to facilitate the formation of a blood clot and then protect the established clot from displacement. The combination of a local hemostatic agent with oral stints for hemostasis and stint therapy alone for minor bleeding episodes resulted in an immediate improvement in the patient's overall condition. In the five months preceding dental treatment, the patient had required seven hospital admissions, approximately 2000 cc of packed red blood cells every week and two to three weekly outpatient hematology evaluations for treatment of anemia secondary to chronic bleeding. During the 17-month postoperative evaluation period, the child did not require a hospital admission for the management of his disease and his need for transfusions diminished substantially.

Dr. Berlocher is assistant professor, Department of Pediatric Dentistry; and Dr. Zeltzer is assistant professor, Department of Pediatrics, Division of Hematology-Oncology, and junior faculty clinical fellow of the American Cancer Society—#542, The University of Texas Health Science Center at San Antonio, 7703 Floyd Curl Dr., San Antonio, TX 78284. Requests for reprints should be sent to Dr. Berlocher.

1. George, J.M. and Reiman, T.R. Inherited disorders of the platelet membrane, in *Textbook of Hemostasis and Thrombosis*, eds. Coleman, R.W., Hiroh, J.L., Salzman, E.W., Marder, V.J. Philadelphia, J.B. Lippincott Co., 1981.
2. Norden, A.T. and Caen, J.P. An abnormal platelet glycoprotein pattern in three cases of Glanzmann's thrombasthenia. *Br J Haematol* 28:253, 1974.
3. Phillips, D.R., Jenkins, C.S.P., Luscher, E.F., and Larrieu, M.J. Molecular differences of exposed surface proteins on thrombasthenic platelet plasma membranes. *Nature* 257:599, 1975.
4. Phillips, D.R. and Agin, P.P. Platelet membrane defects in Glanzmann's thrombasthenia, evidence for decreased amounts of two major glycoproteins. *J Clin Invest* 60:535, 1977.
5. Caen, J.P., Castaldi, P.A., LeClerc, J.C., Inceman, S., Larrieu, M.J., Probst, J., and Bernard, J. Congenital bleeding disorders with long bleeding time and normal platelet count, Glanzmann's thrombasthenia: report of fifteen patients. *Am J Med* 41:4, 1966.
6. Degos, L., Dautigny, A., Brouet, J.C., Colombani, M., Ardaillou, N., Caen, J.P., and Colombani, J. A molecular defect in thrombasthenic platelets. *J Clin Invest* 56:236, 1975.

7. Perkin, R.F., White, G.C., and Webster, W.P. Glanzmann's thrombasthenia, report of two oral surgical cases using a new microfibrillar collagen preparation and EACA for hemostasis. *Oral Surg* 47(1):36, 1979.
8. Kunicki, T.J. and Aster, R.H. Deletion of the platelet-specific alloantigen  $PI^{AI}$  from platelets in Glanzmann's thrombasthenia. *J Clin Invest* 61:1225, 1978.
9. Hugues, J. Agglutination precoce des plaquettes au cours de la formation du clou hemostatique. *Thrombos Diathes Haemorrh.* 3:177, 1959.
10. Simon, J.R. and Vogelsberg, G.M. Use of nitrous oxide inhalation sedation for children, in *Behavior Management in Dentistry for Children*, ed. Wright, G. Philadelphia, W.B. Saunders Co., 1975.
11. Berlocher, W.C. and King, D.L. Considerations in the dental management of the factor VIII-deficient child with inhibitors. *Pediatr Dent* 1:188, 1979.
12. Croll, T.P., Macko, D.J. and Hoyer, L.W. Dental treatment for a hemophilia A patient with circulating antibodies to Factor VIII. *J Pedo* 2:353, 1978.
13. Zucker, W.H. and Mason, R.G. Ultrastructural aspects of interactions of platelets with microcrystalline collagen. *Am J Pathol* 82:129, 1976.

## Quotable Quotes

Not only the disease-causing organism, but neighboring microbes may be the source of an infection's resistance to an antibiotic. Itzhak Brook and colleagues at the Naval Medical Research Institute in Bethesda, MD, report that penicillin treatment against a streptococcal infection can be foiled by other bacteria that break down the drug. In up to 25% of patients, penicillin treatment fails to eliminate Group A beta hemolytic streptococci, an infection that can lead to rheumatic fever and kidney disease in patients with pharyngitis or tonsillitis. Experiments in mice demonstrate that penicillin treatment is more effective in animals infected with streptococci alone than in those infected both with streptococci and strains of *Bacteroides* that produce an enzyme that inactivates penicillin. Brook has identified penicillin-resistant *Bacteroides* in the tonsils of patient with recurrent tonsillitis. Other drugs may be superior to penicillin because of effects on these "protective" microbes as well as on the streptococci.

From: Miller, J.A. *Science News*, Vol. 120, No. 24, 12 December 1981.

Ability tests are not biased against minority group members and can be used reliably to predict performance in school and on the job, according to a national panel. Nevertheless, test scores never should be used in isolation in decisions about educational and employment opportunities, the group recommended.

Concluding a four-year review of the literature on ability testing, the panel of the National Academy of Sciences (NAS) reported rather large differences in the average test scores for racial and ethnic groups but urged that tests not be blamed for social injustice. Instead, educators and employers should recognize that test scores are not a fixed measure of intelligence and that motivation and remedial education ultimately can influence actual performance, the 19-member panel said.

The panel, convened amidst growing controversy over the fairness of standardized tests and the distribution of social opportunity, concluded that while test scores should not be worshiped blindly to the disadvantage of minority members, neither should minority scores be inflated artificially in order to guarantee minority candidates a quota of slots in school and the workplace. Noting that rigid affirmative-action policies have caused very useful tests to be abandoned, the group called for government guidelines that would allow employers legally to consider test scores as an indicator of future performance while still ensuring equal opportunity.

From: Herbert, W. *Science News*, Vol. 121, No. 5, 6 February 1982.