

Developmental orofacial deficits associated with multimodal cancer therapy: case report

R.J. Berkowitz, DDS P. Neuman, PhD, DDS P. Spalding, DDS, MS, MS
L. Novak, MD S. Strandjord, MD P.F. Coccia, MD

Abstract

Multimodal cancer therapy for pediatric head and neck tumors may be associated with significant developmental orofacial morbidity. This report details these effects in a child (C.I.) diagnosed at 2.5 years of age with a rhabdomyosarcoma, primary to the left buccinator. This case is of interest as C.I. has an unaffected identical twin (D.I.) for comparative study. Both were assessed by comparing panoramic radiographs and lateral and frontal tracings of cephalometric radiographs obtained at 8.25 years of age. C.I. had multiple dental anomalies which included agenesis, ectopia, crown malformation, and root malformation. Root malformation, ectopia, and agenesis were restricted to the left dentition, whereas crown malformation was noted bilaterally. C.I. had a generalized craniofacial skeletal hypoplasia relative to D.I. in all three planes, growth defects were greater on the side of the tumor, and the mandible was affected more than the nasomaxillary complex.

Introduction

Multimodal cancer therapy for pediatric head and neck tumors may be associated with significant developmental morbidity (Jaffe et al. 1984; Fromm 1986). This case report details the dental and craniofacial developmental deficits associated with this type of oncologic therapy in a 2-1/2 year old child with a rhabdomyosarcoma. This case is of interest since the patient (C.I.) had an unaffected identical twin (D.I.) who served as a reference.

Case History

C.I., a white male, presented to Rainbow Babies and Children's Hospital (Cleveland, Ohio) at 2.5 years of age with a rhabdomyosarcoma, primary in the left buccinator muscle. He was enrolled in the Children's Cancer Study Group (CCSG) Intergroup Rhabdomyosarcoma Study II (CALGB # 7891) Group III,

Regimen 26. Initially, he received chemotherapy with vincristine, Adriamycin®, and cyclophosphamide with no evidence of response in the primary tumor bed. The patient then received 25 radiation treatments in 41 days for a total dose of 5000 cGy to the left buccal primary tumor. Radiation therapy was delivered using a combination of weighted anterior-posterior fields as well as a single left lateral field (Fig 1). These ports were selected to spare the contralateral parotid gland and oral mucosa. The patient tolerated the radiation very well with a dramatic improvement in the palpable left buccal mass. At completion of treatment, an ulcerated 1.5 cm x 2.0 cm indurated mass remained in the left buccal mucosa. The residual tumor nodule was excised orally. The patient subsequently received a boost dose of radiation consisting of 1000 cGy directed laterally to the left buccal mucosa. This treatment utilized 12 MeV electrons. Subsequent treatment consisted of chemotherapy per the CCSG protocol cited above.

The patient is presently free of disease at 8.5 years of age. He has been off treatment for four years and currently is being followed at the University of Michigan.

Dental Findings

Comparison of panoramic radiographs obtained at 8.25 years of age from C.I. (Fig 2, page 228) and D.I. (Fig 3) demonstrate multiple developmental tooth defects

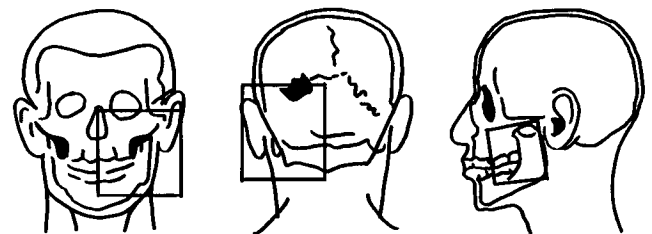


Fig 1. Diagrams of radiation therapy fields.

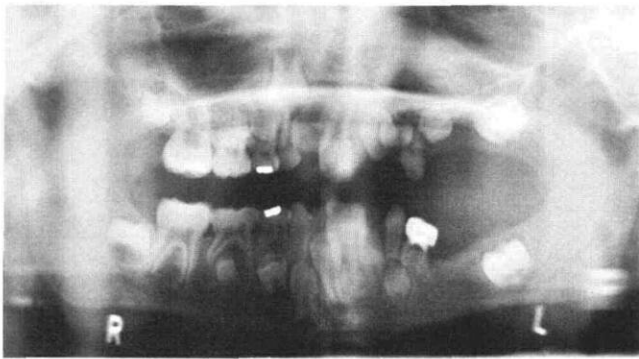

Fig 2. Photo of panorex X ray of C.I. obtained at 8.25 years of age.

associated with C.I.'s dentition. Partial dental deficits included: agenesia — teeth 13, 15, 18, 20; crown malformation — teeth 2, 4, 11, 21, 22, 29, 31; root malformation — teeth 9 and 10 (Fig 4) 11, 14, 19, 23, 24; and ectopia — tooth 11. In addition, root malformation and agenesia were restricted to the left dentition, whereas crown malformation was noted bilaterally (Fig 2).

Craniofacial Findings

The craniofacial skeletal patterns of C.I. and D.I. were assessed in three dimensions (anteroposterior, transverse, and vertical) using lateral and frontal tracings of cephalometric radiographs obtained at 8.25 years of age. Elements of the Grummons analysis (Grummons and Kappeyne 1987) the McNamara analysis (McNamara 1984), the Ricketts analysis (Ricketts et al. 1982), and the Ricketts four-position superimposition method (Ricketts et al. 1982) were used to describe various aspects of the craniofacial complex.

Maxilla: The position of the maxillary complex relative to the upper face was evaluated in the anteroposterior and vertical dimensions by superimposing the lateral cephalometric radiographic tracings along the basion-nasion line at CC point, the

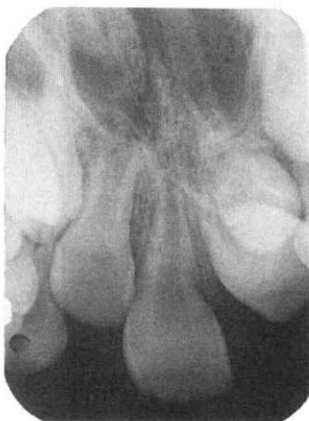


Fig 4. Photo of periapical X ray of teeth 7, 8, 9 and 10 of C.I.

intersection of the basion-nasion plane with a line from the posterior wall of the pterygomaxillary fissure to gnathion (Gn) as illustrated in Figure 5. The difference in the position of point A between the twins was compared. No vertical discrepancy was observed (Fig 5); however, a 7 mm difference in the anteroposterior position of point A was noted.

The transverse plane was assessed by com-

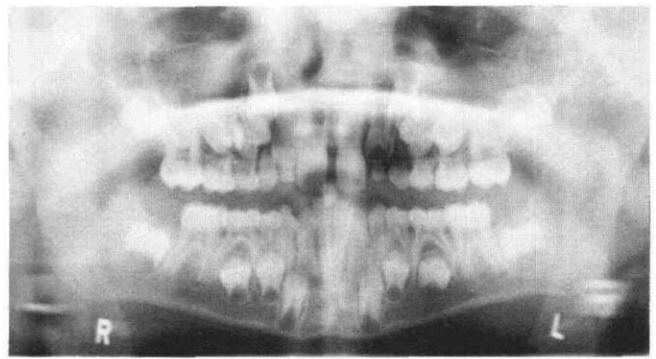


Fig 3. Photo of panorex X ray of D.I. obtained at 8.25 years of age.

paring tracings of the frontal cephalometric radiographs. Using the midsagittal reference line (MSR) from crista galli (Cg) to anterior nasal spine (ANS), the angles formed by the intersection of the following planes with MSR were measured; planes connecting the zygomaticofrontal suture (Z plane), the centers of the zygomatic arches (ZA plane), and the antegonial notches (Ag plane). Visual inspection of the frontal tracing (Fig 6) demonstrates that the ZA and Ag planes converge on the patient's left side and diverge on the right side. No such tendency is discernible on D.I.'s frontal tracing (Fig 6). These observations indicate that C.I.'s maxilla is tipped towards the side of the tumor in the transverse plane.

Mandible: The position of the mandible was evaluated in the anteroposterior and vertical dimensions by superimposing the lateral cephalometric tracings as described earlier (Fig 5). With this superimposition, a 2° difference of the facial axis (PT point — Gn) between the twins was measured (Fig 5). This observation indicates that there was little or no

alteration in mandibular posture during growth (relative to the basion-nasion plane). Differences in the anteroposterior and vertical position of the chin were determined by comparing the position of pogonion (PO) in the horizontal plane and menton (Me) in the vertical plane (Fig 5). Utilizing this method, the position of C.I.'s chin relative to D.I.'s was measured as 6 mm posterior and 11 mm superior.

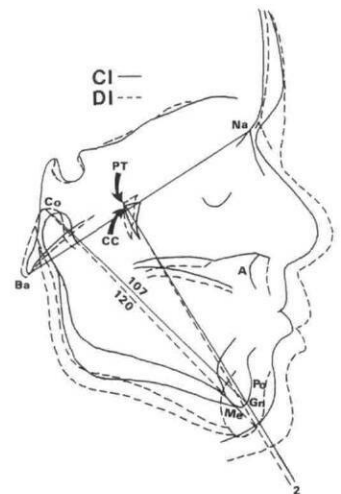


Fig 5. Superimposed tracings of lateral cephalometric X rays of C.I. and D.I.

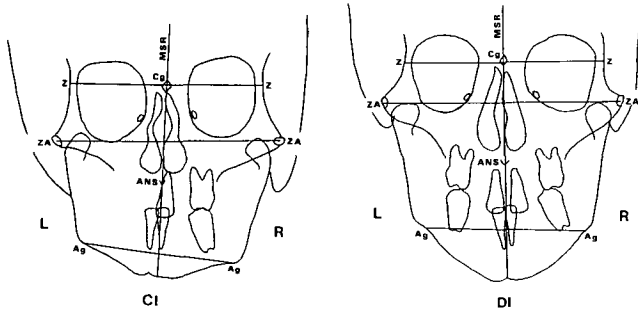


Fig 6. Tracings of frontal cephalometric X rays of C.I. and D.I. comparing maxillary symmetry.

The difference in mandibular length between the twins was determined by comparing the distance from condyion (Co) to Gn (Fig 5). The Co-Gn line was 13 mm shorter in C.I. (107 mm) relative to D.I. (120 mm, Fig 5).

The transverse dimension was assessed by comparing tracings of frontal cephalometric radiographs. Left and right triangles were formed by lines connecting the antegonial notches (Ag), menton (Me), and condyion (Co) (Fig 7). Inspection of C.I.'s right and left triangles (Fig 7) clearly indicates profound asymmetry of mandibular morphology, the more severe deficiency being left-sided. In contrast, D.I. does not exhibit this asymmetry (Fig 7). Cephalometric measurements of mandibular length (Co-Me), ramal length (Co-Ag), corpus length (Ag-Me), and intercondylar width (Co-MSR right + Co-MSR left) also demonstrate gross mandibular asymmetry for C.I. and relative mandibular symmetry for D.I. (Fig 7, Table). In addition, these data (Table 1) demonstrate that C.I. sustained bilateral mandibular growth deficits relative to D.I. In particular, all measured parameters were deficient on the left side (Table 1). Right-sided deficits included mandibular length (Co-Me) and corpus length (Ag-Me, Table 1).

TABLE 1. Cephalometric Measurements of Mandible in the Transverse Plane

	Co-Me ¹	Co-Ag ²	Ag-Me ³	Co-MSR ⁴	Co-Co ⁵
C.I.					
Right	91 mm	67 mm	43 mm	50 mm	93 mm
Left	80 mm	58 mm	35 mm	43 mm	
D.I.					
Right	115 mm	67 mm	50 mm	50 mm	101mm
Left	116 mm	65 mm	52 mm	51 mm	

1. Co-Me: condyion to menton line; measures mandibular length.
2. Co-Ag: condyion to antegonial notch line; measures ramal length.
3. Ag-Me: antegonial notch to menton line; measures corpus length.
4. Co-MSR: condyion to midsagittal reference line.
5. Co-Co: condyion to condyion line; measures intercondylar width.

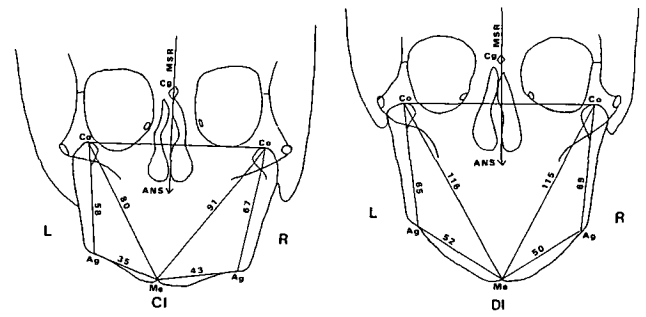


Fig 7. Tracings of frontal cephalometric X rays of C.I. and D.I. comparing mandibular symmetry.

Facial Skeleton: Transverse skeletal deficits of the upper, middle, and lower face were assessed by comparing right- and left-sided cephalometric measurements of frontal cephalometric tracings (Fig 8). These measurements included: condyion to midsagittal reference line; zygomaticofrontal suture (Z) to MSR; zygomatic arch (ZA) to MSR; and antegonial notch to MSR (Fig 8). Visual inspection and comparison of right and left sided cephalometric measurements of C.I.'s frontal tracing (Fig 8) demonstrates a linear asymmetry of his midfacial skeleton (ZA-MSR and Co-MSR) and relative symmetry of his upper (Z to MSR) and lower (Ag-MSR) facial skeleton. Identical analysis of D.I.'s facial skeleton demonstrates no linear asymmetries.

Deficits in height of the facial skeleton were assessed by comparing cephalometric measurements of lateral cephalometric tracings. These measurements included: total face height (TFH, Na -Me); upper facial height (UFH, Na-ANS); and lower facial height (LFH, ANS-Me). D.I.'s TFH was 124 mm and C.I.'s was 110 mm. This 14 mm difference represents an 11.3% deficit in TFH of C.I. relative to D.I. Differences in LFH and UFH between D.I. and C.I. were 11 mm and 3 mm respectively. These findings indicate that 78.6% (11/14) of the difference in TFH was due to a deficit in LFH.

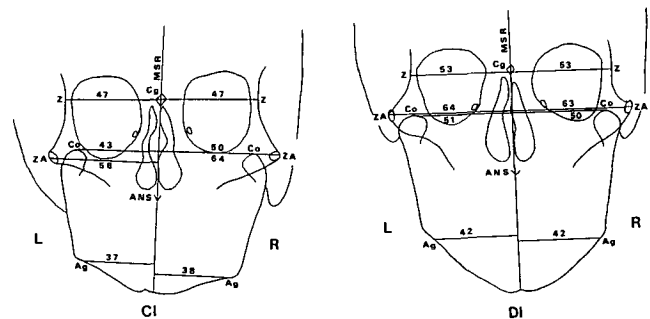


Fig 8. Tracings of frontal cephalometric X rays of C.I. and D.I. comparing facial symmetry.

Discussion

Dental Development

Animal model studies (Donohue and Perreault 1964; Lindvall et al. 1972; Matakı 1981) demonstrate that odontogenesis can be impaired by chemotherapeutic agents and radiation. Human case reports (Gorlin and Meskin 1963; Weyman 1968; Jaffee et al. 1984; Fromm et al. 1986) indicate that exposure of developing dental tissues to therapeutic dosages of radiation is associated with dental maldevelopment. Two recent clinical investigations (Rosenberg et al. 1987; Purdell-Lewis et al. 1988) demonstrate that chemotherapy alone may be associated with abnormal development of dental tissues. These studies also indicate that the severity of dental malformation depends on the stage of tooth development and type and dosage of antineoplastic agent(s) employed. In this regard, the findings of this report are consistent with this concept. Defects in C.I.'s dental development were most severe on the side of the tumor (C.I.'s left buccal segments, Fig 2). These odontogenic tissues were exposed to several chemotherapeutic drugs and were located directly in the radiation ports. Multiple developmental dental defects are present (Fig 2, described earlier in this report). The agenesis of teeth 12, 13, 15, 18, and 20 implies that all odontogenic cellular elements located directly in the radiation fields were ablated. In contrast, comparison of dental development of the right first molars (teeth 3 and 30) between C.I. and D.I. (Figs 2 and 3) indicate that root formation was not clinically impaired by the combined effects of chemotherapy and scatter radiation. However, comparison of dental development of the right second molars (teeth 2 and 31) between the twins indicates that crown formation was adversely affected by the combined effects of chemotherapy and scatter radiation.

Craniofacial Development

Assessment of craniofacial growth in pediatric patients receiving head and neck cancer therapy usually is constrained by the lack of a suitable control. Earlier reports (Nwoku and Koch 1975; Jaffee et al. 1984; Fromm et al. 1986) have utilized differences in the subject's craniofacial symmetry or comparison of the subject's cephalometric measurements to population norms as the basis for demonstrating growth deficits. The present report employs an unaffected identical twin as a reference point for assessing craniofacial growth. Although it is realized that both environmental and genetic factors affect craniofacial growth, the use of an unaffected identical twin as a control minimizes important constraints imposed by the methodologies of the previous reports.

Analysis of the cephalometric data presented earlier in this report demonstrates that C.I. exhibited a generalized craniofacial skeletal hypoplasia in the anteroposterior, vertical, and transverse planes relative to D.I. The observed growth deficits were more severe on C.I.'s left side (the tumor side) as compared to his right side. These findings indicate that therapy-related deficits in craniofacial growth are not restricted to the side of the tumor. In addition, the growth retardation of C.I.'s mandible was affected more than his nasomaxillary complex. This observation suggests that certain structures appear to be at greater risk than others.

Current knowledge of the factors and processes that control craniofacial growth is fragmentary and characterized by divergent opinion (Fuller and West 1986). Thus, we are unable to propose specific mechanisms to explain the reported findings. This matter is further complicated by the fact that the exact degree of morbidity associated with all of the therapeutic variables is not known. It is well documented that radiation disrupts normal development of human skeletal tissues (Donohue et al. 1965; Nwoku and Koch 1975). However, the absolute minimum dose of radiation that will result in alteration of craniofacial growth is not known. Chemotherapy alone previously has not been reported as producing aberration in skeletal development in humans. However, the combined effects of chemotherapy and radiation on human skeletal development are unknown. In addition, in this case, the effect of surgical removal of a tumor primary to the buccinator muscle also may have had an effect on facial skeletal development (Fuller and West 1986).

In summary, this report details the deficits in dental and craniofacial growth associated with multimodal cancer therapy targeted at a pediatric facial tumor. The findings corroborate and extend earlier observations.

Dr. Berkowitz was an associate professor in the department of pediatric dentistry at the University of Texas Dental Branch (Houston) at the time of writing. Dr. Neuman is an associate professor in the department of orthodontics at the University of Texas Dental Branch (Houston). Dr. Spalding is an assistant professor in the department of orthodontics and pediatric dentistry at the University of Michigan (Ann Arbor). Dr. Novak is an assistant professor in the division of radiation oncology at Case Western Reserve University (Cleveland). Drs. Strandjord (SS) and Coccia (PFC) are associate professor (SS) and professor (PFC) in the department of pediatrics, division of hematology and oncology at the University of Nebraska (Omaha). Requests for reprints should be sent to: Dr. Robert J. Berkowitz, Dept. of Pediatric Dentistry, Children's National Medical Center, 111 Michigan Avenue, NW, Washington, D.C. 20010.

Donohue WB, Perreault JG: The effect of X-ray radiation on the growth of the teeth and jaw in kittens. *Arch Oral Biol* 9:739-50, 1964.

-
- Fromm M, et al: Late effects after treatment of 20 children with soft tissue sarcoma of the head and neck. *Cancer* 57:2070-76, 1986.
- Fuller D, West V: The functional matrix hypothesis—current concepts and conflicts. *Aust Orthod* 9:324-28, 1986.
- Gorlin R, Meskin L: Severe irradiation during odontogenesis: report of a case. *Oral Surg* 46:35-38, 1963.
- Grummons D, Kappeyne MA: A frontal asymmetry analysis. *J Clin Orthod* 21:448-65, 1987.
- Jaffee N, et al: Dental and maxillofacial abnormalities in long-term survivors of childhood cancer. Effects of treatment with chemotherapy and radiation to the head and neck. *Pediatrics* 73:816-23, 1984.
- Lindvall A, et al: The effect of roentgen irradiation on the formation of dentin in maxillary rat incisors. *Scand J Dent Res* 80:253-63, 1972.
- Mataki S: Comparison of the effect of colchicine and vinblastine on the inhibition of dentinogenesis in rat incisors. *Arch Oral Biol* 26:955-61, 1981.
- McNamara JA: A method of cephalometric evaluation. *Am J Orthod* 86:449-69, 1984.
- Nwoku AL, Koch H: Effect of irradiation injury on the growing face. *J Maxillofac Surg* 3:28-34, 1975.
- Purdell-Lewis DJ, et al: Long-term results of chemotherapy on the developing dentition: caries risk and developmental aspects. *Commun Dent Oral Epidemiol* 16:68-71, 1988.
- Ricketts RM et al: Orthodontic diagnosis and planning. *Rocky Mountain Orthodontics*, 1982.
- Rosenberg SW et al: Altered dental root development in long-term survivors of pediatric acute lymphoblastic leukemia. *Cancer* 59:1640-48, 1987.
- Weyman J: The effect of irradiation in developing teeth. *Oral Surg* 25:623-29, 1968.
-

Zoology lesson

According to the *Alumni Bulletin*, Indiana University School of Dentistry:

- Cows (and many other hooved animals) don't have maxillary anterior teeth. Their lower teeth bite against a hard pad.
- Moray eels have an extra set of teeth, located deep in the throat.
- The mouth of the lowland gorilla is very similar to that of humans. It has the same number of teeth, cusp numbers, and ridge formations.
- Male baboons challenge one another by displaying their canines. If a top-ranking baboon loses his canines, he may also lose his stature within the baboon society.
- Since the condition of teeth is fundamental to the survival of animals in the wild, occlusion problems are rare. If animals can't eat properly, they die.
- Elephant tusks are actually modified incisors. In addition to their tusks, elephants have four molars (two uppers, two lowers), which are exfoliated as they wear out. Elephants have six sets of molars in their lifetime. Many elephants in the wild die after they wear out their last set. Those having tooth trouble can experience dramatic weight loss of as much as 200-400 pounds.
- For a medical or dental procedure, elephants must not remain anesthetized for long; in a reclining position they may become paralyzed or suffocate under their own weight.
- A shark's tooth is actually a modified scale. It has no pulp, enamel or dentin.
- Fish are anesthetized with drops of anesthetic added to their water. During a medical or dental procedure, oxygenated water is constantly run over the gills.