

## Effect of trauma to the primary incisors on permanent successors in different developmental stages

Yocheved Ben Bassat, DMD    Ilana Brin, DMD  
Anna Fuks, CD    Yerucham Zilberman, DMD

### Abstract

*This clinical and radiographic investigation was undertaken in an attempt to correlate the developmental stage of the permanent tooth buds, the chronological age at the time of trauma, and the degree of primary root resorption with mineralization defects in the permanent successors.*

*One hundred children who had experienced trauma to their primary incisors were recalled and their immediate posttrauma radiographs were examined. Sixty-four exhibited possible signs of previously unnoticed and unreported trauma and were eliminated from the study. This high percentage of unnoticed injury indicates the need for careful radiographic examination to discover signs of previous trauma when attempting to correlate developmental disturbances with injury to primary incisors.*

*Discoloration of the crown of the permanent tooth was evident in 16% of the children with the incisal one-third being the most common site. Hypoplasia was evident in 9% of the permanent teeth. No association could be established between the amount of primary root resorption and the appearance of mineralization defects on the permanent successors.*

**C**orrelation between trauma to the primary teeth and the presence of mineralization defects in the permanent dentition has been described previously.<sup>1-7</sup> The influence of injury to the primary incisors on their permanent successors was related to the spatial relationship of the involved teeth, the child's age at the time of trauma, and the type of injury.<sup>8</sup> Findings from a previous report<sup>9</sup> did not confirm an age relationship between the location of developmental disturbances in the permanent dentition and injury of their primary predecessors. In that study the incisal

third was the most common location of these defects in all age groups examined. This led to the hypothesis that chronologic age might not express sufficiently the developmental status of the dentition. Furthermore, since young children are prone to injuries that often are unnoticed by parents, clinical examinations and anamnestic information might have been insufficient in the previous study.

The objectives of this investigation were:

1. To assess radiographically the degree of development of the permanent incisors at the time of injury
2. To evaluate the immediate posttrauma radiographs for possible evidence of previously unnoticed injury
3. To correlate the roentgenographic and clinical findings from the time of trauma with the clinical appearance of the permanent incisors.

### Methods and Materials

The permanent incisors of 124 children whose primary predecessors had been traumatized were examined clinically (findings have been reported previously<sup>9</sup>).

The files of 100 of these children with a total of 213 injured teeth were available and immediate posttrauma periapical radiographs were examined. The following parameters were recorded from these radiographs:

1. Degree of development of the permanent central and lateral incisors according to Nolla<sup>10</sup> (Table 1)
2. Degree of root development and physiologic resorption of the primary incisors

**TABLE 1.** Stages of Dental Development According to Nolla<sup>10</sup>

Stage 0	Absence of crypt
Stage 1	Presence of crypt
Stage 2	Initial calcification
Stage 3	One-third of crown completed
Stage 4	Two-thirds of crown completed
Stage 5	Crown almost completed
Stage 6	Crown completed
Stage 7	One-third of root completed
Stage 8	Two-thirds of root completed
Stage 9	Root almost completed — open apex
Stage 10	Apical end of root completed

3. Presence of periapical radiolucencies, pathologic root resorption and pulpal pathologic changes — arrest of dentin formation, pulp obliteration, or diffuse intracanal calcifications. (The presence of any of the aforementioned signs were considered as possible indications of unreported or unnoticed previous trauma. Radiographs of teeth presenting with deep caries were excluded, since complications of caries also could lead to mineralization disturbances, thus leaving a “refined” group.)

A clear distinction was made between the total sample (100 children) and a refined group that included 36 children (19 males, 17 females) with 76 injured primary incisors. The mean age at the time of trauma was 3.5 years. In this refined group no evidence of previous trauma or deep caries could be disclosed from the radiographic assessment.

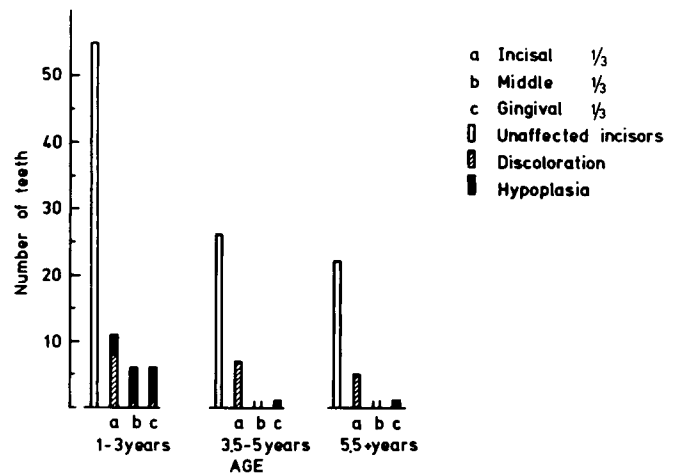
An attempt was made to correlate the presence and location of mineralization defects in the permanent incisors of the refined group with:

1. The child’s chronologic age at the time of trauma
2. The stage of development of the permanent incisor at the time of trauma
3. The stage of root resorption of the primary incisor at the time of trauma
4. The type of trauma.

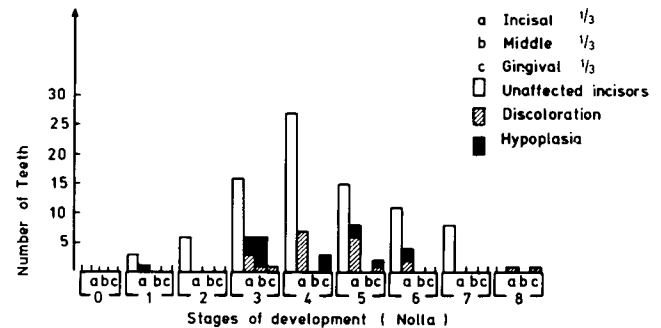
Further, the present results were compared to those obtained in the previous report.<sup>9</sup>

## Results

The appearance and location of mineralization defects of the permanent incisors of the refined group are presented in Figures 1 and 2. Some of the teeth were affected by both discoloration and hypoplasia and therefore are included in both groups. It appears that the frequency of these defects decreases with increasing age at the time of trauma. (Fig 1). Discoloration appeared on 24 teeth (16%) and affected all age groups and Stages 3-6 as described by Nolla.<sup>10</sup>



**FIG 1.** Distribution of mineralization defects according to age groups and location (some of the teeth were affected by both hypoplasia and discoloration and are presented in both groups).



**FIG 2.** Distribution of the location of mineralization defects according to tooth development stages — after Nolla (some of the teeth were affected by both hypoplasia and discoloration and are presented in both groups).

The incisal third was the most common location of discoloration (Figs 1, 2). Hypoplasia observed in 13 teeth (9%) occurred only in the younger age group 1-3 years of age and in Stages 1-5. The location of the hypoplastic defects moved cervically with increasing crown development.

The vast majority (80%) of the primary teeth of the refined group revealed no root resorption, since they probably belonged to the young age group at the time of trauma. The remaining 20% of primary incisors presented with various degrees of root resorption. The same percentage of mineralization defects (25%) appeared in the permanent successors of traumatized primary teeth with and without root resorption.

The most common type of injury sustained by children in this study and the distribution of mineralization defects in their permanent incisors are presented in Table 2. Luxation was the most common

**TABLE 2.** Mineralization Defects as Related to the Most Common Types of Injury to the Primary Incisors

Type of Trauma	No. of Teeth	Teeth Without Defects	Teeth With Discoloration Only	Teeth With Hypoplasia Only	Teeth With Discoloration and Hypoplasia	Total number of Affected Teeth
Luxation	23 (100%)	11 (50%)	5 (20%)	3 (13%)	4 (17%)	12 (50%)
Palatal/displacement	21 (100%)	17 (80%)	4 (20%)	0	0	4 (20%)
Intrusion	7 (100%)	4 (57%)	2 (28%)	0	1 (15%)	3 (43%)
Nontrauma*	62 (100%)	54 (87%)	1	2	5 (5%)	8 (13%)

\* Teeth in proximity to the injured tooth.

type of injury, followed by palatal displacement. Fifty per cent of permanent successors to luxated primary incisors appeared with mineralization defects, while only 20% were affected similarly in case of palatal displacement. Thirteen per cent of the teeth adjacent to the traumatized incisors (nontrauma) were followed by developmentally affected permanent incisors.

## Discussion

In a previous report, no direct correlation was found between the child's age at the time of trauma and the location of mineralization defects in the permanent successors.<sup>9</sup> That study included only children without clinical signs of traumatic injuries to their primary teeth, such as cracked, fractured, or discolored teeth, and premature loss of primary incisors. In addition, parents were asked about possible previous injuries to the primary teeth. Despite the care taken in selection of the study sample, several findings led to the suspicion that some unreported and unnoticed previous trauma might have been included in the sample. It should be stressed that parents tend to forget or to overlook history of minor injuries sustained years before.<sup>4</sup> Considering that young children are prone to trauma and some may have sustained injury without objective clinical signs, a detailed analysis of radiographs taken at the time of trauma was found to be indicated.

Careful examination of those radiographs revealed that 64% of the teeth in the previously reported sample<sup>9</sup> showed either some degree of pathological root resorption, a periapical lesion, or pulpal changes. These findings were interpreted as consequences of previous trauma or as sequelae to deep caries.

Analysis of the refined group revealed that about 25% of the permanent teeth examined showed mineralization defects. This figure is lower than most others reported in the literature (as summarized by Andreasen<sup>7</sup>). This may be due to a difference in sample selection.

Discoloration appeared in all age groups and in

different stages of crown mineralization, ranging from one-third crown formation to crown completion. This finding agrees with Andreasen and Ravn,<sup>3</sup> who explain these findings as being a manifestation of disturbed "secondary" mineralization. Deutsch et al.<sup>11,12</sup> have shown that some secondary mineralization (maturing) of enamel takes place even when the crown is full size and root formation has begun.

As in the previous study, mainly the incisal edge was affected by discoloration in all age groups.<sup>9</sup> This may be due to the proximity of the developing crown to the primary roots.<sup>7,8</sup>

Hypoplasia was present in 9% of the teeth and affected only the young age group. This confirmed the expected results, since hypoplasia is a manifestation of trauma sustained during the formation stages of the permanent tooth germ. Thus, a tooth that appeared radiographically to be in an early stage of development would present with a hypoplastic lesion located more incisally than a tooth in a more advanced stage of crown development. However, radiographic evaluation is not precise, and areas that are not mineralized entirely would not be evident in a radiograph. This fact might explain the appearance of mineralization defects in locations that do not correlate with the stage of crown development, as shown in Fig 2.

No association was established between the amount of the resorption of primary root and the appearance of mineralization defects on the permanent successors, confirming previous findings.<sup>2</sup> This finding also agrees with the histologic presentation of Andreasen<sup>7</sup> and the roentgenographic findings suggested by Smith and Rapp.<sup>8</sup> The latter indicated that the distance between the resorbing primary root and the developing permanent successor does not change significantly between ages 3 and 6.

Correlation between the different types of trauma and the appearance and type of mineralization defects in the permanent successors was not conclusive due to the small refined sample. An exception to this was the group called "nontrauma" (adjacent to the traumatized incisors), in which a larger number of

teeth was included. Thirteen per cent of these teeth were followed by developmentally affected permanent incisors, a lower figure than the 25% reported previously.<sup>9</sup> This reduction probably is due to sample refinement.

## Conclusion

Careful radiographic examination to discover signs of previous trauma is of utmost importance when attempting to correlate trauma to the primary incisors and the appearance of mineralization defects in their permanent successors.

The incisal edge of the permanent incisor was the most common location for discoloration in all age groups and developmental stages. Hypoplasia of the permanent tooth crown appeared only in the young age groups and in the early developmental stages and moved cervically with advanced tooth development.

This study was supported in part by a grant from the Joint Research Fund of the Hebrew University-Hadassah School of Dental Medicine founded by the Alpha Omega Fraternity and the Hadassah Medical Organization.

The authors thank Dr. Y. Lustman for allowing access to the post-trauma records and to Mr. I. Einot for his help in planning and analyzing the statistical data.

Dr. Ben Bassat is an instructor, orthodontics; Dr. Brin is a lecturer, orthodontics; Dr. Fuks is senior lecturer, pedodontics; and Dr. Zilberman is senior lecturer, orthodontics, The Hebrew University-Hadassah Faculty of Dental Medicine, P.O.B. 1172, Jerusalem, Israel. Reprint requests should be sent to Dr. Ben Bassat.

1. Ravn JJ: Sequellae of acute mechanical trauma in the primary dentition. *J Dent Child* 35:281-89, 1968.
2. Andreasen JO, Sundström B, Ravn JJ: The effect of traumatic injuries to primary teeth on their permanent successors. I. A clinical and histologic study of 117 injured permanent teeth. *Scand J Dent Res* 79:219-83, 1971.
3. Andreasen JO, Ravn JJ: The effect of traumatic injuries to primary teeth on their permanent successors. II. A clinical and radiographic follow-up study of 213 teeth. *Scand J Dent Res* 79:284-94, 1971.
4. Andreasen JO, Ravn JJ: Enamel changes in permanent teeth after trauma to their primary predecessors. *Scand J Dent Res* 81:203-9, 1973.
5. Ravn JJ: Developmental disturbances in permanent teeth after intrusion of their primary predecessors. *Scand J Dent Res* 84:137-141, 1976.
6. Zadik D, Fuks A, Eidelman E, Chosack A: Traumatized teeth: two-year results. *J Pedod* 2:116-23, 1980.
7. Andreasen JO: Traumatic injuries of the teeth, 2nd Ed. Copenhagen; Munksgaard, 1981 Ch 9.
8. Smith RJ, Rapp R: A cephalometric study of the developmental relationship between primary and permanent maxillary central incisor teeth. *J Dent Child* 47:36-41, 1980.
9. Brin I, Ben Bassat Y, Fuks A, Zilberman Y: Trauma to the primary incisors and its effect on the permanent successors. *Pediatr Dent* 6:78-82, 1984.
10. Nolla CM: The development of the permanent teeth. *J Dent Child* 27:254-66, 1960.
11. Deutsch D, Tam O, Stack MV: Postnatal changes in size, morphology, and weight of developing postnatal deciduous anterior teeth, in Proceedings of Sixth International Symposium of Dental Morphology. Reykjavik, Iceland; In Press 1983.
12. Deutsch D, Shapira L, Allayof A, Leviel D, Yoeli Z, Arad A: Protein and mineral changes during prenatal and postnatal development and mineralization of human deciduous enamel, in Fourth International Symposium on Tooth Enamel. Odawara, Japan; In Press 1984.

---

## Back Issue Requests

Effective immediately, notification of nonreceipt of *Pediatric Dentistry* must be received by the editorial office within 30 days of the first day of the month of issue (by January 1 for the December issue, etc.). Issues requested after this time will be sent only after receipt of the normal \$14 charge for back issues (\$18 for foreign mailings). Foreign subscribers will have up to 90 days to notify the editorial office of nonreceipt. This policy applies to institutional as well as individual subscriptions.