

Acquired toxoplasmosis of a submandibular lymph node in a 13-year-old boy: case report

Badri Azaz, DMD Isaac Milhem, DMD Oscar Hasson, DMD Gina Kirsch, DMD

Abstract

Toxoplasmosis is a parasitic infection divided into congenital and acquired forms. In the latter form, malaise, fatigue, and lymphadenopathy are commonly found, and submandibular lymphadenopathy is sometimes a manifestation. In children, cervical lymph nodes usually are affected. This is a case of a 13-year-old boy suffering from acquired toxoplasmosis, in which submandibular lymphadenopathy was the only clinical sign of the disease. Meticulous history taking, clinical examination, and specific serological tests should be performed in these cases. Positive serological results will confirm toxoplasmosis infections. Conservative treatment must be attempted initially. (Pediatr Dent 16:378–80, 1994)

Introduction

Toxoplasmosis is a parasitic infection caused by the obligate parasite, *Toxoplasma gondii*, which was first found in a North African rodent called *gondii*¹ and later found to be widely distributed throughout the world. There are two clinical manifestations of toxoplasmosis: the congenital and the acquired forms.^{2,3} The congenital form is characterized by hydrocephalus, chorioretinitis, convulsions, and intracerebral calcifications in the newborn. When the infection occurs late in pregnancy, only mild signs or symptoms may be seen at birth. In such cases, more aggressive complications such as central nervous system seizures or retinochoroiditis will be observed later in life.

The acquired form is further subdivided into the disseminated and the lymphadenopathic types, the latter being the more common form of the disease in men. Acquired toxoplasmosis may be present at any age, but peak incidence is in the second and third decades.⁴ Beverley showed in his study that 30% of the toxoplasmic lymphadenopathy cases were children and young adolescents.⁴ It has been estimated that 15% of unexplained lymphadenopathy is due to toxoplasmosis,⁵ usually affecting the cervical lymph nodes.

This is the case of 13-year-old boy suffering from toxoplasmosis manifested clinically by a submandibular lymphadenopathy.

Case report

A 13-year-old boy was referred to the Department of Oral and Maxillofacial Surgery at the Hadassah Hebrew

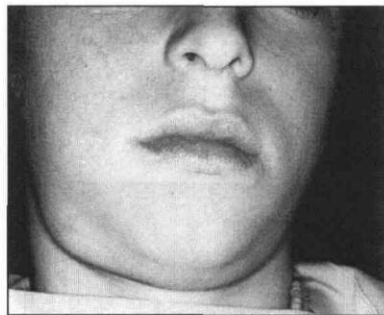


Fig 1. Right submandibular triangle swelling.

University Hospital, complaining of a right submandibular swelling that had appeared two months earlier. The swelling showed no change during this whole period, and the patient had no other symptoms.

Clinical examination revealed a freely mobile firm mass, measuring 2x2 cm in the right submandibular triangle (Fig 1). Intraoral examination showed normal salivary flow from the right Wharton's duct and no signs of acute infection or pathology.

Radiographic examination including a sialogram yielded no pathological findings. A bone scan of salivary glands revealed a decreased absorption of technetium in the right submandibular gland. The chest radiograph was normal. Routine blood tests showed: HB 13.3 g/dl, RBC 5.31×10^{12} , WBC 4.5×10^9 , differential count — neutrophils 62%, eosinophils 1%, lymphocytes 31%, monocytes 5%. The serological tests for Epstein-Barr virus (EBV) and cytomegalovirus (CMV) showed possible ancient contact with these viruses (EBV: IgG = 128 and CMV: IgG = 64) but not new contact (EBV: IgM = 0; CMV: IgM = 0). The Mantoux test for tuberculosis was negative.

Two months later, after no significant change, the patient was admitted for a biopsy with a differential diagnosis of reactive lymph node (cat-scratch disease), mixed tumor, or lymphoma. An enlarged lymph node was excised under general anesthesia by extraoral approach from the right submandibular region. The most distinctive histological features seen on microscopic examination were:

1. A well-preserved lymph node architecture
2. Follicular hyperplasia with active germinal centers containing numerous mitoses and necrotic debris
3. Clusters of pale-staining epithelioid histiocytes scattered haphazardly in cortical and paracortical areas and encroaching the follicular margins in a very characteristic manner (also within the germinal centers)

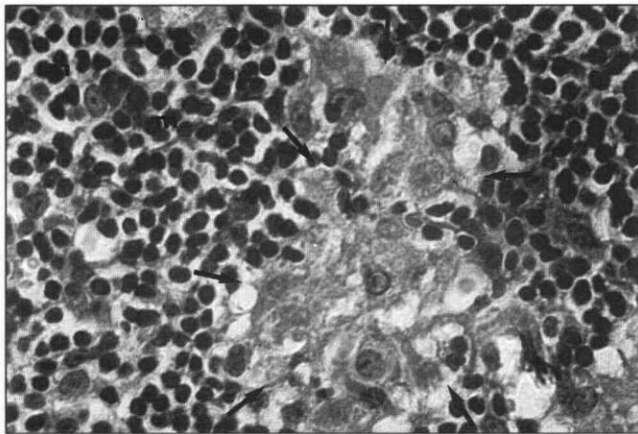


Fig 2. Detail of epithelioid histiocyte (H&E 640x) within arrows and monocytoïd cells (m).

4. Vesicular nuclei and abundant eosinophilic cytoplasm could be discerned under high power (Fig 2)
5. Focal distention of the subcapsular and trabecular sinuses by monocytoïd cells (cells resembling blood monocytes, Fig 2)
6. Medullary cords containing numerous plasma cells and large mononuclear antigenically stimulated cells (called immunoblasts).

Subsequently, the indirect fluorescent antibody (IFA) test was performed to detect antibody to *T. gondii*, which revealed an elevated IgG titre 1:2015 (normal IgG:0-15) and an IgM titre of 1:18 (normal IgM = 0). The postoperative course was uneventful and the patient was discharged 5 days later.

Discussion

Lymphadenopathy, a common sign in the head and neck region, may be related to several different pathological entities.

Several diseases may cause localized or generalized lymphadenopathy such as localized infections, infectious mononucleosis, cytomegalovirus, cat-scratch disease, sarcoidosis, toxoplasmosis, non-Hodgkin's and Hodgkin's lymphoma, metastatic malignant disease, tuberculosis, tularemia, brucellosis, dermatopathic adenitis, and rubella.

T. gondii exists in three forms.^{3,6,7} The tachyzoites form is seen in the acute stage of infection, but is destroyed by freezing and thawing and by digestive juices. The tissue cyst form usually is associated with chronic toxoplasmosis and transmission of the disease and is caused by ingesting uncooked meat containing the tissue cyst form. Once in the gastrointestinal system, the action of local enzymes ruptures the cysts, liberating the viable organism and infecting the immunocompromised host. Freezing and thawing, and heating to 60°C may destroy the cyst form. The oocyst form — usually found in cat litter — is the most resis-

tant to the external environment, though it plays an important role in disease transmission. The oocyst is destroyed by boiling or dry heat over 66°C. If toxoplasmosis is suspected, possible contact with litter of infected cats and ingesting uncooked meat — especially that of cattle, sheep, and pigs — must be examined.

Lymphadenopathy is a typical and sometimes a unique⁸ sign of the acquired toxoplasmosis: usually of soft consistency, mobile, and sometimes painful. Cervical adenopathy usually is encountered in the posterior cervical region (82%), followed by axillary (35%), inguinal (19%), and anterior chest wall (8%).⁹ The submandibular lymph nodes are rarely involved (0.45%).¹⁰ In children, the cervical lymph nodes are most commonly affected.

Palpable lymph nodes are a common sign of lymphadenopathy in children. Herzog¹¹ showed that in infants, cervical and submandibular palpable lymph nodes are seen in 11 and 0.2% of cases, respectively, and in children aged 1 to 5 years, 42 and 21% of cases, respectively. In the aggressive form of acquired toxoplasmosis, diffuse lymphadenopathy, macular eruption, loss of taste, granulomatous stomatitis, and glossitis may be observed.³

Laboratory blood examinations show a slight monocytosis as well as lymphocytosis; alteration in liver function may be seen, especially in the first week of the disease. The serological examinations are of substantial help. The Sabin-Feldman dye test is one of the most specific tests with unknown false positives in human. When positive, this test confirms a previous infection. Some tests may reveal a recent infection — the most accurate is the IGM-ELISA (enzyme-linked immunosorbent assay), positive in 97% of recently acquired toxoplasmosis.⁷

Until the introduction of the immunohistochemical examination, excisional biopsy and histological examination usually were performed, which may explain the fewer solitary lymphadenopathy-acquired toxoplasmosis regressions reported in the literature. In our view, if no malignant lymphadenopathy is suspected, all the laboratory tests must be completed before performing surgery.

Despite its typical histological picture, toxoplasmosis is definitively diagnosed after obtaining results from serological tests. Uncommonly a cyst or pseudocyst containing toxoplasma may be present and will thus be another helpful diagnostic aid.

The microscopic picture is extremely important in differentiating this lesion from a more serious malignant lymphoma, like Hodgkin's lymphoma. First, in toxoplasmosis the lymph node architecture is maintained. Second, the proliferative cells show normal mitoses and only among them does any significant necrosis appear. Third, no giant cells of Hodgkin's disease are observed. Finally, the cellular infiltration is

seen to involve the capsule and extend out of the node as is characteristic of inflammatory conditions.

Serological examinations are most trustworthy in confirming recent or old toxoplasmosis infection. When positive results are present in suspected acquired toxoplasmosis, conservative management should be the treatment of choice. Patients suffering from lymphadenopathy in the head and neck regions, without any other systemic manifestation, should be followed up with no complementary drug therapy. Lymphadenectomy must be considered in cases of growing lymph nodes. In more severe cases, pyrimethamine and sulfadiazine are the treatment of choice.

Because of its possible relationship to 15% of unexplained lymphadenopathies, toxoplasmosis should be considered in the differential diagnosis of any head and neck lymphadenopathy.

Professor Azaz is head; and Dr. Milhem and Dr. Hasson are residents in the department of oral & maxillofacial surgery; Dr. Kirsch is resident, department of oral pathology; Hebrew University, Hadassah School of Dental Medicine, founded by the Alpha Omega Fraternity, Jerusalem, Israel.

1. Nicolle C, Manceaux L: Sur une infection a corps de Leishman (ou organismes voisins) du gondi. *Compt Rend Acad D Science* 147:763-66, 1908.
2. Newman L: Cervical lymphadenopathy associated with toxoplasmosis. *Br Dent J* 156:15-6, 1984.
3. Appel BN, Mendelow H, Pasqual HN: Acquired toxoplasma lymphadenitis. *Oral Surg Oral Med Oral Pathol* 47:529-32, 1979.
4. Beverley JKA, Toxoplasmosis. *Br Med J* 2:475-78, 1973.
5. Toxoplasmosis, World Health Organization Technical Report Series No. 431. 1969, pp 5-31.
6. Ishikawa T, Nishino H, Ohara M, Shimamoto T, Nanba K: The identification of a rabbit-transmitted cervical toxoplasmosis mimicking malignant lymphoma. *Am J Clin Pathol* 94:107-10, 1990.
7. VonArx DP: Cervicofacial toxoplasmosis. *Br J Oral Maxillofac Surg* 26:70-77, 1988.
8. Sumi Y, Kaneda T, Nagasaka T: Toxoplasmosis of the preauricular and cervical lymph nodes. *J Oral Maxillofac Surg* 45:978-79, 1987.
9. Rafaty FM: Cervical adenopathy secondary to toxoplasmosis. *Arch Otolaryngol* 103:547-49, 1977.
10. Gray GF Jr, Kimball AC, Kean BH: The posterior cervical lymph node in toxoplasmosis. *Am J Pathol* 69:349-56, 1972.
11. Herzog LW: Prevalence of lymphadenopathy of the head and neck in infants and children. *Clin Pediatr* 22:485-87, 1983.

In-line skating injuries tracked

More than 30,000 people suffered injuries in one year

More than 30,000 in-line skaters suffered injuries during one year, according to a study in a recent *Journal of the American Medical Association*. Nevertheless, in-line skaters suffered fewer injuries than rollerskaters or skateboarders.

"For every in-line skating injury, approximately 3.3 rollerskating and 1.2 skateboarding injuries occurred," writes Richard A. Schieber, MD, from the National Center for Injury Prevention and Control, Centers for Disease Control and Prevention, Atlanta, with colleagues.

The authors looked at all persons treated for product-related injuries involving in-line skates, rollerskates, or skateboards between July 1, 1992, and June 30, 1993. They say that in-line skating "is currently the fastest growing recreational sport in the United States." Experienced skaters commonly reach cruising speeds of 10 to 17 mph, and there have been anecdotal reports of speeds more than 45 mph.

The authors based their study on data from the National Electronic Injury Surveillance System. There were approximately 30,863 in-line skaters aged 5 to 71 years injured during the study period, they found. About 92,963 rollerskaters and about 34,938 skateboarders suffered injuries.

While the current study did not determine rates of injury, the authors cite a 1992 survey that found there were 22.6 million rollerskaters who skated an average of 14.7 days per person per year; there were 6.5 million skateboarders who skateboarded 36.7 days per person per year; and there were 9.4 million in-line skaters who averaged 22.5 days of in-line skating per person per year.

Average age for injured in-line skaters was 19.7 years; for rollerskaters it was 16.6 years; for skateboarders it was 13.6 years. Male-to-female ratio of injured was 1.3:1 for in-line skates, 0.4:1 for rollerskates, and 4.6:1 for skateboards.

"The wrist area, including the wrist and lower arm, was the most common site of injury for all three sports and was the principal anatomic site of injury for 38% of all injuries among in-line skaters, 46% among rollerskaters, and 20% among skateboarders," they write. "Injuries were classified as 'more severe' in 52% of the injured in-line skaters, 46% of the injured rollerskaters, and 36% of the injured skateboarders."

"Because wrist fractures were the most common type of injury in all three sports, wrist protection is needed," they say. "Head protection by helmets is recommended."