



Novel Dental Anomalies Associated With Congenital Contractural Arachnodactyly: A Case Report

Kathryn Marina Sherwood Ayers, BDS, MDS Bernadette Kathleen Drummond, BDS, MS, PhD

Dr. Ayers and Dr. Drummond are pediatric dentists and senior lecturers, Department of Oral Sciences, Faculty of Dentistry, University of Otago, Dunedin, New Zealand.

Correspond with Dr. Ayers at katie.ayers@stonebow.otago.ac.nz

Abstract

Congenital contractural arachnodactyly (CCA) is an inherited disorder of connective tissue similar to Marfan's syndrome. The craniofacial and oral features of a young girl with CCA are described. The patient has the typical features of CCA as well as some additional dental anomalies which have not previously been reported with this syndrome. These include banded pitted enamel hypoplasia and hypomineralization, long, spindly tapered roots, and pulp canal obliteration with multiple pulp stones. Dentists must be aware of the clinical features of a patient's syndrome to determine whether there are implications for dental treatment such as a need for antibiotic prophylaxis. It is important to exclude Marfan's syndrome as a differential diagnosis for CCA because the former has more associated complications and a less favorable prognosis. (*Pediatr Dent.* 2003; 25:501-504)

KEYWORDS: DENTAL ANOMALIES, CONGENITAL CONTRACTURAL ARACHNODACTYLY, BEALS' SYNDROME, MARFAN'S SYNDROME

Received July 23, 2002 Revision Accepted March 1, 2003

Congenital contractural arachnodactyly (CCA) or Beals' syndrome is an autosomal dominant condition phenotypically related to Marfan's syndrome (MS). CCA was first described as a distinct syndrome in 1971.¹ However, it is thought that the first case described by Marfan in 1896 probably represented a case of CCA rather than Marfan's syndrome as it is now recognized.² CCA is an inherited disorder of connective tissue characterized by multiple joint contractures, arachnodactyly (extreme length and slenderness of fingers and toes), dolichostenomelia (long, thin limbs), scoliosis, and a characteristic abnormality of the external ears.¹ Underdevelopment of the calf muscles is a common feature.^{3,4} Mental retardation does not appear to be a feature of the syndrome.^{3,5} Although the disorder is usually inherited by autosomal dominant transmission, many cases are sporadic, and there appears to be considerable variation in the penetrance and expressivity of the mutant gene.⁶

A child with CAA is usually the result of a normal pregnancy but often with a breech delivery. Early growth and development are normal, but motor development may be delayed due to joint contractures present at birth, with the knees most affected.^{1,5} Individuals tend to be tall and spinal abnormalities such as kyphosis, scoliosis, or kyphoscoliosis

occur in about 50% of cases, particularly in those more severely affected with CCA.⁴ Congenital heart lesions including mitral valve prolapse, structural anomalies, and aortic root dilacerations may exist in association with CCA.² Ocular abnormalities, including myopia, keratocornus, and ectopia lentis, have been reported.^{7,8} However, patients with CCA do not usually have long-term medical problems and life expectancy is normal.³

Previously reported craniofacial features include:

1. oval-shaped skull with frontal prominence;
2. deep-set eyes with slight ptosis and a mild degree of hypertelorism;
3. small nose, upturned at the tip with a flattened nasal bridge;
4. elongated philtrum;
5. microstomia and retrognathic mandible with limitation of mandibular excursions;
6. "crumpled" ears—normal position but abnormal structure with extraprominent crura in the antihelix, partially obliterating the concha allowing helix flattening;
7. short neck;
8. high-arched palate and widely spaced anterior maxillary teeth.^{1,3,9}

Table 1. Comparison of the Characteristic Traits of Congenital Contractural Arachnodactyly and Marfan's Syndrome

Trait	CCA	Marfan's syndrome
Arachnodactyly	Yes	Yes
Joint hyperextensibility	Some	Yes
Spinal abnormalities	Yes	Yes
Muscle hypotonia	Yes	Yes
Crumpled ears	Yes	Rarely
Cardiovascular defects	Rarely	Commonly (60%-90%)
Ocular abnormalities	Occasionally	Usually (60%-80%)
Intelligence	Usually normal	Normal
High arched palate	Yes	Yes (50%)
Cleft palate	Yes	Yes
Prognathism	Rarely	Sometimes
Micrognathia	Often	Rarely
Spindly roots	No	Yes
Anterior open bite	Yes	Yes
Dental occlusion	Spacing	Crowding
TMJ disorders	No	Yes

The clinical and radiographic intraoral features described include maxillary diastema, bilateral ectopic eruption of maxillary first permanent molars, micrognathia, and anterior open bite¹⁰. Several reports have noted high-arched palates and central palatal clefts.^{3,7,9,11} Midline natal teeth have been reported as have irregularly spaced teeth.^{7,8}

CCA results from mutations in the FBN2 gene mapped to 5q23-q31. This encodes fibrillin-2, a protein whose domain structure and length are very similar to fibrillin-1, the protein altered in MS and encoded by FBN1 located on chromosome 15. The types of FBN2 mutations in patients with CCA are similar to the FBN1 mutations identified in MS patients, suggesting a similar pathogenesis for the 2 conditions. It is suggested that the rarity of CCA in comparison with MS is because of the occurrence of the mutations in only a limited region of the FBN2 gene.²

The differential diagnosis of CCA includes: Marfan's syndrome, homocystinuria, arthrogyrosis, Achard's syndrome, osteogenesis imperfecta, and Stickler's syndrome. The most important differential diagnosis to be excluded is Marfan's syndrome. The conditions overlap in symptomatology and morphology but differ dramatically in prognosis (Table 1). Both have an autosomal dominant inheritance pattern with variable expression. The features include tall, slender body, frequent kyphoscoliosis, and normal intelligence. Arachnodactyly and dolichostenomelia are usually more frequent and severe in Marfan's syndrome, and hyperextensibility of joints is more usual. Ocular defects and cardiovascular abnormalities are also common.

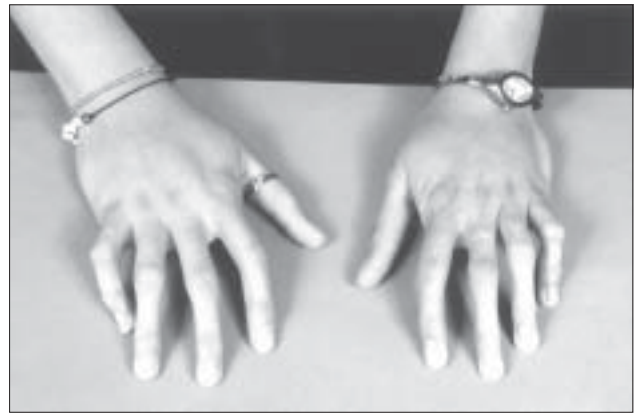

Figure 1. Photograph of the patient's hands showing fixed flexion deformity of the fingers.

High-arched palates have been reported in both syndromes, while prognathism is more common in Marfan's syndrome and micrognathia is often present in CCA.^{1,4-7,10}

The purpose of the following case report is to describe a case of CCA with some novel dental anomalies.

Case report

A 14-year-old girl was referred to the University of Otago Pediatric Dentistry Clinic in 1998 from a school dental clinic because of anxiety and a

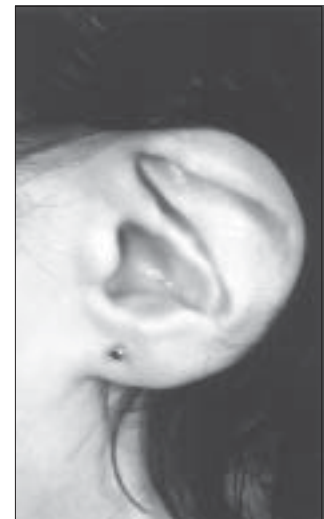


Figure 2. Close-up view of the ears with characteristic "crumpled" appearance.

history of repeated dental abscesses necessitating several tooth extractions. There was a history of early childhood caries with prolonged use of a feeding bottle containing fruit juice. B, D, E, F, G, and H had been extracted early because of abscesses and root resorption. The medical history revealed a diagnosis of Beals' syndrome (congenital contractural arachnodactyly). The patient was the first child born to nonconsanguineous parents with no family history of CCA. She was delivered by elective cesarean section at 37 weeks because of a small maternal pelvis, intrauterine growth retardation, and breech presentation. Her birth weight was 2.2 kg and her head circumference was 31.3 cm. She had a fixed flexion deformity of the fingers, was unable to fully abduct hips, had bilateral talipes, and squashed looking toes. A small jaw with flat squashed ears and narrow face were also noted. Craniofacial features included "crumpled" appearance of the ears, a broad prominent forehead, relatively flat occiput, downslanting palpebral fissures, downturned angles of the mouth, and a

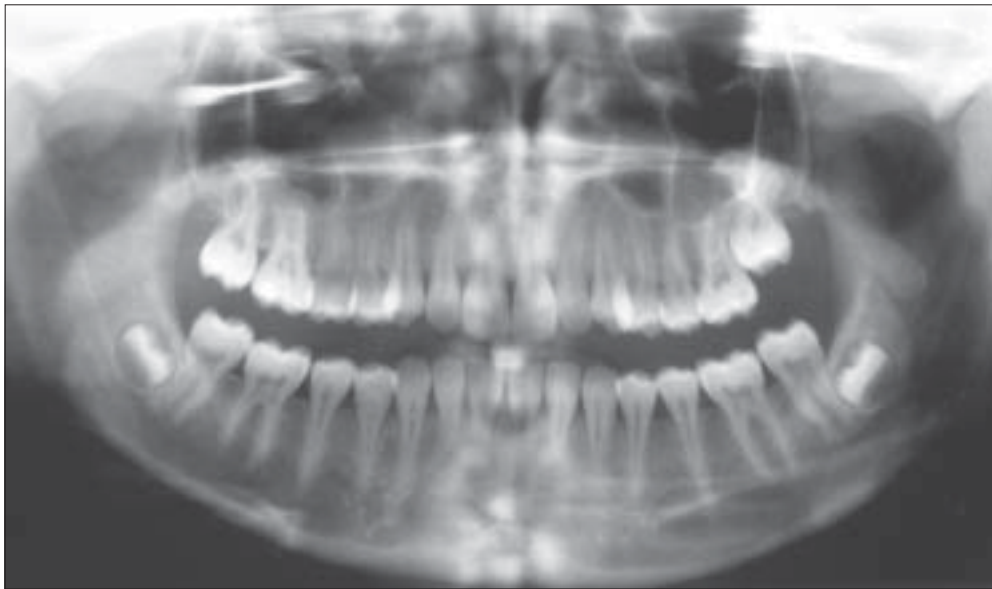


Figure 3. Orthopantomogram; note the long spindly tapered roots, pulp stones, and absent maxillary third molars.

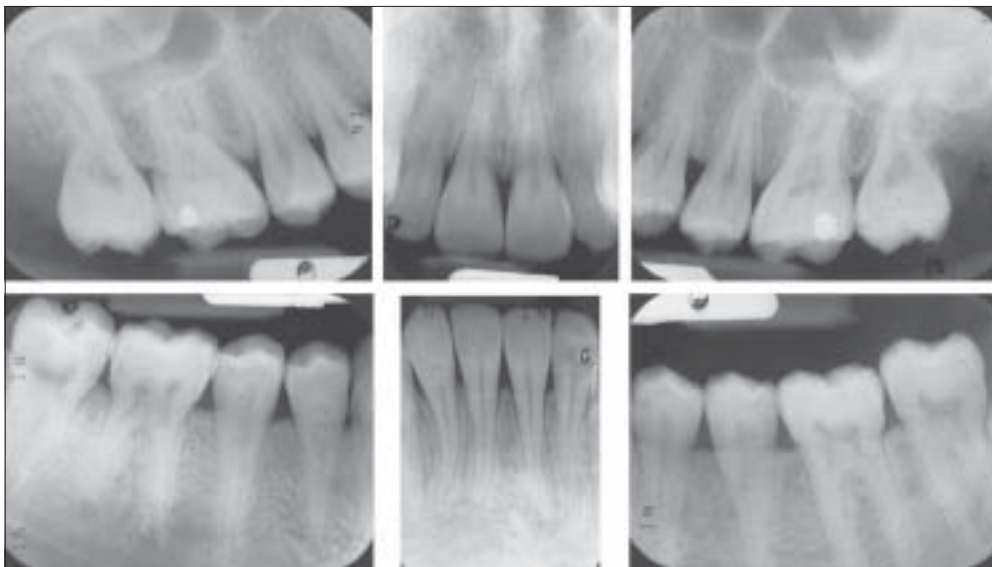


Figure 4. Selected periapical radiographs. Again note the long spindly roots and abnormal pulp morphology.

short neck. Motor development was slightly delayed, but growth followed the 50th percentile for height and weight. Joint contractures improved over time, and the child could walk, skip, run, and jump by 8 years of age.

This patient had the phenotypic appearance of CCA, as evidenced by slender limbs; arachnodactyly; contractures at the fingers (Figure 1), elbows, and knees; ligamentous laxity; accentuated lumbar lordosis; and mild scoliosis. Radiographs demonstrated some rotation of the thoracic spine with loss of normal kyphosis in the lower part of the thoracic spine. The degree of scoliosis increased in adolescence. A full cardiology examination was performed in 1993 with no abnormal findings. The patient had a myopic astigmatism, but no evidence of Marfan's syndrome on eye examination. She had eczema and mild asthma, for

which terbutaline sulphate and Budesonide inhalers were prescribed. Genetic evaluation concluded that this case of CCA is due to a new mutation with a 50/50 probability of transmission to any offspring.

On presentation, the patient exhibited a short neck, crumpled ears (Figure 2), increased facial hair, deep-set eyes, tapering frontal profile, and concave lateral profile with a Class I skeletal base but a retruded midface. There was facial asymmetry with a flattened nasal bridge, and short upper lip with competent lips. Speech and swallowing were normal and no temporomandibular abnormalities were evident. The intraoral soft tissues were healthy with the exception of some areas of marginal gingival inflammation associated with plaque retention. The arches were U-shaped with normal palatal height. There was a cross bite of 3 and 29, 50% over bite, 1.5 mm overjet and a lower midline deviation of 2 mm to the right. The teeth were well spaced. The upper anterior teeth and canines exhibited banded pitted

enamel hypoplasia and hypomineralization. Some pit and fissure sealants were present, and there was occlusal caries involving 14.

The radiographs demonstrated long, spindly tapered roots with increased curvature and abnormal pulps. Many teeth had thistle tube-shaped pulpal chambers with significant pulpal obliteration, and pulp stones were evident in several teeth. It is unusual to see such pulpal findings in an adolescent. The maxillary third molars were absent (Figures 3 and 4).

Discussion

The patient exhibited many of the orofacial features of CCA previously reported in the literature. However, there were a number of other unusual features which have not

been previously reported. These include the pattern of bands of enamel pitting hypoplasia and hypomineralization of the teeth, the presence of numerous pulp stones, and the unusual root development of the permanent teeth. No other cause for the enamel hypoplasia could be detected, including any suggestion of a fluoride effect after assessment of the history of fluoride use. It may be that enamel hypoplasia is a feature of the syndrome, given its connective tissue etiology.

A higher prevalence of enamel structural defects was recently reported in individuals with Marfan's syndrome compared to controls.⁹ Similarly, long, narrow teeth have been described in Marfan's syndrome but not in CCA. The finding that the fibrillin gene is altered also suggests that there could be alteration in the periodontal ligament. No signs of excess tooth mobility were detected in this case. The pulp changes apparent in this case have not previously been reported in CCA, but pulp inclusions and abnormalities in pulp shape were recently reported to be more common in individuals with Marfan's syndrome compared to a control group.⁹ Further investigation is required to determine whether such dental abnormalities are a feature of CCA.

This case demonstrates the importance of documenting orofacial signs to determine if they match those of the diagnosed syndrome, particularly where there may be some doubt. In this case, the patient does not exhibit the orofacial features of Marfan's syndrome (crowded dentition, extreme maxillary overjet, and open bite),¹² but does exhibit previously reported features of CCA. In addition, other features have been identified which can be reported to the clinical geneticists and, if noted in other cases, may be of use in further determining the molecular effects of the mutation that causes this syndrome.

It is important to consider the possibility of cardiac disease in patients with CCA. Abnormalities such as mitral valve prolapse, structural anomalies, and aortic root dilacerations have been reported in about one third of cases.² There may be implications for the provision of dental care due to the increased risk of bacterial infective endocarditis.

Despite marked skeletal problems, this girl's dental care needs have been routine to date. As required for all patients presenting with CCA, her cardiac status was assessed to determine the risk of infective endocarditis with dental treatment. The worsening of the scoliosis may require adapting physical support for dental care in the future. For some patients, oral hygiene practices may be compromised because of limitations of elbow flexion, supination and pronation, and long narrow fingers with flexure contractures of the proximal interphalangeal joints. This can be taken into account with preventive management using battery operated brushes, adapted manual toothbrushes, fluoride products, and antibacterial mouthrinses and toothpastes.

References

1. Beals RK, Hecht F. Congenital contractural arachnodactyly: a heritable disorder of connective tissue. *J Bone Joint Surg.* 1971;53:987-993.
2. Gupta PA, Putman EA, Carmical SG, et al. Ten novel FBN2 mutations in congenital contractural arachnodactyly: Delineation of the molecular pathogenesis and clinical phenotype. *Hum Mutat.* 2002;19:39-48.
3. Belleh S, Zhou G, Wang M, Der Kaloustain VM, Pagon RA, Godfrey M. Two novel fibrillin-2 mutations in congenital contractural arachnodactyly. *Am J Med Genet.* 2000;92:7-12.
4. Ramos Arroyo MA, Weaver DD, Beals RK. Congenital contractural arachnodactyly. *Clin Genet.* 1985; 27:570-581.
5. Hecht F, Beals RK. "New" syndrome of congenital contractural arachnodactyly originally described by Marfan in 1896. *Pediatrics.* 1972;49:574-579.
6. Mirise RT, Shear S. Congenital Contractural Arachnodactyly. *Arthritis Rheumatism.* 22:542-546, 1979.
7. Anderson RA, Koch S, Camerini-Otero RD. Cardiovascular findings in congenital contractural arachnodactyly: Report of an affected kindred. *Am J Med Genet.* 1984;18:265-271.
8. Bawle E, Quigg MH. Ectopia lentis and aortic root dilaceration in congenital contractural arachnodactyly. *Am J Med Genet.* 1992;42:19-21.
9. De Coster PJA, Martens LCM, De Paepe A. Oral manifestations of patients with Marfan's syndrome: A case-control study. *Oral Surg Oral Med Oral Pathol Oral Radiol Endod.* 2002;93:564-572.
10. Sanger RG, Wieman WB. The CCA syndrome (congenital contractural arachnodactyly): a new differential syndrome for Marfan's syndrome and homocystinuria. *Oral Surgery.* 1975;40:354-361.
11. Viljoen D, Ramesar R, Behari D. Beals' syndrome: clinical and molecular investigation in a kindred of Indian descent. *Clin Genet.* 1991;39:181-188.
12. Westling L, Mohlin B, Bresin A. Craniofacial manifestations in Marfan's syndrome: palatal dimensions and a comparative cephalometric analysis. *J Craniofac Genet Dev Biol.* 18:211-218, 1998.