



Management of mandibular molar ectopic eruption using primary molar hemisection: case report

Supaporn Auychai, DDS, MS Robert J Feigal, DDS, PhD Paul O. Walker, DDS, MS

Ectopic eruption is the abnormal eruption of a permanent tooth that often causes root resorption of an adjacent primary tooth. Two types of permanent first molar ectopic eruption can be distinguished.¹ In the reversible type, the molar, after resorbing the distal root surface of the second primary molar, becomes free and erupts into its normal position in the dental arch. In the irreversible type, the erupting first permanent molar becomes blocked by the second primary molar, and the permanent molar remains in this locked position until treatment is provided or premature exfoliation of the primary molar occurs.

The prevalence of ectopic eruption is reported to be between 2 and 6%,¹⁻³ most often associated with the permanent maxillary first molar and the mandibular lateral incisor.

Several etiologic factors have been suggested for ectopic eruption of first permanent molars, including inadequate arch length, lack of growth in the posterior region of the jaw, mesially inclined eruption path of first permanent molars, and abnormally large first permanent molars.^{2, 4-6} The literature also suggests that ectopic eruption is an indicator of developing inadequate arch circumference and, therefore, is likely to result in a crowded permanent dentition. Kennedy and Turley⁷ suggested that patients presenting with ectopic eruption of molars require careful management.

Ectopic eruption can be diagnosed clinically on the basis of partial or total failure to emerge.⁸ Pathologic resorption of primary teeth often is noted during routine dental radiographic evaluation.⁹ The mesial eruption of the permanent first molar may be a local eruption problem or may indicate developmental arch circumference deficiency requiring further consideration.

A 3- to 6-month observation period is indicated after early diagnosis because the molar may spontaneously self-correct and erupt into a normal position.⁵ If the molar is prevented from erupting at the end of the observation period, therapeutic intervention is neces-

sary. Bjerklin and Kurol³ stated in 1981 that if the first permanent molar has not fully emerged by age 7, it is unlikely that natural correction will take place. One goal of treatment is to move the ectopically erupting tooth away from the tooth it is resorbing to allow the tooth to erupt into its normal position, maintaining a normal arch circumference. A secondary goal, if optimal position is not attained, is to allow molar eruption in the best available vertical position with the least loss of arch circumference. Although much has been written about ectopic eruption of the maxillary first permanent molar, few reports mention ectopic mandibular first molars. Young¹ reported that only three of 78 ectopic eruptions diagnosed among 1619 schoolchildren were mandibular first molars, and Groper reported management of an unusual case involving a single, mandibular first permanent molar.¹⁰

This case report involves bilateral ectopic eruption of mandibular first permanent molars treated with primary molar hemisection.

Case report

A 7-year-old Caucasian female presented to the pediatric dental clinic for consultation. Her medical history was noncontributory and the extraoral findings were within normal limits. Parental concern was "overcrowding, needs extraction".

A clinical oral examination showed unerupted mandibular first permanent molars. Upon radiographic examination, it was found that both mandibular first permanent molars were erupting ectopically. Extensive resorption of the distal roots of mandibular second primary molars had occurred bilaterally (Figs 1 and 2). However, both unerupted maxillary first permanent molars were positioned normally.

Full orthodontic records were obtained. Cephalometric analysis revealed the patient had a skeletal class II tendency. Arch circumference deficiency was noted in both upper and lower arches, and severe crowding was anticipated in the transitional dentition.

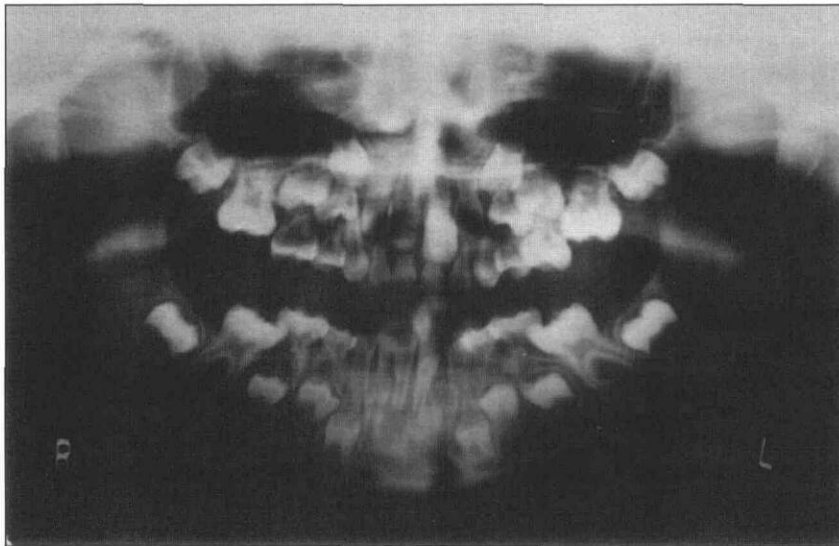


Fig 1. Panoramic radiograph of patient at age 7 years showing the severe ectopic eruption of both mandibular permanent molars.

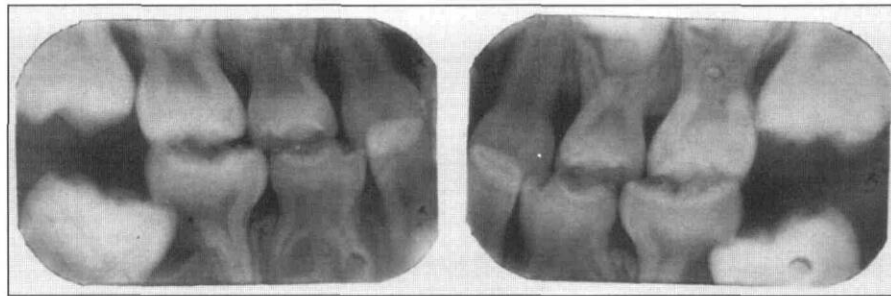

Fig 2. Bite-wing radiographs at age 7 years. Note the distal root resorption of both mandibular second primary molars.

The treatment plan for this patient consisted of hemisection of both mandibular second primary molars to allow vertical eruption of mandibular first permanent molars without further loss of arch circumference. Maintenance of arch circumference would be afforded by the remaining half of each mandibular second primary molar.

At treatment, using regional infiltration local anesthesia, both mandibular second molars were cut halfway through the crown with a fissure bur and then split with a straight elevator. Regional infiltration of local anesthetic was employed because we felt that both molars were nonvital and that a regional injection might provide hemostasis in an area of chronic inflammation. The distal portions then were removed. No patient discomfort was noted. Minimal bleeding occurred. Normal soft tissue was seen under the area of the

removed distal crown segments, the distal roots having been resorbed previously. Due to the fact that no periapical pathology was observed clinically or radiographically and that the crowns of the premolar teeth appeared to be fully calcified, we felt that there was little risk of damage to any unerupted permanent teeth in the area involved. Primary molar bands were cemented with glass ionomer cement on the remaining mesial portions of the primary second molars to guide the eruption of the first permanent molars.

Due to the unconventional treatment in this case, the patient was followed on a regular, periodic basis to closely observe the clinical health of the remaining mesial half of each mandibular second primary molar and to observe eruption of the first permanent molars. Bite-wing radiographs were deemed necessary and were exposed at each visit. We felt that if at any time this approach was unsuccessful, extraction and arch circumference maintenance could be instituted without incurring any additional risk to the patient.

Four months after treatment, the mandibular first permanent molars emerged. Since the mesial half of

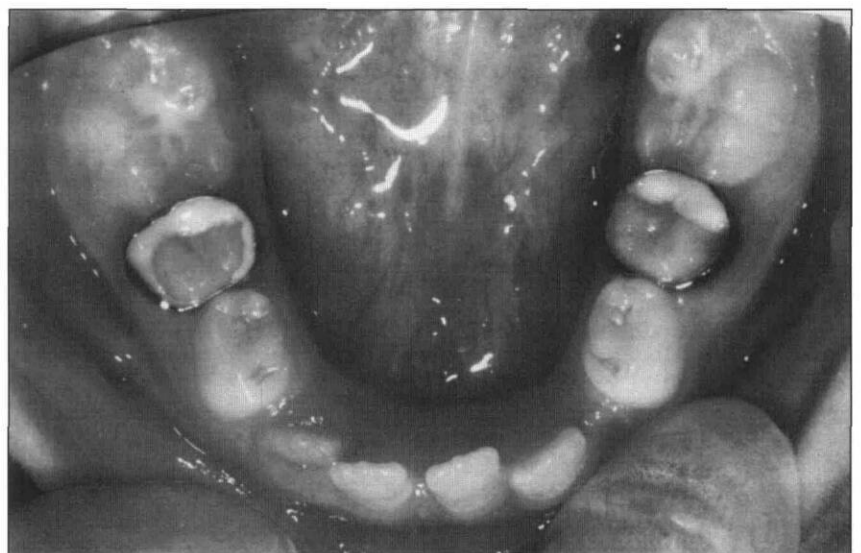

Fig 3. Photograph of mandibular arch 10 months post treatment showing hemisected primary molars with bands and showing successful eruption of first permanent molars.

each mandibular second primary molar was still intact and free of pathology, a lingual holding arch was considered unnecessary. Fig 3 shows the patient at 10 months post treatment. No soft tissue or periapical pathology was observed at this examination. Orthodontic bands and glass ionomer cement remained intact allowing for an eruption guide plane for the permanent molars. Fig 4 shows radiographs of the areas of interest 2 years post treatment. Permanent molar position was favorable and eruption of premolars was normal. Fig 5 is a full arch photograph 3 years after treatment. While the left second premolar erupted out of the ideal sequence, there continued to be no sign of pathology. Arch circumference was still inadequate for all permanent teeth, yet the patient had not lost additional arch circumference since treatment. Permanent molars were in a favorable vertical position.

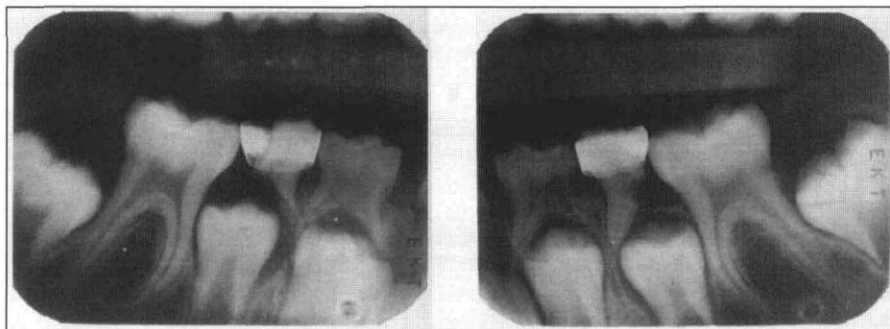


Fig 4. Bite-wing radiographs 2 years post treatment. Note the favorable position of first permanent molars.

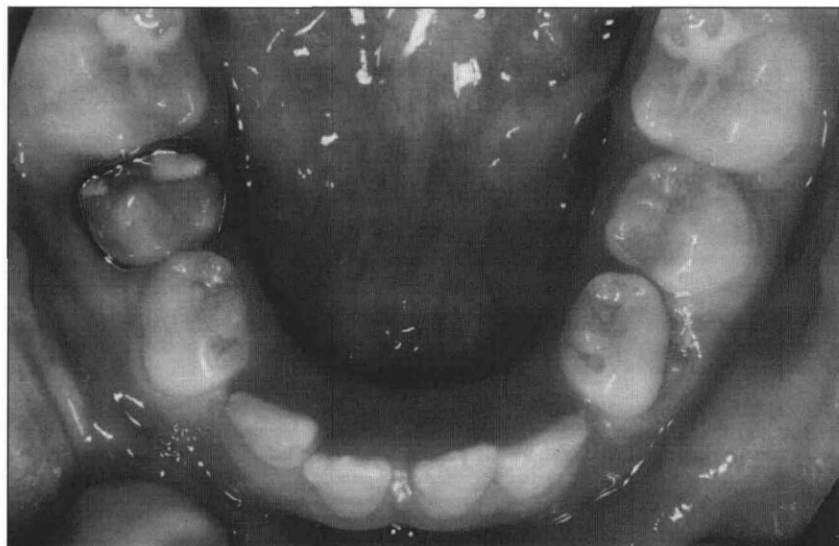

Fig 5. Photograph of mandibular arch 3 years post treatment.

Discussion

In this case report, irreversible ectopic eruption of mandibular first permanent molars is presented. Ectopic eruption of molars usually is associated with resorption of an adjacent primary tooth, frequently leads to molar impaction, and usually is associated with crowding. The patient described in this case report had all these associated clinical findings.

Duncan and Ashrafi¹¹ reported a case of an ectopically erupted mandibular first permanent molar, which was corrected by reducing the distal surface of the second primary molar thereby providing a clear pathway for eruption. In our case, the degree of ectopic eruption was more severe since nearly half of the mandibular first molars were impacted and the distal roots of the second primary molars were resorbed. We justified selecting hemisection of the second primary molars because orthodontic records led us to anticipate severe crowding and the need for further treatment. Extracting the entire second primary molar would have caused first permanent molar migration and mesial tipping, leading to more space loss and unfavorable mesial molar angulation.

Our primary goal was to allow for eruption of the mandibular first permanent molars by sectioning the distal part of the adjacent second primary molars. Bands placed on the second primary molars served as

guides for eruption of the ectopic molars. This strategy allowed a later decision on arch circumference reduction or maintenance.

The hemisection procedure performed in this case report is similar to that described by Sanders,¹² who recommended sectioning the crown of the primary molar, thus allowing for individual root removal when there is a need for modifications of routine extraction technique to avoid complications. For example, a hemisection is indicated when there is a close relationship between the partially formed permanent premolar crown and the roots of a mandibular first molar.

Based on clinical experience, primary molars with severely resorbed roots often contain pulpal soft tissue, which does not react pathologically to manipulation. Due to the clinical observation of normal-appearing soft tissue under the distal crown segment, we chose not to perform pulp therapy. Although a pulpotomy could have been performed as a preventive measure, we felt that the additional reduction of tooth structure might further compromise the integrity of the teeth and result in extraction of one or both teeth. If extraction of one or both teeth had become necessary, arch circumference maintenance would have been required. Due

to the incomplete eruption of the mandibular permanent first molars, one or more distal shoe appliances, followed by placement of a passive lingual holding arch would be required. The procedures performed in this case were done to avoid these additional treatments and their expense.

This report presents one treatment option for ectopic molars. However, cases should be selected carefully since this treatment results in arch length loss equal to about half the width of the primary second molar. The importance of preventing additional arch circumference loss in some patients is highlighted by this case. If the full width of the second primary molars was lost, the patient's arch circumference inadequacy could not have been treated by a single premolar extraction in each quadrant. When the relative simplicity of such treatment is weighed against the severity of the consequences of untreated cases of ectopic eruption, it can be argued that early intervention is important to assure a normal eruption pathway while minimizing detrimental effects on the developing occlusion.

Dr. Auychai is an instructor, department of pediatric dentistry, faculty of dentistry, Chulalongkorn University, Bangkok, Thailand. Dr. Feigal is a professor and head of pediatric dentistry, department of orthodontics and pediatric dentistry, University of Michigan, Ann Arbor. Dr. Walker is the associate dean for clinical affairs and professor of pediatric dentistry, Baylor College of Dentistry, Dallas, Texas.

1. Young DH: Ectopic eruption of the first permanent molar. *J Dent Children* 24:153-62, 1957.
2. Pulver F: The etiology and prevalence of ectopic eruption of the maxillary first permanent molar. *J Dent Child* 35:138-46, 1968.
3. Bjerklin K, Kurol J: Prevalence of ectopic eruption of the maxillary first permanent molar. *Swed Dent J* 5:29-34, 1981.
4. Bjerklin K, Kurol J: Ectopic eruption of the maxillary first permanent molar: etiologic factors. *Am J Orthod Dentofacial Orthop* 84:147-55, 1983.
5. Christensen JR, Fields HW: Treatment planning and treatment of orthodontic problems. In: *Pediatric Dentistry: Infancy through Adolescence*, JR Pinkham, Ed. Philadelphia: WB Saunders Co, 1994, pp 505-37.
6. Raghoebar GM, Boering G, Vissink A, Stegenga B: Eruption disturbances of permanent molars: a review. *J Oral Pathol Med* 20:159-66, 1991.
7. Kennedy DB, Turley PK: The clinical management of ectopically erupting first permanent molars. *Am J Orthod Dentofacial Orthop* 92:336-45, 1987.
8. van der Linden FPGM: Problems and procedures in dentofacial orthopedics. London: Quintessence, 1990, pp 297-300.
9. Ngan P, Wei SHY: Management of space in the primary and mixed dentitions. In: *Pediatric Dentistry: Total Child Care*, SHY Wei, Ed. Philadelphia: Lea & Febiger, 1988, pp 454-70.
10. Groper JN: Ectopic eruption of a mandibular first permanent molar: report of an unusual case. *ASDC J Dent Child* 59:228-30, 1992.
11. Duncan WK, Ashrafi MH: Ectopic eruption of the mandibular first permanent molar. *J Am Dent Assoc* 102:651-54, 1981.
12. Sanders B: Oral and maxillofacial surgery. In: *Pediatric Dentistry*, RE Stuart, TK Barber, KC Troutman, SHY Wei, Eds. St Louis: CV Mosby Co, 1981, pp 973-90.

Pediatric Dentistry is on the Web!

Visit the American Academy of Pediatric Dentistry's new web site at <http://aapd.org> to preview the abstracts of articles accepted for publication in *Pediatric Dentistry* months before they are published in the printed format. Abstracts will be on line as soon as manuscripts are accepted and will include the date accepted and a target date for publication in the journal.

By using world wide web browser software, readers, authors and advertisers can access other journal information immediately, including:

- Instructions for contributors
- Advertising rates and deadlines
- Subscription forms
- Reference Manual passages

Also on the AAPD site are content areas for members, parents, and the media; helpful tips and free, downloadable software to help you best access our site; and links to hundreds of other sites including other dental and health care organizations and academic, federal, and regulatory institutions.