

Oral submucous fibrosis in a 12-year-old girl: case report

S. Anil, BDS, MS V.T. Beena, BDS, MDS

Abstract

A case of oral submucous fibrosis in a 12-year-old girl discusses its etiopathogenesis, clinical features, and histopathologic findings of the condition and highlights strong association of areca nut chewing as the potential factor in the etiology of this condition. Cessation of the areca nut chewing habit and submucosal administration of aqueous extract of healthy human placental extract (Placentrex®) showed marked improvement of the condition. (Pediatr Dent 15: 120–22, 1993)

Introduction

Oral submucous fibrosis (OSMF) is an insidious chronic disease affecting the mucosa of any part of the oral cavity and occasionally extending into the pharynx and esophagus. The condition is sometimes preceded by and/or associated with vesicle formation, but always associated with a juxtaepithelial inflammatory reaction followed by a fibroelastic change of the lamina propria with epithelial atrophy, leading to stiffness of the oral mucosa and causing trismus and inability to eat.¹ OSMF has been well established in Indian medical literature since the time of Sushruta — a renowned Indian physician who lived in the era 2500–3000 B.C. It was first described in the modern literature by Schwartz in 1952.² Joshi³ first described the condition in India and suggested the name oral submucous fibrosis.

This condition is seen predominantly in Indians in India or Indians living in Malaysia, South Africa, and England.^{4–8} Sporadic cases of OSMF have been observed in China, Nepal, Thailand, and South Vietnam.⁹ From a series of epidemiological surveys conducted in India and South Africa, Pindborg⁹ found a prevalence rate ranging from zero in Bihar to 0.6% in Uttar Pradesh and Durban. He estimates that there are no fewer than 250,000 cases of OSMF in India.⁵ In a survey of cancer of buccal mucosa in India, Paymaster¹⁰ mentioned submucous fibrosis of the palate and tonsillar fossa as one of the interesting clinical findings. He found that a slow-growing carcinoma developed in the affected region in about one-third of patients showing submucous fibrosis of palate. The incidence of malignant transformation in patients with OSMF ranges from 3 to 7.6%.^{9, 11, 12}

The etiology of this crippling condition still remains obscure. Earlier workers correlated it with hypersensitivity to capsaicin (*Capsicum annuum* and *Capsicum frutescens*) — an active ingredient in chilies — secondary to chronic iron and/or vitamin B complex deficiencies; or exposure to cashew kernel oil.^{8, 13, 14} Sirsat and Khanolkar¹³ painted the palate of rats with capsaicin, but this produced only a limited connective tissue response. Ramanathan⁸ summa-

ri- zed the evidence of OSMF being a mucosal change secondary to chronic iron and/or Vitamin B Complex deficiency. He suggested that the disease is an Asian analogue of sideropenic dysphagia. According to Lal,¹⁵ without exception all cases had a history of chewing areca nuts. This association of betel nut chewing with OSMF was confirmed in subsequent studies.^{16–18} Currently, the habit of chewing areca nuts (the fruit of *Areca catechu* plant) is recognized as the most important etiologic agent in the pathogenesis of this condition. The betel nut has psychotropic and antihelminthic activity due to the presence of areca alkaloids, predominantly arecoline. These alkaloids have powerful parasympathetic properties, produce euphoria, and counteract fatigue.¹⁹

The occurrence of this condition in children is extremely rare. Review shows that only one case has been reported in the literature in a 4-year-old girl.²⁰ The case reported here is an advanced condition of OSMF in a 12-year-old girl. The only etiologic factor that could be traced in this case is the habit of chewing roasted areca nuts.

The management of OSMF depends largely upon the mucosal changes. The patient must be actively discouraged from chewing areca nut preparations. Medical and surgical management of the disease has been both empirical and unsatisfactory.^{21, 22} The intralesional injection of human placental extract (Placentrex®) has been shown to be effective, lasting, and safe.²³

Placentrex is an aqueous extract of human placenta that contains nucleotides, enzymes, vitamins, amino acids, and steroids. Its action is essentially "biogenic stimulation." It is suggested that it stimulates the pituitary and the adrenal cortex, and regulates the metabolism of tissues. It also increases the vascularity of tissues. Its use is based on the method of "tissue therapy" introduced by Filatov in 1933 and later in 1953.²⁴ His theory states, "Animal and vegetable tissues, when severed from the parent body and exposed to conditions unfavorable but not mortal to their existence, undergo biological readjustment leading to development of substances in state of their survival to ensure

their vitality. Such tissues or their extracts, implanted or injected into the body after resistances to pathogenic factors, stimulate the metabolic or regenerative processes, thereby favoring recovery. It has no contraindications and the results obtained are found to be lasting."

Case report

A 12-year-old girl from Andaman and Nicobar islands reported at the outpatient department of the Dental College Hospital, Trivandrum, Kerala, and complained of difficulty in opening the mouth, protrusion of the tongue, and intolerance to spicy food. She had a habit of chewing Pansupari™ (a proprietary preparation consisting of small pieces of roasted areca nut dusted with a powder containing slaked lime and unknown flavoring agents). She started the habit of chewing at age 7 years and continued it regularly since then (a minimum of once daily). No other family members had a similar condition.

The interincisal distance of maximal mouth opening was 1.7 cm. The oral mucosa appeared very pale. On

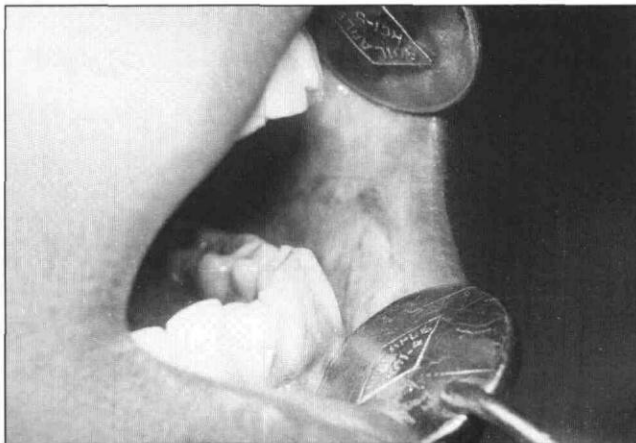

Fig 1. Restricted mouth opening and the blanched appearance of buccal mucosa.

palpation, the buccal mucosa had decreased elasticity and had a leathery consistency (Fig 1). Vertical fibrotic bands were palpable on both sides of the cheek. The soft palate had an opaque, white, blanched appearance. Tongue mobility was reduced, and the papillae on the surface of the tongue were atrophied (Fig 2).

Routine hematological analysis showed no abnormalities. Radiographs of the temporomandibular joints were exposed to exclude pathology. A biopsy was taken from the exposed buccal mucosa. Histopathologic examination revealed atrophic epithelium with absence of rete ridges. The underlying connective tissue showed hyalinization. A moderate number of chronic inflammatory cells were present under the epithelium (Fig 3). We diagnosed oral submucositis fibrosis and advised the patient to stop chewing areca nuts. Submucous (intralesional) injection of aqueous extract of healthy human placenta (Placentrex, 2 ml)

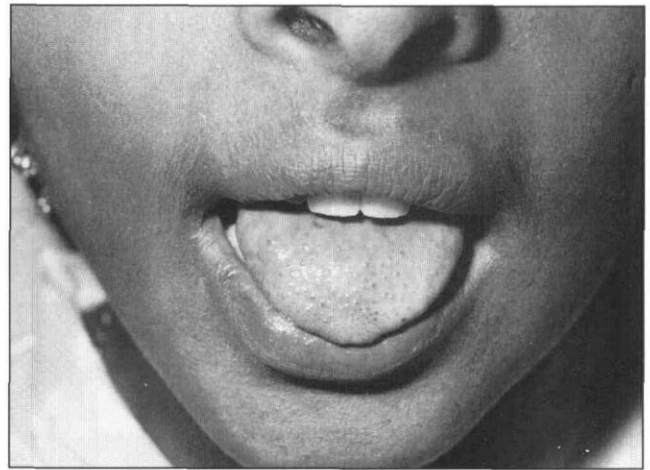


Fig 2. Limited protrusion of the atrophic tongue.

was given for two months to the regions with palpable fibrotic bands. The procedure was repeated at an interval of three days. Each time, 2 ml of solution was deposited around the specific region on both sides. There was a remarkable improvement in the burning sensation of the mouth and moderate improvement in mouth opening.

Discussion

The role of areca nut as an etiologic factor in OSMF has gained attention during recent years.^{19,25} The frequency of areca nut chewing habit reported ranges from 84 to 100% in OSMF cases.^{17,18} Sinor et al.,¹⁸ in a case control study, demonstrated that this condition occurred only among those who chewed areca nuts in one form or other.



Fig 3. Oral submucositis fibrosis — histopathologic appearance of buccal mucosa showing atrophic epithelium and hyalinized lamina propria — H&E stain (original magnification, 100x).

The exact role of the areca nut in causing OSMF is not defined yet. HLA-DR typing suggests that there might be an HLA-linked genetic susceptibility for areca nut alkaloids and tannins in individuals with this condition.²⁵

In this case, the interception of the areca nut chewing habit and intralesional injection of human placental extract showed marked improvement of the condition.

Dr. Anil is assistant professor and Dr. Beena is lecturer, Government Dental College and Hospital, Kerala, India.

1. Pindborg JJ, Sirsat SM: Oral submucous fibrosis. *Oral Surg* 22:764-79, 1966.
2. Schwartz J: Atrophia idiopathica (tropica) mucosae Oris. demonstrated at the eleventh International Dental Congress. London, 1952.
3. Joshi SG: Submucous fibrosis of the palate and pillars. *Indian J Otolaryngol* 4:1-4, 1953.
4. Lemmer J, Shear M: Oral submucous fibrosis: a possible case in a person of Caucasian descent. *Br Dent J* 122:343-46, 1967.
5. Pindborg JJ, Mehta FS, Gupta PC, Daftary DK: Prevalence of oral submucous fibrosis among 50,915 Indian villagers. *Br J Cancer* 22:646-54, 1968.
6. Simpson W: Submucous fibrosis. *Br J Oral Surg* 6: 196-200, 1969.
7. Dockrat I, Shear M: Oral submucous fibrosis in Natal. *Proc Int Acad Oral Path* 4:57-63, 1970.
8. Ramanathan K: Oral submucous fibrosis — an alternative hypothesis as to its causes. *Med J Malaysia* 36:243-45, 1981.
9. Pindborg JJ: Is submucous fibrosis a precancerous condition in the oral cavity? *Int Dent J* 22:474-80, 1972.
10. Paymaster JC: Cancer of buccal mucosa: a clinical study of 650 cases in Indian patients. *Cancer* 9:431-35, 1956.
11. Pindborg JJ, Zachariah J: Frequency of oral submucous fibrosis among 100 South Indians with oral cancer. *World Health Organ* 32:750-53, 1965.
12. Pindborg JJ: Oral submucous fibrosis as a precancerous condition. *J Dent Res* 45:546-53, 1966.
13. Sirsat SM, Khanolkar VR: Submucous fibrosis of the palate in diet-preconditioned Wistar™ rats. Induction by local painting of capsaicin. *Arch Pathol* 70:171-79, 1960.
14. Rajendran R, Anil S, Vijayakumar T: Risk of Oral Submucous Fibrosis (OSMF) Among the Factory Workers of Kerala, South India, Exposed to Cashew. *Proc Int Con Primary Health Care* 9-12, 1988, New Delhi.
15. Lal D: Diffuse oral submucous fibrosis. *J All India Dent Assoc* 26:1-3, 14-15, 1953.
16. George AT: Submucous fibrosis of the palate and buccal mucous membrane. *J Indian Med Assoc* 31:489-90, 1958.
17. Murti PR, Gupta PC, Bhonsle RB, Daftary DK, Mehta FS, Pindborg JJ: Effect on the incidence of oral submucous fibrosis of intervention in the areca nut chewing habit. *J Oral Pathol Med* 19:99-100, 1990.
18. Sinor PN, Gupta PC, Murti PR, Bhonsle RB, Daftary DK, Mehta FS, Pindborg JJ: A case-control study of oral submucous fibrosis with special reference to the etiologic role of areca nut. *J Oral Pathol Med* 19:94-98, 1990.
19. Canniff JP, Harvey W: The aetiology of oral submucous fibrosis. The stimulation of collagen synthesis by extracts of areca nut. *Int J Oral Surg* 10: (Suppl 1):163-67, 1981.
20. Hayes PA: Oral submucous fibrosis in a 4-year-old girl. *Oral Surg* 59:475-78, 1985.
21. Gupta D, Sharma SC: Oral submucous fibrosis — a new treatment regimen. *J Oral Maxillofac Surg* 46:830-33, 1988.
22. Yen DJC: Surgical treatment of submucous fibrosis. *Oral Surg* 54:269-72, 1982.
23. Rananjaneyulu P, Rao P: Submucous fibrosis — new treatment. *J Indian Dent Assoc* 52:379-80, 1980.
24. Filatov VP: Tissue Therapy: Teaching on Biogenic Stimulators. Moscow: Foreign Language Publishing House, 1955, p. 2.
25. Canniff JP, Batchelor JR, Dodi IA, Harvey W: HLA-typing in oral submucous fibrosis. *Tissue Antigens* 26:138-42, 1985.