

Clinical Article

A Simplified Isolation Technique for Preparation and Placement of Resin Composite Strip Crowns

Gregory L. Psaltis, DDS¹ • Ari Kupietzky, DMD, MSc²

Abstract: Resin composite strip crowns (SCs) have been utilized for over 2 decades to restore carious primary teeth. While SCs are the most esthetic anterior crowns, they also are the most technique sensitive. Restoration of a severely decayed primary anterior tooth with a SC restoration is often complicated by hemorrhage in the operative site. Inflamed, bleeding gingiva may interfere with proper curing of the restorations, resulting in discolored crowns due to excessive bleeding during the curing process. Proper isolation and hemostasis is crucial for successfully completing the SC restoration. Traditionally, the routine use of ligature ties to deflect gingival tissue and retain the rubber dam in place has been recommended to address this problem. The purpose of this report was to describe a simple, relatively inexpensive, alternative technique for placing SCs by utilizing orthodontic elastomers. (*Pediatr Dent* 2008;30:436-8) Received July 17, 2007 | Last Revision October 4, 2007 | Revision Accepted October 8, 2007

KEYWORDS: PRIMARY INCISORS, STRIP CROWNS, RESTORATIVE DENTISTRY

Resin composite strip crowns (SCs) have been utilized for over 2 decades to restore carious primary teeth.^{1,2} While SCs are the most esthetic of all restorations for the treatment of decayed primary incisors³ and parental satisfaction is high,⁴ they are the most technique sensitive. Restoration of a severely decayed primary anterior tooth with an SC restoration is often complicated by hemorrhage around the operative site. Proper isolation and hemostasis are crucial for successfully completing the SC restoration. Ideal oral hygiene prior to commencement of treatment is preferred but not always possible. Many children appear for treatment with inflamed gingiva, which may interfere with proper curing of the restorations, resulting in discolored crowns due to excessive bleeding during the curing process. Traditionally, the routine use of ligature ties to deflect gingival tissue and retain the rubber dam in place has been recommended to address this problem.

Ligature ties, however, often cause bleeding and discomfort for the patient. Their use may inhibit rapid removal of the




Figure 1. Thread 2 strands of floss through each elastomer.

rubber dam during treatment. The removal of the ligatures, which are situated under the cured restoration, is often difficult after curing.

The purpose of this report was to describe a simple and relatively inexpensive alternate technique for placing SCs by utilizing orthodontic elastomers.

Clinical technique

The clinical technique and step-by-step procedures for placing SCs were described and fully illustrated in a previous report.¹ This paper describes the use of orthodontic elastomeric ligatures, also commonly known as Alastiks (3M Unitek, Monrovia, Calif), in place of ligatures for the specific purposes of rubber dam retraction and virtual elimination of the problems of

¹Dr. Psaltis is a pediatric dentist in private practice, Olympia, Wash; and ²Dr. Kupietzky is a pediatric dentist in private practice, Jerusalem, Israel and a visiting professor, Department of Pediatric Dentistry, New Jersey Dental School, University of Medicine and Dentistry of New Jersey, Newark, NJ. Correspond with Dr. Kupietzky at drkup@netvision.net.il

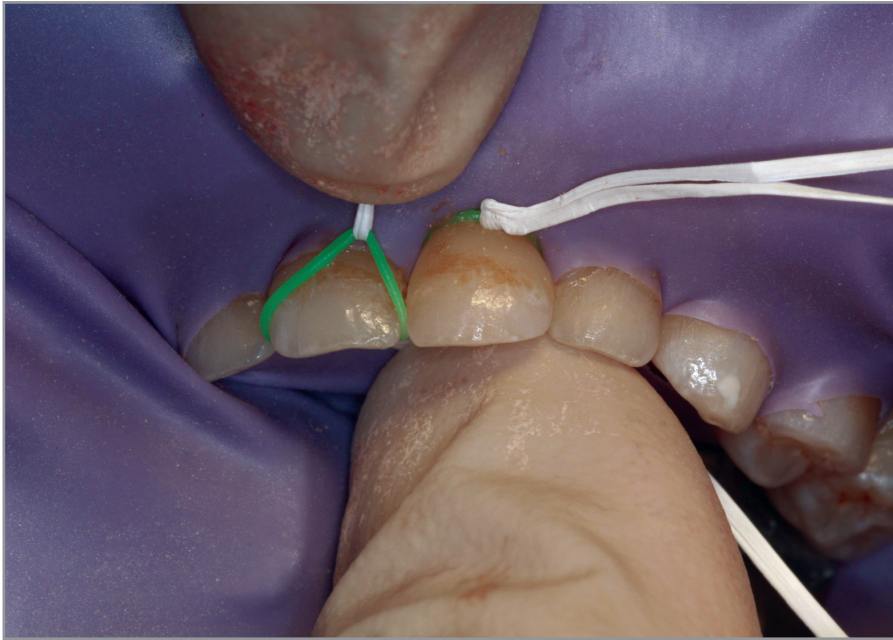


Figure 2. The elastomer is stretched and eased over the tooth with the labial and palatal floss strands.

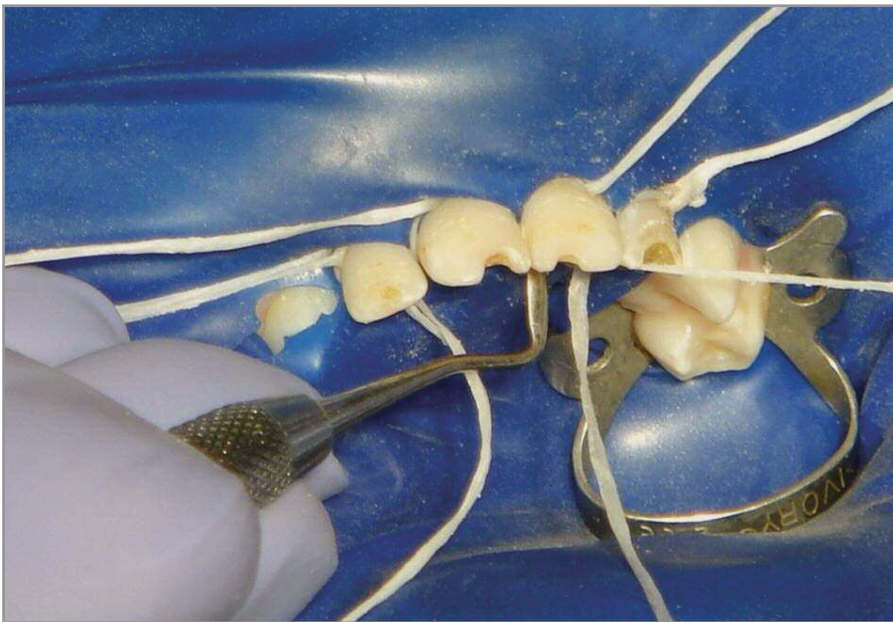


Figure 3. A Hollenback carver or a similar hand instrument may be used to guide the elastomer in place.

blood and saliva contamination of the operative areas. This technique's success depends on 3 key steps:

1. Use a rubber dam punched with 4 holes of the smallest possible size. This allows the tightest fit, eliminates leakage, and enables the elastomers to retract the dam more effectively around the teeth. It is recommended to space the 4 holes over the center of each maxillary incisor. Placement too close together will result in stretching of the rubber dam between the teeth and subsequent leakage around the teeth.

2. Place orthodontic elastomers over each incisor after placement of the rubber dam. This is accomplished by threading 2 strands of floss through each elastomer (Figure 1) and then stretching it over the tooth (Figure 2). If the interproximal areas are sharp or jagged due to caries, the elastomers may tear during this process. If so, slice through the jagged areas with a thin fissure bur (no. 169 or 1169) to eliminate them. In many cases, the elastomers can be flossed into place by pulling them simultaneously from each tooth's labial and lingual surfaces. It also is sometimes necessary to facilitate this procedure by using a Hollenback carver or a similar hand instrument that can tuck the elastomer well into the gingival sulcus around each tooth (Figure 3). When the elastomers have been properly place over a well-punched rubber dam, they will almost immediately begin to contract. Consequently, they also will retract the dam and gingival tissues. If any treatment is to be completed in the posterior segments, it is best to proceed and complete them first to give the elastomers more time to continue this retraction process. Once the elastomers are in place, remove the piece of floss from the lingual side, but leave the labial floss in place.

3. Remove the elastomers with the labial floss after the preparation and restoration of the incisors have been completed (Figure 4). It is critical to remove the elastomers, as they will continuously migrate up the conical-shaped root on any of the incisors and, if left in place, can atraumatically and asymptotically "extract" the tooth. Hence, the facial floss provides an easy way to remove the elastomer and serves as a reminder.

The proper use of these elastomers eliminates the tedious tying (and removal) of floss ligatures and virtually eliminates

any hemorrhaging to ensure a clean field for placement of the strip crowns.

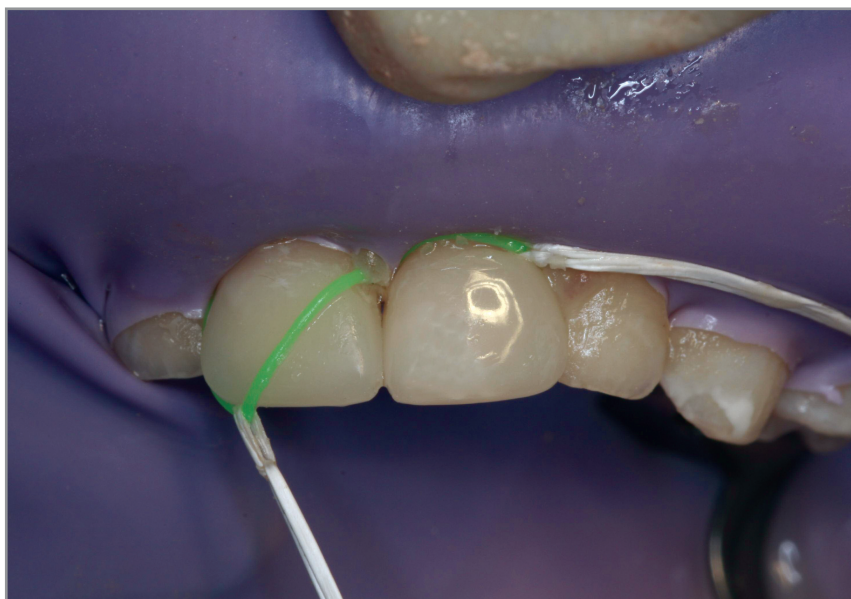

Figure 4. The elastomers are removed from the facial by using the floss that was left in place.

References

1. Kupietzky A. Bonded resin composite strip crowns for primary incisors. *Pediatr Dent* 2002;24:145-8.
2. Lee JK. Restoration of primary anterior teeth: Review of the literature. *Pediatr Dent* 2002;24:506-10.
3. Waggoner WF. Restoring primary anterior teeth. *Pediatr Dent* 2002;24:511-6.
4. Kupietzky API, Waggoner WF. Parental satisfaction with bonded resin composite strip crowns for primary incisors. *Pediatr Dent* 2004;26:337-40.

Abstract of the Scientific Literature

Relationship between caregiver's and child's caries prevalence among disadvantaged African Americans

The purpose of this study was to assess the relationship between African-American caregivers' and children's caries levels adjusting for socio-demographic factors. A representative sample of 1021 children (0-5 years) and their caregivers were recruited from low-income households in Detroit. The response rate was 74%. Participants completed interviewer-administered questionnaires and underwent an oral examination. Data were collected on sociodemographic characteristics, food frequency and several oral health parameters, including caries, missing teeth, oral hygiene, periodontal measures, and edentulism. Younger children (ages 0-3 years) had lower caries rates (18% having a cavitated lesion), compared with 51% among the 4- to 5-year olds. Multivariate analyses found that the number of cavitated surfaces among the caregivers was significantly related to the number of cavitated and noncavitated lesions among their children for both age groups. The prevalence of children with caries increased with increasing caregivers' caries scores when demographic characteristics of caregivers were controlled. Younger children with family incomes < \$10,000 had a significantly increased risk of higher caries prevalence compared with children in families with incomes >\$20,000. Although caregivers' caries levels were modestly correlated with children's caries, higher caries prevalence significantly increased the risk of caries prevalence among their children. Thus, improving caregivers' oral health could result in reducing caries risk among their children, regardless of a biological or behavioral mechanism. In addition, the authors recommended increasing fluoride exposure and improving access to preventive dental care for these children, and noted that even small increases in family income could have a significant effect on reducing caries risk among young children.

Comments: The results reinforced the importance of improving caregivers' oral health to reduce caries risk in children but also demonstrated the need for multi-factorial considerations of caries risk and prevention strategies. **PJL**

Address correspondence to Dr Susan Reisine, 263 Farmington Ave, Farmington, Conn 06030-3910; e-mail: reisine@nso1.uchc.edu

Reisine S, Tellez M, Willem J, Sohn W, Ismail A. Relationship between caregiver's and child's caries prevalence among disadvantaged African Americans. *Community Dent Oral Epidemiol* 2008; 36:191-200.

44 references