

Case Report

Multiple Lesions of Intracoronal Resorption of Permanent Teeth in the Developing Dentition: A Case Report

Hiroko Hata, DDS, PhD¹ • Maki Abe, DDS² • Hideaki Mayanagi, DDS, PhD³

Abstract: *The purpose of this case report is to describe an unusual presentation of multiple lesions of intracoronal resorption in the permanent teeth in a healthy boy. Longitudinal radiographs demonstrated that all 3 lesions were acquired after the crowns were completely formed. Unlike previous reports in which intracoronal radiolucencies have been found in unerupted teeth or in newly erupting teeth, one lesion in this case developed in a fully erupted tooth, which was differentiated from internal resorption and invasive cervical resorption of the root. All were considered idiopathic external resorption, but they demonstrated diversities in size, appearance, and involvement of pulp and the rate of progression. Conservative treatment was performed. All remained asymptomatic, showing normal root development. This case report indicates that intracoronal resorption is a condition demonstrating a diversity of clinical features. (Pediatr Dent 2007;29:420-5) Received August 13, 2006 / Revision Accepted January 1, 2007.*

KEYWORDS: INTRACORONAL RESORPTION, IDIOPATHIC RESORPTION, TOOTH DEVELOPMENT

Intracoronal radiolucencies in unerupted permanent teeth have been reported in sporadic case reports.¹⁻¹⁵ Histological findings from several case reports demonstrated that the lesions are resorptive,¹⁻⁴ while nonprogressive lesions that were considered developmental anomalies in origin have also been reported.⁵⁻⁸ These lesions mainly occur in permanent molars or premolars, while canines or incisors are rarely involved.^{16,17} The authors previously reported a rare case in which a permanent maxillary central incisor was affected.¹⁸ Subsequently, new resorptive lesions occurred in other teeth in this case, and moreover, one of them developed within the crown of a fully erupted tooth.

This study's purpose was to describe an unusual case with multiple lesions of intracoronal resorption and to compare the clinical findings and progression of lesions between the previously reported lesion¹⁸ and the newly developed lesions using longitudinal radiographs.

Case report

The patient was a healthy boy with no remarkable medical history. He was raised in a nonfluoridated area in Japan and did not have any fluoride supplementation. He visited

the pediatric dental clinic of Tohoku University, Sendai, Japan, for evaluation of an anterior open bite at age 6 years. The intraoral examination revealed a full, normal primary dentition. He exhibited an anterior open bite with a 1-mm overjet. He had no history of any sucking habits or tooth trauma, and the cause of the open bite was not identified. A panoramic radiograph showed normal development of permanent teeth, except for the congenitally missing mandibular left central incisor. Proximal caries was detected with bitewing radiography in all primary molars. After restorations with composite resin and stainless steel crowns, he was followed every 6 months.

Recall examination at age 8.5 years revealed a large radiolucent defect in the crown of a newly erupting permanent maxillary right central incisor. Two years and 5 months later, other radiolucent defects were detected in the crowns of a fully erupted permanent mandibular lateral incisor and an unerupted permanent mandibular left second premolar. Because of the unusual event in the maxillary central incisor, panoramic radiographs were taken annually to examine the other unerupted teeth for resorptive lesions until age 12 years, and the suspicious sites were thoroughly examined by bitewing or periapical radiography.

The clinical findings, radiographic findings, and management of each tooth are described as follows.

Permanent maxillary central incisor

Clinical examination at age 8.5 years revealed an extensive

¹Dr. Hata and ²Dr. Abe are in private practice, Sendai, Japan; and ³Dr. Mayanagi was professor in the Department of Oral Health and Development Sciences, Division of Pediatric Dentistry, Graduate School of Dentistry, Tohoku University, Sendai Japan.
Correspond with Dr. Hata at hiroko@mail.tains.tohoku.ac.jp

destruction in the crown of a recently erupted permanent maxillary right central incisor (Figure 1a). The patient had not experienced pain or any other symptoms, although his mother had recognized the eruption of a discolored incisor. Except for a thin enamel shell on the labial surface, the hard tissue in the crown's mesial region was replaced by pink soft tissue, which was associated with the palatal gingival tissue.

sue in the defect was curetted away and a pinhole exposure of pulp was revealed (Figure 2a). A partial pulpotomy with calcium hydroxide ($\text{Ca}(\text{OH})_2$) powder in sterile saline was performed to a depth of approximately 1 mm, followed by a glass ionomer interim restoration. Histological examination revealed that the soft tissue in the defect was granulation tissue that demonstrated chronic inflammation. After

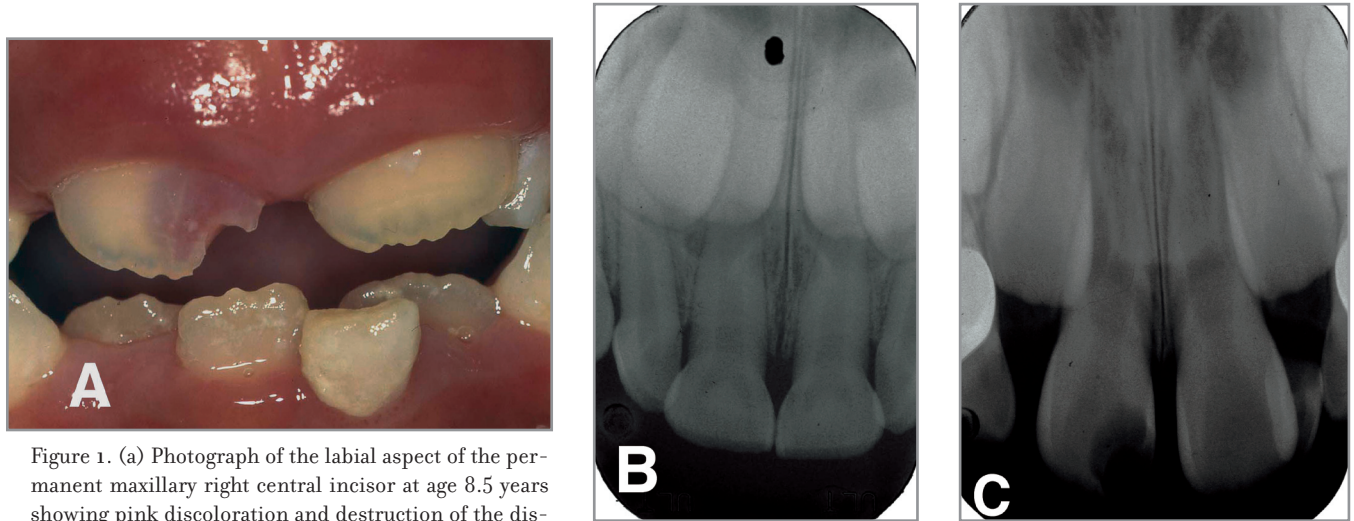


Figure 1. (a) Photograph of the labial aspect of the permanent maxillary right central incisor at age 8.5 years showing pink discoloration and destruction of the distal region of enamel. (b) Periapical radiograph at age 6 years showing normal development of the permanent maxillary right central incisor. (c) Periapical radiograph at age 8.5 years showing a large radiolucency close to the pulp (from Abe M et al¹⁸).

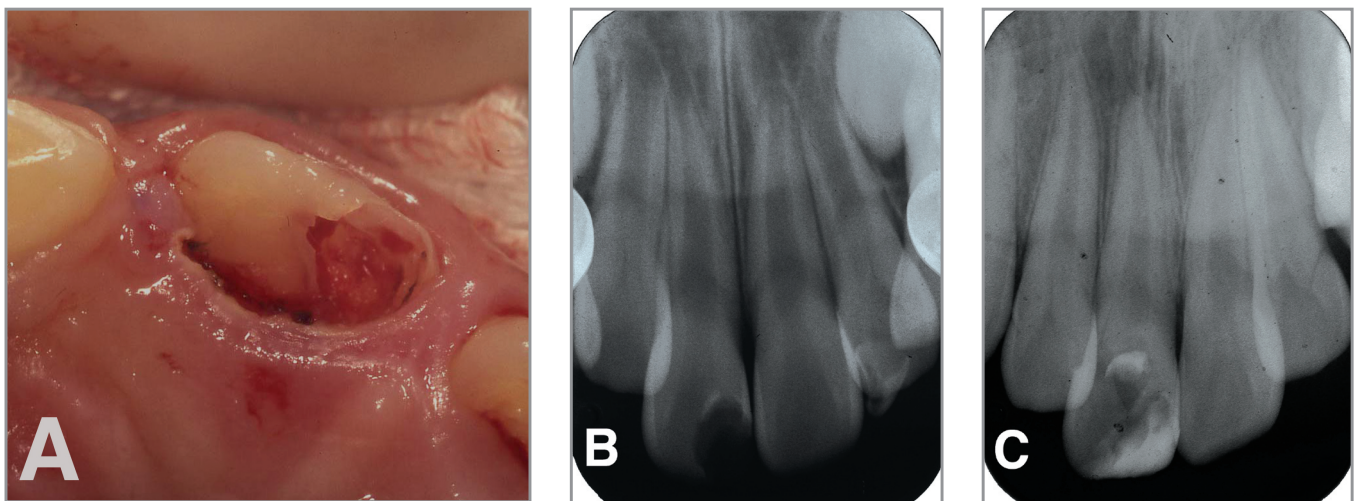


Figure 2. (a) Photograph of the palatal aspect after removal of soft tissues showing a large defect including enamel. (b) Periapical radiograph at age 11 years showing normal root formation (from Abe M et al¹⁸). (c) Periapical radiograph at 2 years 6 months after traumatic crown fracture and subsequent partial pulpotomy showing reparative dentin formation and apical maturation (age 13 years 8 months).

It appeared that gingival tissue had grown into the defect.

Although the radiograph at age 6 years demonstrated that the tooth's crown had been formed normally, the radiograph at age 8.5 years demonstrated a clear, oval, radiolucent lesion close to the pulp (Figure 1b, 1c). No signs of periapical inflammation were found. After local anesthesia, the tis-

2 months, reparative dentin formation was confirmed by probing and a final composite restoration was placed. This tooth had been asymptomatic, and a periapical radiograph taken at age 11 years showed normal root formation (Figure 2b). It was traumatized, however, at age 11 years 2 months. The crown's distal portion was fractured with a pulp exposure

approximately 0.5 mm in diameter at the distal pulp horn. A partial pulpotomy was performed to a depth of approximately 2 mm. Since then, all clinical and radiographic findings indicated normal pulp vitality and normal root formation over 3 years (Figure 2c).

Permanent mandibular lateral incisor

Clinical examination at age 10 years 11 months revealed a pink spot lesion on the permanent mandibular right lateral incisor's labial surface (Figure 3a). The patient was not aware of this and had not experienced any discomfort. The tooth was displaced lingually, and inflammation of the marginal gingiva was seen. No defects connecting to the lesion were detected by probing the enamel surface, including within the gingival sulcus. The periapical radiograph showed a radiolucent defect in the dentin pulpal to the dentoenamel junction (DEJ) on the mesial surface (Figure 3b). The lesion was clearly separated from the pulp with a layer of dentin.

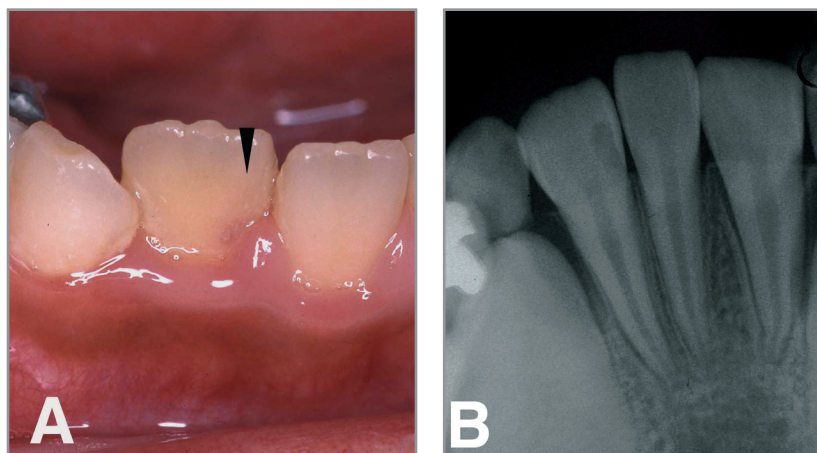


Figure 3. (a) Photograph of labial aspect of the permanent mandibular right lateral incisor showing a pink spot area (arrow). (b) Periapical radiograph at age 10 years 11 months showing a radiolucent defect in the dentin pulpal to the dentoenamel junction on the mesial surface.

Reviewing past records, this tooth erupted between age 8 years and age 8.5 years. No periapical radiograph for mandibular incisors was available prior to age 8.5 years. Three panoramic radiographs taken from age 8.5 years to 10 years 1 month were reviewed, although these films provided unclear views for anterior teeth. Figures 4 shows the details of panoramic radiographs for the mandibular anterior teeth. Although the defect was not detected at age 8.5 years, a suspicious radiolucency was found at age 9 years 3 months and it became more apparent at age 10 years 1 month.

Although the authors recommended immediate treatment, it was postponed because the patient did not consent to immediate treatment for personal reasons. Three months later, at age 11 years 4 months, progression of the lesion was evaluated by periapical radiography, but no change in the lesion was apparent (Figure 5a). The lesion, however, clearly enlarged after 1 year (Figure 5b). The decision to open the lesion was made at age 12 years 1 month. After local anesthesia, a gingivectomy was performed for the labial gingiva of the affected tooth and the adjacent central incisor, and both teeth were isolated with a rubber dam. The enamel over the translucent area was removed with a high-speed bur. The tissue in the defect was small, fragile, soft, pink tissue. Because it was attached strongly to the cavity wall, it was removed with a low-speed steel round bur. Consequently, the tissue was not submitted for histological examination.

After removing the soft tissue with a low-speed bur, the cavity wall was examined with a sharp explorer. No pulp exposure was found, but a pinhole connecting to the gingival tissue was detected on the cervical part of the enamel. The cavity was lined with Ca(OH)₂ liner and restored with composite resin. All clinical

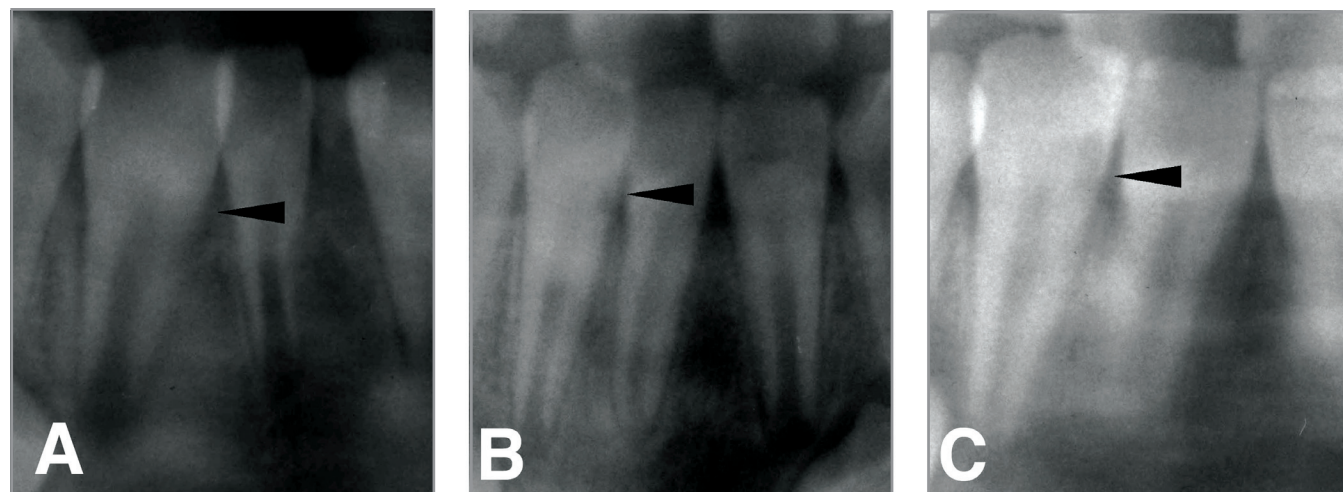


Figure 4. Details of panoramic radiographs showing the development of the lesion of the permanent mandibular right lateral incisor. (a) Panoramic radiograph at age 8.5 years showing no clear lesion. (b) Panoramic radiograph at age 9 years 3 months showing suspicious radiolucency (arrow). (c) Panoramic radiograph at age 10 years 1 month showing small radiolucency (arrow).

cal and radiographic findings indicated normal pulp vitality and normal periodontal tissue during the following 3 years (Figure 5c).

Opening the overlying enamel carefully with a high-speed bur revealed that the distal pit was connected to the defect. The tissue within the defect was small and pink; it was re-

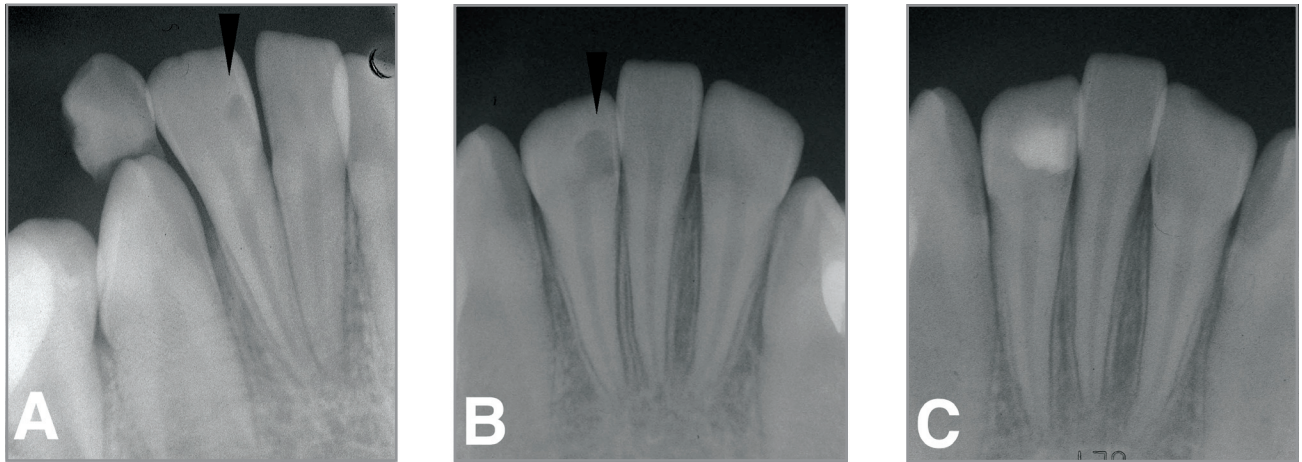


Figure 5. (a) Periapical radiograph of the permanent mandibular right lateral incisor at age 11 years 4 months. Progression of the lesion was not apparent compared to Figure 2b (arrow). (b) Periapical radiograph at age 12 years showing the extended lesion (arrow). (c) Periapical radiograph at 18 months after treatment (age 13 years 8 months) showing apical maturation.

Mandibular second premolar

Radiographic examination at age 10 years 11 months revealed a small radiolucent lesion beneath the occlusal distal pit of the mandibular left second premolar, which was not found in a panoramic radiograph taken 10 months earlier. After a year, the lesion had enlarged. Figure 6 shows the details of panoramic radiographs for the mandibular left premolars, which exhibit the enlargement of a radiolucent lesion in the mandibular left second premolar. The tooth was exposed by extraction of the primary second molar. The tooth's occlusal surface was macroscopically intact, but the examination with an explorer revealed that soft tissue was passing into the distal pit.

removed by an excavator. The tissue was not submitted for histological examination. No pulp exposure was found, and the defect was lined with Ca(OH)_2 prior to a glass ionomer interim restoration. The tooth remained asymptomatic and the root developed normally (Figure 7).

Discussion

Although some cases of intracoronal radiolucencies appear to be developmental anomalies in origin, most cases are considered to be caused by external resorption.^{1-4,9-15} Cases that provide longitudinal radiographs demonstrating the lesion's progression, however, are limited.^{9,10} In this case, all lesions

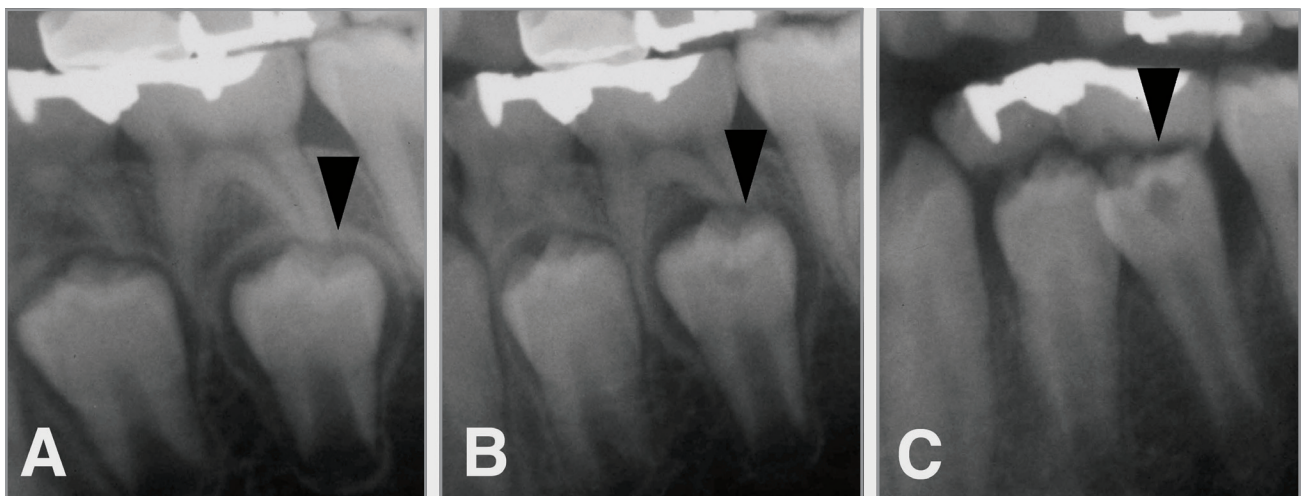


Figure 6. Details of panoramic radiographs showing the development of the lesion of the permanent mandibular left second premolar. (a) Panoramic radiograph at age 10 years 1 month showing no radiolucency within the crown. (b) Panoramic radiograph at age 10 years 11 months showing small radiolucency just beneath the occlusal enamel (arrow). (c) Panoramic radiograph at age 12 years showing enlarged radiolucency (arrow).

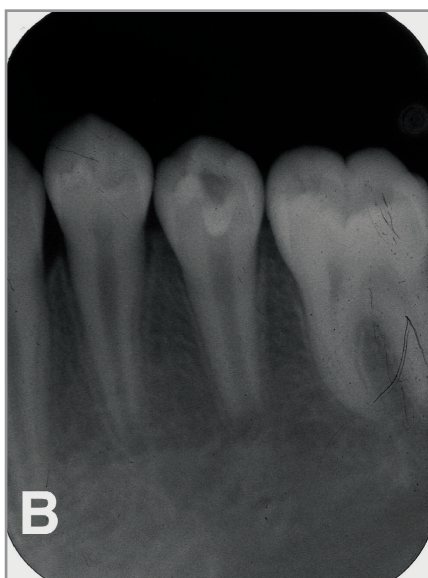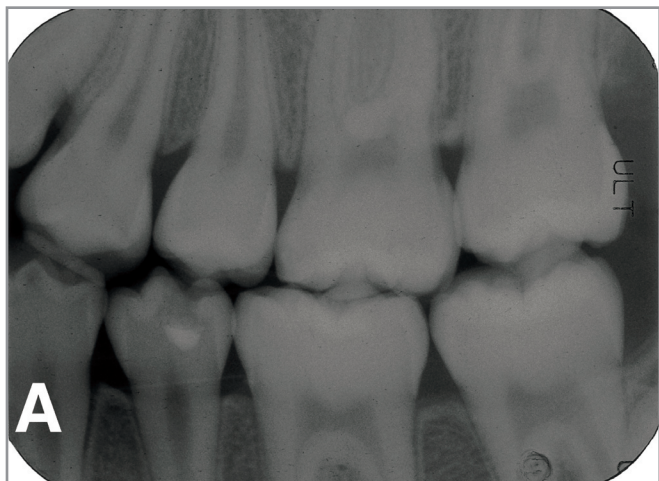


Figure 7. (a) Bitewing radiograph of the mandibular left second premolar at 18 months after treatment (age 13 years, years 8 months) showing a layer of sound dentin separating the pulp and the filling. (b) Periapical radiograph of the permanent mandibular left second premolar at age 13 years, years 8 months showing continuing root formation.

were acquired after the dental crowns were formed completely, suggesting the cause of the lesions to be external resorption. The crown formation of the maxillary right central incisor was normal at age 6 years on radiographs, but a large defect that involved the pulp was found after 2 years 6 months.

Compared to this tooth, the progression of the lesions in the mandibular right lateral incisor and the mandibular left second premolar was slow. This suggests that intracoronal resorption varies in the rate of progression, even within a single individual. Therefore, if a lesion is found in an unerupted tooth, the progression rate should be ascertained and the timing for intervention should then be determined, ex-

cept in cases where there is danger of pulp involvement. The lesion progression of the mandibular right lateral incisor was not apparent after follow-up at 5 months. This suggests that a 6-month follow-up is not sufficient to determine whether a lesion is progressive in slowly progressing lesions.

A lesion of the mandibular incisor was detected approximately 3 years after eruption. The clinical features suggested that this lesion might be an invasive cervical resorption—a type of external root resorption that involves the tooth's cervical area.¹⁹ The treatment procedure, however, revealed that the exterior opening was located on the enamel and the root was not affected. Furthermore, pulp exposure was not detected within the defect. Therefore, this lesion was differentiated from either internal resorption or invasive cervical resorption of the root, and it was considered an intracoronal resorption.

Some authors have reported that the tissue within a defect of pre-eruptive intracoronal resorption is necrotic tissue,^{11,12} suggesting that the vascular supply to the resorptive lesions is cut off upon eruption. Thus, most lesions arrest upon eruption, while the risk of microbial infection increases. If the channel communicating with the external tissue is located near the cemento-enamel junction (CEJ), however, the vascular supply will be maintained and the progression of the lesion will not arrest, even though the tooth has erupted. In this case study, the defect that is too small to detect on radiography might possibly exist before eruption. It might enlarge gradually, being found eventually. Seow¹³ reported a second premolar with a crown that was fractured during orthodontic debanding as a result of intracoronal resorption. In that case, the entry of resorptive cells was considered to be located near the CEJ.

Because of the unusual event in the maxillary central incisor, the other unerupted teeth were examined and followed by panoramic radiographs. Consequently, the lesion in the second premolar was detected at an early stage. Although the prevalence of intracoronal radiolucencies in unerupted teeth examined by bitewing radiographs is slightly higher (6% by subjects, 2% by teeth)²⁰ than panoramic radiographs (3% by subjects, <1% by teeth),¹⁷ Seow et al reported that panoramic radiographs aid in the diagnosis of lesions in unerupted developing teeth.¹⁷ The lesion in the permanent mandibular lateral incisor was overlooked, however, until it became detectable by visual inspection because panoramic radiographs provide unclear views of anterior teeth. Anterior teeth, including erupted teeth, should have been examined by periapical radiography.

The maxillary central incisor with an exposed pulp was treated by partial pulpotomy because the tooth was asymptomatic. This procedure appears to be successful in treating immature teeth with cariously exposed pulps and teeth with crown-fracture exposed pulps.²¹ Compared to cervical pulpotomy, one of the advantages of partial pulpotomy is the

preservation of cell-rich coronal pulp tissue, which allows for the deposition of dentin in a cervical area. Rankow et al reported the successful case of a pulp-exposed permanent canine treated by direct pulp capping.⁴ Considering the possible infection and inflammation of pulp in an exposed area, however, the authors recommend the partial pulpotomy.

Previous cases of pre-eruptive intracoronal resorption showed the: (1) diversity of lesion size; (2) integrity of enamel; (3) tissues within the defect; and (4) involvement of pulp.^{1,4,9-15} Interestingly, all lesions in this case also varied in those points, plus the rates of progression and the time when the lesions were detected, although histological examination was not performed in the latter 2 cases. In these cases, an adequate amount of tissue needed for histological examination was not obtained. If the tooth structure around the cavity was cut using a high-speed bur and tooth fragments adjacent to soft tissue were excised, histological examination might be possible. The authors, however, considered that the preservation of tooth structure was preferable.

A possible initiating factor of intracoronal resorption discussed in previous reports is a breakdown in reduced enamel epithelium that may result in the invasion of resorptive connective tissues into dentin.^{3,4,9,14} Ectopic positioning or impaction of the tooth may be a trigger factor.^{7,17} No local or systemic etiological factors could be determined in this case, although the lesions might be triggered by the same predisposing factors.

Acknowledgements

The authors wish to thank the Japanese Journal of Pediatric Dentistry for the permission to reproduce Figures 1 and 2a.

References

- Savage NW, Gentner M, Symons AL. Pre-eruptive intracoronal radiolucencies: Review and report of case. *J Dent Child* 1998;65:36-40.
- DeSchepper EJ, Haynes JI, Sabates C. Pre-eruptive radiolucencies of unerupted teeth: Report of a case and literature review. *Quintessence Int* 1988;19:157-60.
- Grundy GE, Pyle RJ, Adkins KF. Intracoronal resorption of unerupted molars. *Aust Dent J* 1984;29:175-9.
- Rankow H, Croll TP, Miller AS. Pre-eruptive idiopathic coronal resorption of permanent teeth in children. *J Endod* 1986;12:36-9.
- Giunta JL, Kaplan MA. "Caries-like" dentin radiolucency of unerupted permanent tooth from developmental defects. *J Pedod* 1981;5:249-55.
- Walton JL. Dentin radiolucencies in unerupted teeth: Report of two cases. *J Dent Child* 1980;47:35-8.
- Rubinstein L, Wood AJ, Camm J. An ectopically impacted premolar with a radiolucent defect. *J Pedod* 1989;14:50-2.
- Moskovitz M, Holan G. Pre-eruptive intracoronal radiolucent defect: A case of a nonprogressive lesion. *J Dent Child* 2004;71:175-8.
- Seow WK, Hackley D. Pre-eruptive resorption of dentin in the primary and permanent dentitions: Case reports and literature review. *Pediatr Dent* 1996;18:67-71.
- Ignelzi MA Jr, Fields HW, White RP, Bergenholz G, Booth FA. Intracoronal radiolucencies within unerupted teeth: Case report and review of literature. *Oral Surg Oral Med Oral Pathol* 1990;70:214-20.
- Brooks JK. Detection of intracoronal resorption in an unerupted developing premolar: Report of a case. *J Am Dent Assoc* 1988;116:857-9.
- Holan G, Eidelman E, Mass S. Pre-eruptive coronal resorption of permanent teeth: Report of three cases and their treatment. *Pediatr Dent* 1994;16:373-6.
- Seow WK. Multiple pre-eruptive intracoronal radiolucent lesions in the permanent dentition: Case report. *Pediatr Dent* 1998;20:195-8.
- Taylor NG, Gravely JF, Hume WJ. Resorption of the crown of an unerupted permanent molar. *Int J Paediatr Dent* 1991;2:89-92.
- Davidovich E, Kreiner B, Peretz B. Treatment of severe pre-eruptive intracoronal resorption of a permanent second molar. *Pediatr Dent* 2005;27:74-7.
- Nik NN, Abul Rahman R. Pre-eruptive intracoronal dentin defects of permanent teeth. *J Clin Pediatr Dent* 2003;27:371-5.
- Seow WK, Lu PC, McAllan LH. Prevalence of pre-eruptive intracoronal dentin defects from panoramic radiographs. *Pediatr Dent* 1999;21:332-9.
- Abe M, Hata H, Mayanagi H. Pre-eruptive idiopathic coronal resorption of permanent teeth in children: Report of two cases. *Jpn J Pediatr Dent* 2001;39:231-7.
- Heithersay GS. Clinical, radiologic, and histopathologic features of invasive cervical resorption. *Quintessence Int* 1999;30:27-37.
- Seow WK, Wan A, McAllan LH. The prevalence of pre-eruptive intracoronal dentin radiolucencies in the permanent dentition. *Pediatr Dent* 1999;21:26-33.
- Fong CD, Davis MJ. Partial pulpotomy for immature permanent teeth, its present and future. *Pediatr Dent* 2002;24:29-32.