



# Comparison of Mineral Trioxide Aggregate and Calcium Hydroxide as Pulpotomy Agents in Young Permanent Teeth (Apexogenesis)

Omar A.S. El Meligy, BDS, MSc, PhD<sup>1</sup> David R. Avery, DDS, MSD<sup>2</sup>

## Abstract

**Purpose:** The purpose of this study was to compare mineral trioxide aggregate (MTA) with calcium hydroxide (Ca(OH)<sub>2</sub>) clinically and radiographically as a pulpotomy agent in immature permanent teeth (apexogenesis).

**Methods:** Fifteen children, each with at least 2 immature permanent teeth requiring pulpotomy (apexogenesis), were selected for this study. All selected teeth were evenly divided into 2 test groups. In group 1, the conventional Ca(OH)<sub>2</sub> pulpotomy (control) was performed, whereas in group 2, the MTA pulpotomy (experimental) was done. The children were recalled for clinical and radiographic evaluations after 3, 6, and 12 months.

**Results:** The follow-up evaluations revealed failure due to pain and swelling detected at 6 and 12 months postoperative evaluations in only 2 teeth treated with Ca(OH)<sub>2</sub>. The remaining 28 teeth appeared to be clinically and radiographically successful 12 months postoperatively. Calcific metamorphosis was a radiographic finding in 2 teeth treated with Ca(OH)<sub>2</sub> and 4 teeth treated with MTA.

**Conclusions:** Mineral trioxide aggregate showed clinical and radiographic success as a pulpotomy agent in immature permanent teeth (apexogenesis) and seems to be a suitable alternative to calcium hydroxide. (Pediatr Dent 2006;28:399-404)

**KEYWORDS:** APEXOGENESIS, MINERAL TRIOXIDE AGGREGATE, MTA

Received September 27, 2005 Revision Accepted May 10, 2006

Although vital pulp capping and pulpotomy procedures of cariously exposed pulps in mature teeth remain controversial, it is universally accepted that vital pulp therapy is the treatment of choice for immature teeth (incompletely developed apices).<sup>1</sup> Such vital pulp therapy, often called apexogenesis, is defined as vital pulp therapy of an immature tooth that permits continued root formation and apical closure.<sup>2</sup>

Calcium hydroxide (Ca(OH)<sub>2</sub>) has been a popular pulpotomy agent for this type of vital pulp therapy and is widely used clinically. It was introduced by Herman as a biologic dressing.<sup>3</sup> Despite its apparent success in vital pulp therapy, considerable confusion and condemnation of this material have long persisted because Ca(OH)<sub>2</sub>—in its pure state and in the original formulations—actually kills a certain amount of tissue when placed in direct contact with the pulp rather than merely functioning as a biologic dressing. Because of its alkalinity (pH of 12), it is so caustic that when placed in

contact with vital pulp tissue, the reaction produces a superficial necrosis of the pulp.<sup>4</sup> Studies have also shown that Ca(OH)<sub>2</sub> is extremely toxic to cells in tissue culture, also it has some tissue altering and dissolving effects.<sup>5-7</sup> Therefore, the search continues for procedures and materials that are more biocompatible while stimulating continued dentin formation and apical closure of immature teeth.

Mineral trioxide aggregate (Pro Root MTA, Tulsa Dental Products, Tulsa, Okla), a newer material currently being used in pulp therapy, has been shown to provide an enhanced nonresorbable seal over the vital pulp.<sup>8,9</sup> MTA was used experimentally for a number of years and was approved for human use by the US Food and Drug Administration in 1998.<sup>10</sup>

MTA is a powder consisting of tricalcium silicate, dicalcium silicate, tricalcium aluminate, calcium sulfate dehydrate, and bismuth oxide.<sup>11</sup> When the material is hydrated, it becomes a colloidal gel that solidifies in approximately 3 hours.<sup>10</sup> It is available in 1 gm packets of MTA powder. The cost of a box of 5 packets, with a carrier included, is approximately \$300.<sup>12</sup>

Like Ca(OH)<sub>2</sub>, MTA also has a high pH (12.5) that causes denaturation of adjacent cells, tissue proteins, and some bacteria in the wound area. As the material sets, how-

<sup>1</sup>Dr. Omar is lecturer, Department of Pediatric Dentistry and Public Health, Faculty of Dentistry, Alexandria University, Alexandria, Egypt; <sup>2</sup>Dr. Avery is the Ralph E. McDonald Professor of Pediatric Dentistry Emeritus, School of Dentistry, Indiana University, Indianapolis, Indiana.  
Correspond with Dr. Omar at oelmeligy@dataxprs.com.eg

ever, the pH changes and the cell injuries subside.<sup>13</sup> The set material has low solubility and a radiopacity slightly greater than that of dentin.<sup>14</sup> MTA (Dentsply Caulk, Milford, Del) has been found to have a set compressive strength of about 70 MPa. This is approximately equal to that of IRM, but much less than amalgam (311 MPa).<sup>9,14</sup>

MTA has been shown to have superior sealing ability to amalgam, zinc oxide-eugenol, or IRM.<sup>15,16</sup> Recent investigations using MTA as a direct pulp capping material seemed to stimulate natural dentin repair at pulpal exposure sites.<sup>9,17,18</sup> It was also found to produce less inflammation and better dentin bridge formation when compared with Ca(OH)<sub>2</sub> in monkeys.<sup>15</sup>

MTA was found to be biocompatible when implanted into guinea pigs, dogs, and monkeys, and was more biocompatible than amalgam, Super-EBA (Harry J. Bosworth Co, Skokie, Ill), and IRM.<sup>19-21</sup> In animal studies, MTA was the only material that allowed cementum overgrowth.<sup>20,22</sup> In vitro studies of human osteoblasts showed that MTA stimulated cytokine release and interleukin production.<sup>23,24</sup> MTA has been also found to be nonmutagenic and less cytotoxic than Super-EBA and IRM.<sup>25,26</sup>

The setting ability of MTA is uninhibited by blood or water.<sup>27</sup> In fact, Arens and Torabinejad have recommended covering MTA with a wet cotton pellet and IRM to gain a better setting of the material.<sup>28</sup>

MTA has been used to manage many clinical problems, including: (1) successful pulp caps; (2) pulpotomies; (3) apexifications; (4) root perforations repairs (surgical and nonsurgical); and (5) root-end filings.<sup>9,10</sup> In all cases, MTA allowed bone healing and elimination of clinical symptoms. MTA showed high clinical and radiographic success rates as a pulpotomy dressing in immature permanent teeth.<sup>29-31</sup> MTA performed well as a pulpotomy agent, causing dentin bridge formation while simultaneously maintaining normal pulpal histology.<sup>31,32</sup>

The treatment of pulpal injury during the period of root maturation provides a significant challenge for the clinician. Depending on the vitality of the affected pulp, apexogenesis or apexification may be considered. Apexogenesis is "a vital pulp therapy procedure performed to encourage continued physiological development and formation of the root end." Apexification is "a method to induce a calcified barrier in a root with an open apex or the continued apical development of an incomplete root in a tooth with a necrotic pulp."<sup>33</sup>

The purpose of this study was to compare mineral trioxide aggregate with calcium hydroxide as a pulpotomy agent in immature permanent teeth. Postoperative clinical and radiographic evaluations of the treated teeth were conducted to make the comparison of the results with each agent.

## Methods

This study was carried out on 30 traumatized or carious young permanent teeth of 15 children ranging in age from 6 to 12 years. The sample included 4 traumatized central

incisors, 2 carious premolars, and 24 carious first molars. These children were selected from the Pediatric Dental Clinic at the Faculty of Dentistry, Alexandria University, Alexandria, Egypt. They were invited to participate over a period of 12 months. Each child had at least 2 contralateral qualifying teeth. The children were healthy and cooperative. Prior to treatment, an appropriate informed consent was obtained from the parents. This study was conducted in compliance with all policies of appropriate patient care at Alexandria University.

All patients selected for this study were free from any systemic diseases. Each tooth chosen for pulpotomy (apexogenesis) met the following criteria<sup>2</sup>:

1. The tooth was immature with incomplete root formation and damage to the coronal pulp, but with a presumed healthy radicular pulp.
2. The crown was fairly intact and restorable.
3. There was no clinical evidence of extensive pulp degeneration or periapical pathology, including spontaneous throbbing pain, tenderness to percussion, tooth mobility, swelling, or fistulous tract.
4. There was no radiographic evidence of periapical pathology or inter-radicular bone loss, internal resorption, pulp calcification, ankylosis, or pathologic external root resorption.

Preoperative periapical radiographs of the teeth considered for treatment in the study were made using the XCP extension cone paralleling technique (Dentsply Rinn, Elgin, Ill).<sup>34</sup> The selected teeth were randomly assigned and divided into 2 test groups. Group 1 included 15 teeth treated with Ca(OH)<sub>2</sub> (control group). Group 2 included 15 teeth treated with MTA (experimental group). Each child received both treatments, Ca(OH)<sub>2</sub> on one side of the mouth and MTA on the other side of the mouth.

For both groups the following pulpotomy technique was followed<sup>2</sup>:

1. After local anesthesia and rubber dam isolation, a conventional access cavity was made with a high-speed bur using copious water spray.
2. Strands of pulp and debris were removed coronal to the amputation site. Amputation of the coronal pulp at the cervical level was performed with a sharp spoon excavator or a large sterile round bur.
3. Bleeding of the pulp stump was controlled with saline on a cotton pellet applied with gentle pressure.

For group 1 (calcium hydroxide): Ca(OH)<sub>2</sub> powder was mixed with saline to a thick consistency. The paste was carefully placed on the pulp stump surface 1 to 2 mm thick. A layer of zinc oxide-eugenol cement was placed over the Ca(OH)<sub>2</sub> to protect it against leakage and to provide a rigid base prior to final restoration. Anterior teeth were restored with bonded composite resin. Posterior teeth were restored with amalgam.

For group 2 (MTA): The MTA powder was mixed with sterile water according to the manufacturer's directions. The

**Table 1. No. of Teeth Exhibiting Clinical Findings in the 2 Groups**

Posttreatment interval (mos)	Clinical findings					
	History of pain		Swelling		Sinus tract	
	G1*	G2†	G1*	G2†	G1*	G2†
3	0	0	0	0	0	0
6	0	0	0	0	0	0
12	2	0	2	0	0	0

\*G1: Ca(OH)<sub>2</sub> apexogenesis.

†G2: MTA apexogenesis.

**Table 2. No. of Teeth Exhibiting Radiographic Findings in the 2 Groups**

Posttreatment interval (mos)	Radiographic findings							
	Widened PDL		Periapical radiolucency		Internal or external root resorption		Root growth and canal narrowing	
	G1*	G2†	G1*	G2†	G1*	G2†	G1*	G2†
3	0	0	0	0	0	0	NA‡	NA‡
6	0	0	0	0	0	0	NA‡	NA‡
12	2	0	2	0	0	0	13	15

\*G1: Ca(OH)<sub>2</sub> apexogenesis.

†G2: MTA apexogenesis.

‡NA: No assessment.

mixture was placed on the pulp stump surface and patted with a moist cotton pellet. A damp cotton pellet was placed over the material, and the remaining cavity was filled with fortified zinc oxide-eugenol cement (IRM). After a week, the IRM and the cotton pellet were removed and a final restoration was placed over set MTA (bonded composite for anterior teeth and amalgam for posterior teeth). The same operator provided these treatments to all 15 patients in this study.

The children were recalled for clinical and radiographic evaluations after 3, 6, and 12 months. Two examiners, who were blinded to treatment type, evaluated the teeth clinically and radiographically. The examiners were faculty from the Department of Pediatric Dentistry and Public Health, Alexandria University.

The treatment was considered successful:

1. clinically if there were no signs or symptoms of pulp or periapical disease (no history of pain and no clinical evidence of swelling or sinus tract); and
2. radiographically if there was continued growth of the root and canal narrowing, and no widened periodontal ligament, no periapical radiolucency and no internal or external root resorption.<sup>2</sup>

If calcific metamorphosis occurred, it was noted but not regarded as a treatment failure.

The clinical and radiographic data for the 2 groups were statistically analyzed using the chi-square test.

## Results

All 30 teeth were available for examination at each of the 3-, 6-, and 12-month evaluations. This study's results are divided into: (1) clinical findings; and (2) radiographic findings.

### Clinical findings

Table 1 shows the clinical findings of the 2 groups during the follow-up period.

After 3 and 6 months, no clinical signs or symptoms of failure were observed in either of the 2 groups. After 12 months follow-up, 2 teeth in group 1 had a history of pain, as reported by the patient, and swelling of tissues associated with these teeth was noted during the clinical exam. In group 2, all 15 teeth were free of any clinical signs and symptoms. At the end of the study, 2 teeth in group 1 were considered to be clinical failures.

### Radiographic findings

Table 2 shows the radiographic findings of the 2 groups during the follow-up period. After 3 and 6 months, no radiographic signs of failure were observed in any teeth of the 2 groups. After 12 months follow-up, 2 teeth in group 1 showed widening of lamina dura and periapical radiolucency. In group 2, the periradicular condition of all teeth appeared normal after 12 months. Calcific metamorphosis, though not a criterion for success or failure, was a radiographic finding in 2 teeth treated with Ca(OH)<sub>2</sub> and 4 teeth treated with MTA. At the end of the study, 2 teeth in group 1 were considered to be radiographic failures (same 2 teeth that were clinical failures).

The examiners agreed that assessing root growth and canal narrowing could not be reliably determined by observing the radiographs at the 3- and 6-month observation periods, even though no adverse radiographic signs were noted for these periods. Therefore, assessing the radiographic evidence for root growth and canal narrowing was recorded only at the 12-month evaluations. After 12 months, 13 teeth in group 1 and all 15 teeth in group 2 demonstrated continued root growth and canal narrowing comparable to normal tooth maturation.

### Clinical and radiographic success rates

The 4 traumatized maxillary central incisors were treated successfully with both materials (2 teeth treated with Ca(OH)<sub>2</sub> and 2 teeth treated with MTA). Twenty-four of

the 26 carious posterior teeth were also treated successfully with the 2 pulpotomy agents (11 teeth treated with  $\text{Ca}(\text{OH})_2$  and 13 teeth treated with MTA). Only 2 posterior teeth treated with  $\text{Ca}(\text{OH})_2$  were considered failures at the study's end. There were no disagreements between the examiners' evaluations throughout the study.

The clinical and radiographic success rates for the  $\text{Ca}(\text{OH})_2$  and MTA groups were 87% and 100%, respectively. Figures 1 to 3 show radiographs of 1 successful case for each of the 2 groups. There was no statistically significant difference between the 2 groups, either clinically or radiographically, using the chi-square test (chi-square=2.14;  $P=.16$ ).

### Discussion

This study examined the clinical and radiographic success rates of permanent tooth pulpotomies with MTA, a material with evidence-based success in many endodontic procedures. Several *in vitro* and *in vivo* studies have shown that MTA:

1. prevents microleakage;
2. is biocompatible and nonresorbable;
3. has low solubility and high compressive strength; and
4. promotes tissue regeneration when it is placed in contact with dental pulp or periradicular tissues.<sup>9,15,16,29,30</sup>

Using MTA as a pulpotomy agent, however, is somewhat expensive. One suggestion to improve the cost effectiveness of using MTA is to carefully store unused portions of the powder from an opened packet in sterilized empty film canisters to keep it fresh and prevent hydration.<sup>12</sup>

Another noteworthy point when using MTA is that it needs to cure completely before placing a definitive restoration on the treated tooth. Therefore it is necessary to schedule 2 treatment appointments relatively close together: the first to perform the pulpotomy and place the MTA, and the second to complete the tooth restoration after the MTA has cured.<sup>29</sup>

$\text{Ca}(\text{OH})_2$  was selected as the control pulpotomy agent because it is currently considered the standard therapeutic

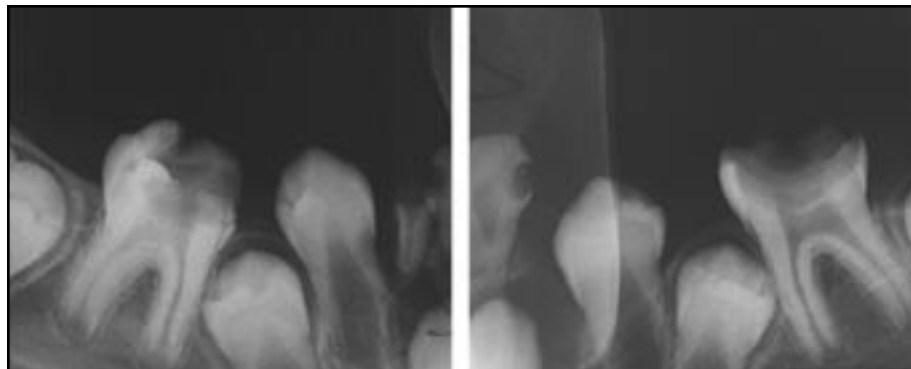


Figure 1. Preoperative periapical radiographs showing carious mandibular permanent first molars with open apices.

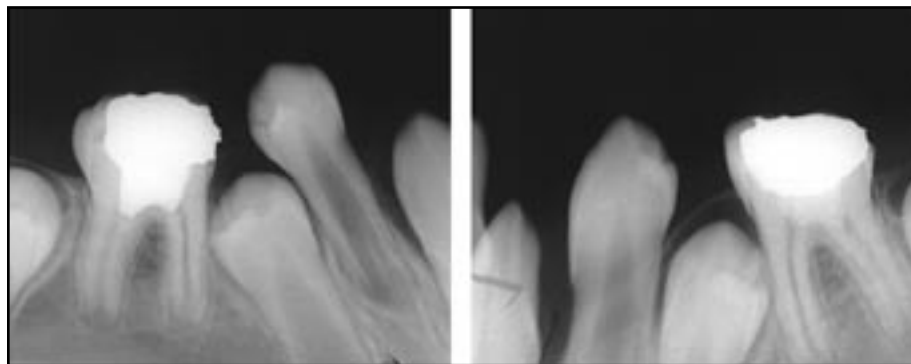


Figure 2. The same teeth 3 months after initiating apexogenesis. The mandibular right molar was treated with MTA (on left) and the mandibular left molar was treated with  $\text{Ca}(\text{OH})_2$ . There were no signs of failure in either tooth.

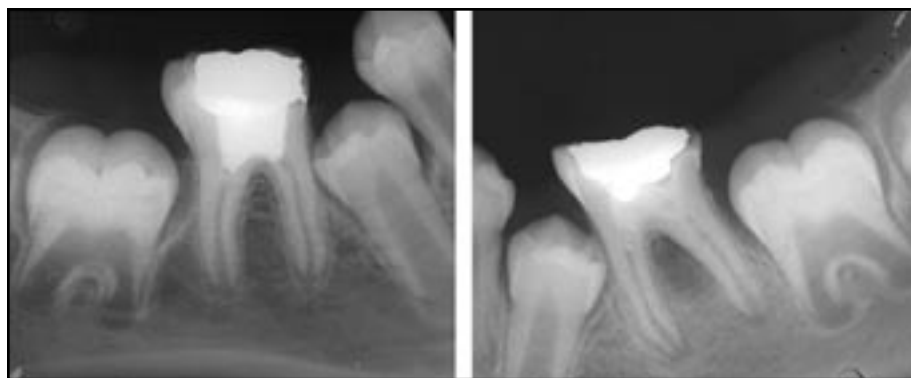


Figure 3. The same teeth 12 months postoperatively. Notice continued normal root development in both teeth.

agent for apexogenesis procedures in immature permanent teeth.  $\text{Ca}(\text{OH})_2$  has a long and proven record as an effective pulp therapy agent, including pulpotomies, and it is not expensive. On the other hand,  $\text{Ca}(\text{OH})_2$  has high solubility and low strength.  $\text{Ca}(\text{OH})_2$  has been reported to produce more inflammation and lower quality bridge formation when compared to MTA in monkeys and dogs.<sup>15,17</sup> Similar results were found when human third molars were used to compare the effect of pulp capping with MTA and  $\text{Ca}(\text{OH})_2$ .<sup>18</sup>

This study's  $\text{Ca}(\text{OH})_2$  group showed 2 teeth with pathologic signs and symptoms and they were regarded as failures

at the 12-month evaluation. Walton and Torabinejad believe that failure usually results from bacterial contamination through microleakage around the restoration and through the porous bridge at the pulpotomy site.<sup>2</sup> Ca(OH)<sub>2</sub> offers no protection against microleakage, while MTA remains stable and resists microleakage after it sets.<sup>29</sup>

Calcific metamorphosis was the most common noteworthy radiographic finding in both groups in this study, although it is not considered a criterion for success or failure in the treated teeth. It results from vigorous odontoblastic activity and indicates pulpal vitality. Calcific metamorphosis is a common radiographic finding in pulpotomized teeth. In the present study, it was observed in 2 teeth treated with Ca(OH)<sub>2</sub> and in 4 teeth treated with MTA. Observing calcific metamorphosis in a portion of this study's sample was not surprising, since both materials are known to promote hard tissue formation.

This study's success rate of MTA was excellent. All 15 teeth in the experimental group were completely successful after 12 months, compared to 13 of 15 in the control group. Future material development may be expected to result in faster curing MTA. Further studies with a larger sample size and longer follow-up periods are recommended.

### Conclusions

Based on this study's results, the following conclusions can be made:

1. After a 12-month postoperative period, mineral trioxide aggregate (MTA) proved very effective as a successful pulpotomy agent for apexogenesis in young permanent teeth.
2. MTA is a suitable replacement for calcium hydroxide as a pulpotomy agent for the apexogenesis procedure.
3. There was no statistically significant difference in the 2 treatment groups.

### Acknowledgements

This study was partially supported by the Zawawi Pediatric Dentistry Fund of the Indiana University Foundation.

### References

1. Fong CD, Davis MJ. Partial pulpotomy for immature permanent teeth: Its present and future. *Pediatr Dent* 2002;24:29-32.
2. Walton RE, Torabinejad M. Management of incompletely formed roots. In: *Principles and Practice of Endodontics*. 3<sup>rd</sup> ed. Philadelphia, Pa: WB Saunders; 2002:388-404.
3. Herman B. *Biologische Wurzelbehandlung*, Frankfurt, Germany: W. Kramer; 1936.
4. McDonald RE, Avery DR, Dean JA. Treatment of deep caries, vital pulp exposure and pulpless teeth. In: *Dentistry for the Child and Adolescent*. 8<sup>th</sup> ed. St. Louis, Mo: Mosby Co; 2004:389-412.
5. Anusavice KJ. Biocompatibility of dental materials. In: *Phillip's Science of Dental Materials*. 10<sup>th</sup> ed. Philadelphia, Pa: WB Saunders; 1996:57-110.

6. Andersen M, Lund A, Andreasen JO, Andreasen FM. In vitro solubility of human pulp tissue in calcium hydroxide and sodium hypochlorite. *Endod Dent Traumatol* 1992;8:104-8.
7. Barnes IE, Kidd EA. Disappearing dycal. *Br Dent J* 1979;147:111.
8. Holland R, de Souza V, Nery MJ, Otoboni Filho JA, Bernabe PF, Dezan JE. Reaction of rat connective tissue to implanted dentin tubes filled with mineral trioxide aggregate or calcium hydroxide. *J Endod* 1999;25:161-6.
9. Torabinejad M, Chivian N. Clinical applications of mineral trioxide aggregate. *J Endod* 1999;25:197-205.
10. Schwartz RS, Mauger M, Clement DJ, Walker WA, III. Mineral trioxide aggregate: A new material for endodontics. *J Am Dent Assoc* 1999;130:967-75.
11. Dentsply. [material safety data sheet]. White ProRoot MTA root canal repair material. Tulsa, Okla: Tulsa Dental; 2001.
12. Schmitt D, Lee J, Bogen G. Multifaceted use of Pro-Root MTA root canal repair material. *Pediatr Dent* 2001;23:326-30.
13. Saidon J, He J, Zhu Q, Safavi K, Spangberg LSW. Cell and tissue reactions to mineral trioxide aggregate and Portland cement. *Oral Surg Oral Med Oral Pathol Oral Radiol Endod* 2003;95:483-9.
14. Torabinejad M, Hong CU, McDonald F, Pitt Ford TR. Physical and chemical properties of a new root-end filling material. *J Endod* 1995;21:349-53.
15. Pitt Ford T, Torabinejad M, Abedi H, Kariyawasam S. Using mineral trioxide aggregate as a pulp-capping material. *J Am Dent Assoc* 1996;127:1491-4.
16. Sluyk SR, Moon PC, Hartwell GR. Evaluation of setting properties and retention characteristics of mineral trioxide aggregate when used as a furcation perforation repair material. *J Endod* 1998;24:768-71.
17. Faraco IM Jr, Holland R. Response of the pulp of dogs to capping with mineral trioxide aggregate or a calcium hydroxide cement. *Dent Traumatol* 2001;17:163-6.
18. Aeinehchi M, Eslami B, Ghanbariha M, Saffar AS. Mineral trioxide aggregate (MTA) and calcium hydroxide as pulp-capping agents in human teeth: A preliminary report. *Int Endod J* 2003;36:225-31.
19. Torabinejad M, Hong CU, Pitt Ford TR, Kariyawasam SP. Tissue reaction to implanted super-EBA and mineral trioxide aggregate in the mandible of guinea pigs: A preliminary report. *J Endod* 1995;21:569-71.
20. Torabinejad M, Hong CU, Lee SJ, Monsef M, Pitt Ford TR. Investigation of mineral trioxide aggregate for root-end filling in dogs. *J Endod* 1995;21:603-8.
21. Torabinejad M, Pitt Ford TR, McKendry DJ, Abedi HR, Miller DA, Kariyawasam SP. Histologic assessment of MTA as a root-end filling in monkeys. *J Endod* 1997;23:225-8.
22. Pitt Ford TR, Torabinejad M, McKendry DJ, Hong CU, Kariyawasam SP. Use of mineral trioxide aggregate

- for repair of furcal perforations. *Oral Surg Oral Med Oral Pathol* 1995;79:756-63.
23. Koh ET, Pitt Ford TR, Torabinejad M, McDonald F. Mineral trioxide aggregate stimulates cytokine production in human osteoblasts. *J Bone Miner Res* 1995;10S:S406.
  24. Koh ET, McDonald F, Pitt Ford TR, Torabinejad M. Cellular response to mineral trioxide aggregate. *J Endod* 1998;24:543-7.
  25. Kettering JD, Torabinejad M. Investigation of mutagenicity of mineral trioxide aggregate and other commonly used root-end filling materials. *J Endod* 1995;21:537-42.
  26. Torabinejad M, Hong CU, Pitt Ford TR, Kettering JD. Cytotoxicity of four root-end filling materials. *J Endod* 1995;21:489-92.
  27. Torabinejad M, Higa RK, McKendry DJ, Pitt Ford TR. Dye leakage of four root-end filling materials: Effects of blood contamination. *J Endod* 1994;20:159-63.
  28. Arens D, Torabinejad M. Repair of furcal perforations with mineral trioxide aggregate: Two case reports. *Oral Surg Oral Med Oral Pathol Oral Radiol Endod* 1996;82:84-8.
  29. Bakland LK. Management of traumatically injured pulps in immature teeth using MTA. *J Calif Dent Assoc* 2000;28:855-8.
  30. Banchs F, Trope M. Revascularization of immature permanent teeth with apical periodontitis: New treatment protocol. *J Endod* 2004;30:196-200.
  31. Koh ET, Pitt Ford TR, Kariyawasam SP, Chen NN, Torabinejad M. Prophylactic treatment of dens evaginatus using mineral trioxide aggregate. *J Endod* 2001;27:540-2.
  32. Salako N, Joseph B, Ritwik P, Salonen J, John P, Junaid TA. Comparison of bioactive glass, mineral trioxide aggregate, ferric sulfate, and formocresol as pulpotomy agents in rat molar. *Dent Traumatol* 2003;19:314-20.
  33. American Association of Endodontics. *Glossary of Endodontic Terms*. 7<sup>th</sup> ed. Chicago, Ill: AAE; 2003.
  34. Rinn Corporation: *Intraoral Radiography With Rinn XCP/BAI Instruments*. Elgin, Ill: Rinn Corp; 1989.

## Abstract of the Scientific Literature



### Association Between Disability and Child Abuse and Neglect

This is the first whole-population-based study to report on the relationship of disability to reports of child abuse. The study concluded that children with disabling conditions seem to be at increased risk of child abuse and neglect. There was a strong association between reports of child abuse and neglect and conditions such as conduct disorder and learning difficulties. This outcome was anticipated, since these conditions share a common etiologic pathway with child abuse and neglect. The study does not necessarily support the view that disability predisposes one to child abuse. Rather, reverse causation and common etiologic pathways with abuse were noted as probable factors.

**Comments:** There was a strong association between learning disability and conduct disorder with all types of child abuse, but sexual abuse in particular. Children with cerebral palsy were associated with increased reports of physical abuse and neglect. Children with nonconduct psychological disorders and those with speech and language disorders appear to be at increased risk of reports of physical, emotional, and neglect categories, but not in the sexual abuse category. There was no evidence noted of a reduced threshold for reporting of parents/guardians of disabled children for child abuse and neglect. Although dental practitioners assess all patients for potential signs of child abuse and neglect, it appears that children with specific disabilities may be at greater risk of specific types of child abuse and neglect. **GEM**

*Address correspondence to Stuart Logan, FRCPCH, Institute of Health and Social Care Research, Peninsula Medical School, Exeter, UK.*

**Spencer N, et al. Disabling conditions and registration for child abuse and neglect: A population-based study. *Pediatrics* 2005;116:609-613.**

19 references