

Conference Paper



Contemporary Perspectives on Vital Pulp Therapy: Views From the Endodontists and Pediatric Dentists

N. Sue Seale, DDS, MSD¹ • Gerald N. Glickman, DDS, MS²

Abstract: *The purpose of this study was to determine the level of agreement between pediatric dentists and endodontists at a pulp therapy symposium conjointly sponsored by the American Association of Endodontists (AAE) and the American Academy of Pediatric Dentistry (AAPD) on November 2–3, 2007. Presymposium and postsymposium tests were administered, and respondent answers were compared between pediatric dentists and endodontists. Opinions on 3 areas were sought: pulp therapy for cariously involved primary teeth; indirect pulp treatment (IPT) for cariously involved immature permanent teeth; and innovative treatment options including pulpal revascularization and regeneration. Results were analyzed with χ^2 tests. Comparisons of presymposium and postsymposium responses and between the 2 groups of attendees indicated that the pediatric dentistry and endodontic communities agree that formocresol will be replaced as a primary tooth pulpotomy agent, that mineral trioxide is the first choice to take its place, that IPT in primary teeth holds hope as a replacement for pulpotomy, and that IPT is an acceptable pulp therapy technique for cariously involved young permanent teeth. Both groups believe that pulp revascularization and regeneration will be viable treatment modalities in the future. The AAE and the AAPD are positioned to begin preparation of best practice guidelines that share common language and treatment recommendations for pulp therapies performed by both specialties. (Pediatr Dent 2008;30:261-7)*

KEYWORDS: INDIRECT PULP CAPPING, PULP THERAPY, PULPOTOMY

This symposium was intended to bring together 2 different disciplines, pediatric dentistry and endodontics, to hear and evaluate the best evidence surrounding the pulpal therapy treatments they commonly perform. One anticipated outcome of the symposium was to begin preparation for working together to produce best practice guidelines that share common language and treatment recommendations. Such an outcome would require both disciplines to agree with interpretation of the evidence presented concerning the shared treatments.

Because this was the first such endeavor to bring these 2 specialties together, it was anticipated that there would be a diverse cross-section of opinions, both within each individual specialty and across the 2 specialties. Therefore, the planning committee sought to determine, through a brief pretest administered before the first speaker, the baseline opinions of the attendees concerning the various topics to be presented. The planning committee also needed to determine what effect, if any, the conference presentations had on attendees' opinions,

specifically regarding reaching agreements on the evidence presented to support the treatments being discussed. To that end, a more in-depth post-test was created and administered to the attendees via a real-time electronic audience response system (ARS).

The purpose of this article was to present the results of the opinion surveys and report the current status of agreement of the 2 specialties concerning the 3 major areas of interest: pulp therapy for the cariously involved primary tooth; indirect pulp treatment (IPT) for the cariously involved, immature permanent tooth; and innovative treatment options including pulpal revascularization and pulpal regeneration, both currently under investigation.

Methods

An 8-question pretest was prepared and administered to attendees before the first presentation. The first 3 questions asked for demographic data, including dental discipline, age, and current situation (pediatric or endodontic practitioner, pediatric or endodontic resident, or academician). Five additional questions used a 5-point Likert scale with the choices of strongly agree, agree, neutral, disagree, and strongly disagree and queried about primary tooth pulpotomy and primary and permanent tooth IPT. Frequency tables of responses to the pretest questions were calculated for all respondents and compared by discipline, age

¹Dr. Seale is Regents Professor and chairman, Department of Pediatric Dentistry, and ²Dr. Glickman is professor and chairman, Department of Endodontics, both at the Baylor College of Dentistry, Texas A&M University Health Science Center, Dallas, Texas.

Correspond with Dr. Seale at sseale@bcd.tamhsc.edu

group, and current career position by using χ^2 analysis, with a significance level of $P < .05$.

After the last speaker, a more detailed set of 20 questions about the same topics was presented to the audience for their opinion via an electronic ARS. The same 3 demographic questions that were asked in the pretest were repeated, so that attendees' responses could be identified by discipline, age group, and current career position. Additional questions used the Likert scale or allowed the attendees to choose a single best answer from a list of options and patient scenarios. Six questions addressed primary tooth pulpotomy, including medicament choice and opinions about formocresol as a primary tooth pulpotomy agent. Four questions asked for opinions about indirect pulp capping (IPC)/stepwise excavation in primary teeth, and an additional 5 questions asked about the same procedure in permanent teeth. Five questions addressed pulpal revascularization and the potential for stem cell research for pulpal regeneration. Frequency tables of responses to the ARS questions were calculated for all respondents and compared by discipline (pediatric dentist or endodontist) by using χ^2 analysis, with a significance level of $P < .05$.

Results

A total of 376 individuals provided responses, and they were divided as follows: 79 endodontists, 23 endodontic residents, 231 pediatric dentists, 21 pediatric dental residents, and 22 other. The numbers of residents and nonspecialists were small. Therefore, χ^2 analyses were only performed on responses from pediatric dentists and endodontists.

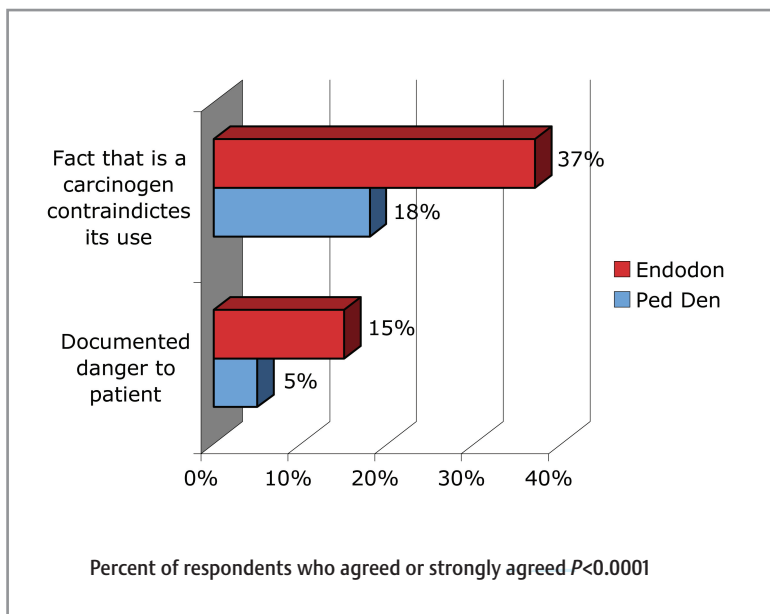


Figure 1. Comparison by specialty of responses to the statements: The fact that formocresol is a potential carcinogen should contraindicate its future usage in pediatric pulp therapy; and when used as a primary tooth pulpotomy agent, formocresol presents a documented danger to the patient.

One of the major areas addressed by the speakers was pulp treatment for the cariously involved primary tooth. Issues covered included the controversy surrounding the use of formocresol as a pulpotomy agent in primary teeth and the level of evidence supporting either discontinuing its use or maintaining it as a viable pulpotomy agent; the status of different pulpotomy agents for primary teeth and the level of evidence that supports them; and the use of IPT as an alternative to pulpotomy for cariously involved primary teeth.

Pretest responses concerning the acceptability of formocresol as a contemporary technique for primary tooth pulpotomy were significantly more positive ($P < .001$) from pediatric dentists, with 80% agreeing or strongly agreeing compared with only 29% of endodontists. Three of the postseminar ARS questions revisited this issue, primarily concerning formocresol's safety. When attendees were asked to respond to the statement "formocresol, when used as a primary tooth pulpotomy agent, presents documented danger to the patient," pediatric dentists (5%) were significantly ($P < .001$) less likely than endodontists (15%) to agree or strongly agree. When asked whether the fact that formocresol is a potential carcinogen should contraindicate its future usage in pediatric pulp therapy, however, 18% of pediatric dentists agreed or strongly agreed, compared with 37% of endodontists. Again, these differences were significant ($P < .001$; Fig. 1). Attendees were asked their opinion about the statement "formocresol will be replaced as a primary tooth pulpotomy agent, not because of its danger to patients, but because there is much controversy about its potential to be dangerous." Pediatric dentists and endodontists were unified in their opinions, with 78% and 76%, respectively, agreeing or strongly agreeing.

Pulpotomy agents or treatment alternatives for cariously involved primary teeth were addressed in 2 post-symposium ARS questions. Attendees were asked to give their opinions of the best treatment for a reversibly inflamed primary molar with a large carious lesion encroaching on the pulp. They did this by choosing from a list that included an IPT or a pulpotomy with formocresol, ferric sulfate, mineral trioxide aggregate (MTA), or sodium hypochlorite. MTA was the favorite pulpotomy agent, chosen most often by both pediatric dentists (30%) and endodontists (34%), whereas 20% of pediatric dentists and 4% of endodontists chose formocresol. The second question dealt with choices of agents for pulpotomy and asked, "If cost were not an issue, which is the recommended medicament for pulpoto-mies in primary teeth?" MTA was the overwhelming winner, with pediatric dentists and endodontists in agreement, choosing it 85% of the time. Only 15% of pediatric dentists and 3% of endodontists chose formocresol (Fig. 2).

IPT in primary teeth was addressed in the pretest by asking attendees whether IPT was an acceptable

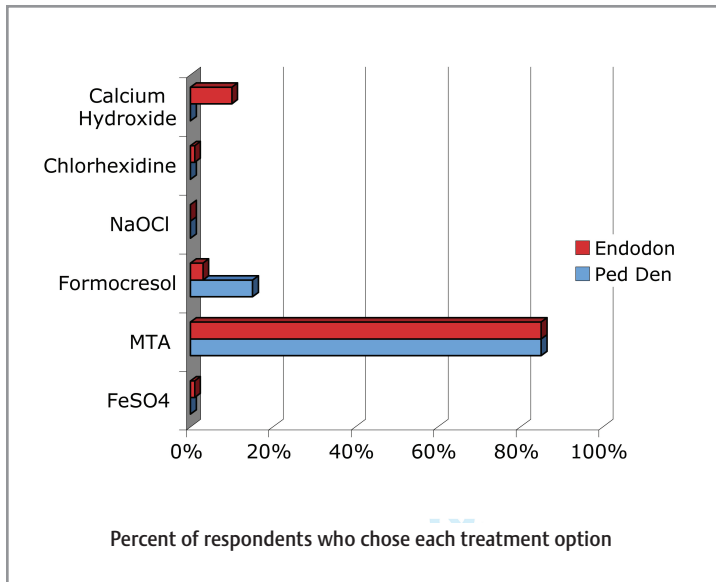


Figure 2. Comparison by specialty of responses to the question: If cost were not an issue, which is the recommended medicament for primary tooth pulpotomy?

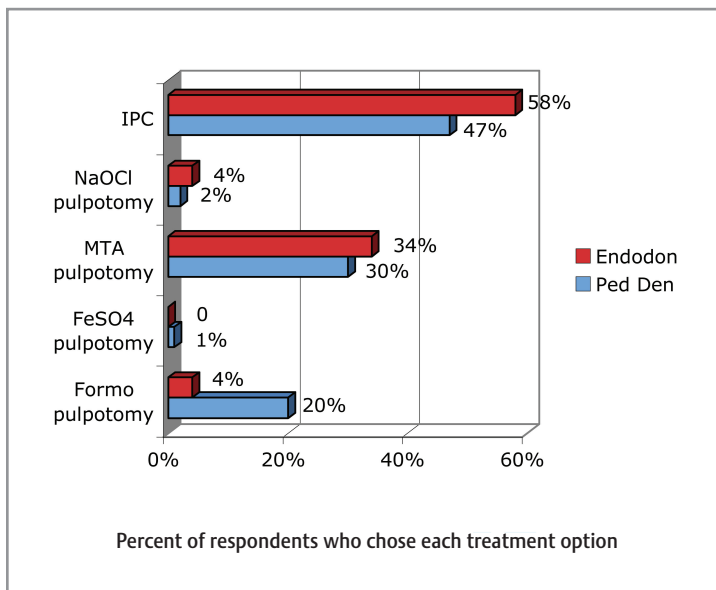


Figure 3. Comparison by specialty of responses to the question: Which is the best treatment choice for a reversibly inflamed primary molar with a large carious lesion encroaching on the pulp?

substitute technique to replace pulpotomy to maintain vitality of cariously involved primary teeth. Endodontists were significantly ($P=.003$) more likely at 47% to agree or strongly agree, compared with pediatric dentists (32%). The post-symposium ARS used 5 questions to further explore opinions of attendees concerning the subject of IPT in primary teeth. IPT was offered as a treatment option in cariously involved primary teeth in a question that asked attendees to choose

from a list the best treatment for a reversibly inflamed primary molar with a large carious lesion encroaching on the pulp. Forty-seven percent of pediatric dentists and 58% of endodontists chose IPT (Fig. 3).

A second question asked attendees to respond to the statement “there is convincing evidence that IPT is as successful as a pulpotomy in primary teeth with reversible pulpitis.” Seventy-four percent of pediatric dentists and 70% of endodontists agreed or strongly agreed. When asked to respond to the statement “there is convincing evidence that primary teeth with reversible pulpitis should all be treated by step-wise excavation for 3 months and only receive a pulpotomy if exposure occurs on re-entry to remove remaining caries,” attendees were divided in their opinions. Forty percent of pediatric dentists and 63% of endodontists agreed or strongly agreed. A scenario question asked what they would do for a 5-year-old child with a second primary molar in which they had removed nearly all of the decay, knowing that if they removed the remaining decay, a pulp exposure would be imminent. More than half of the pediatric dentists (55%) and 71% of endodontists would stop caries removal and do an IPT.

The final question about IPT in primary teeth in the post-symposium ARS asked attendees to choose from a list their main reason for not performing an IPT in a primary tooth with reversible pulpitis. The most frequently chosen answers in descending order by pediatric dentists were “pulpotomy is supported by evidence to have a better, more predictable outcome” (40%), “there is inadequate reimbursement by third party payers for the procedure” (32%), “there is insufficient evidence to support its efficacy and success” (19%), and “I don’t believe IPT is successful in primary teeth” (9%). Endodontists had slightly different rankings of their choices, with “there is inadequate reimbursement by third party payers for the procedure” (35%), “pulpotomy is supported by evidence to have a better, more predictable outcome” (28%), “there is insufficient evidence to support its efficacy and success” (18%), and “I don’t believe IPT is successful in primary teeth” (20%) (Fig. 4).

A second major area addressed by the speakers was management of the carious lesion encroaching on the pulp of an immature permanent tooth, including those with an open apex. Two pretest questions dealt with attendees’ opinions about IPT for these teeth. The first asked for reactions to the statement “indirect pulp capping is an acceptable contemporary technique for maintaining the vitality of asymptomatic, cariously involved young permanent teeth.” Pediatric dentists were overwhelmingly positive and significantly ($P<.001$) more likely at 94% to agree or strongly agree, compared with endodontists (69%).

The second pretest question asked for reactions to the statement “symptoms of reversible pulpitis are contraindications to

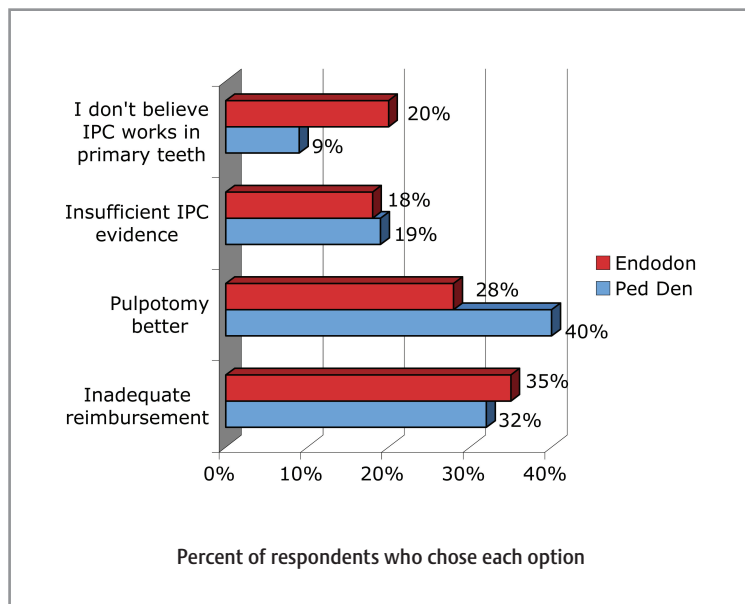


Figure 4. Comparison by specialty of responses to the statement: My main reason for not performing a pulpotomy in a primary tooth with reversible pulpitis.

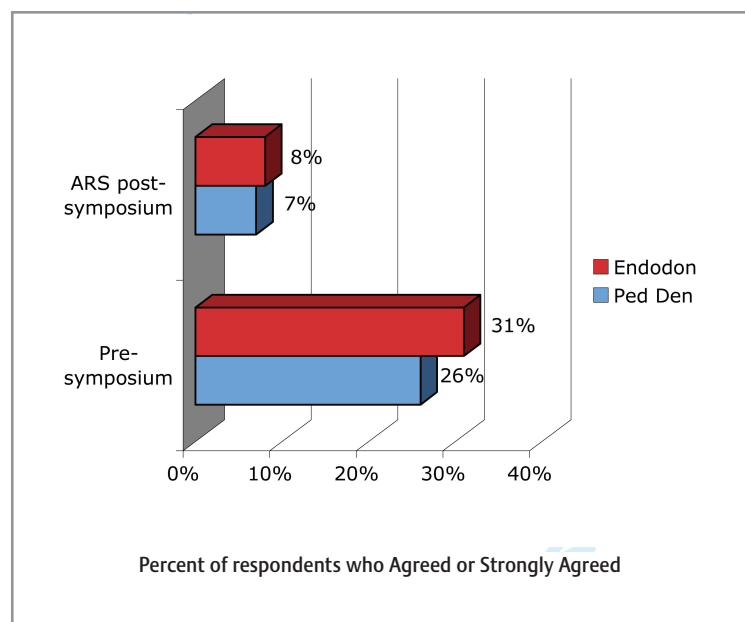


Figure 5. Comparison by specialty of presymposium and postsymposium responses to statement: Symptoms of reversible pulpitis are contraindications to IPT in young permanent teeth with open apices.

IPT in young permanent teeth.” Endodontists were significantly ($P=.02$) more likely to agree or strongly agree at 31% than pediatric dentists at 26%. The post-symposium ARS used the exact same question to assess opinions after the presentations, and there was a significant difference in how the attendees responded to this question by the end of the conference. When the endodontists’ pretest responses (31%)

were compared with their ARS responses, significantly fewer ($P=.001$) agreed or strongly agreed (8%) that symptoms of reversible pulpitis were a contraindication to IPT. The same trend was true for pediatric dentists, with significantly fewer ($P<.001$) at 7% agreeing or strongly agreeing that symptoms of reversible pulpitis were a contraindication to IPT, compared with their pretest responses (26%) (Fig. 5).

Additional post-symposium ARS questions asked attendees’ opinions of the stepwise, 2-appointment version of IPT in permanent teeth. One question asked about agreement with “step-wise excavation as a practical treatment modality for IPT in young permanent teeth.” Pediatric dentists were significantly ($P<.03$) more likely to agree or strongly agree at 71%, compared with 59% of endodontists. Another question asked attendees to choose from a list their main reason for not performing stepwise excavation in a permanent tooth with an open apex. Pediatric dentists chose in descending order: patient compliance for 2 appointments might be questionable (52%); MTA pulpotomy is supported by evidence to have a better outcome (20%); there is more evidence to support the efficacy of the 1-step indirect pulp cap (18%); and inadequate reimbursement by third party payers for the procedure (10%). Endodontists expressed different preferences for their answers, with their first choice being: MTA pulpotomy is supported by evidence to have a better outcome (61%); patient compliance for 2 appointments might be questionable (27%); there is more evidence to support the efficacy of the one-step indirect pulp cap (6%); and inadequate reimbursement by third party payers for the procedure (6%) (Fig. 6).

Finally, attendees were asked to choose from a list their strongest argument for performing stepwise caries excavation in a young permanent tooth. Responses from pediatric dentists included patient recall to assess symptoms and vitality (41%); patient recall to assess evidence of root maturation (31%); re-entry to ensure dentin remineralization (24%); and provides low-cost treatment for patients needing access to care (4%). Endodontists responded differently, listing in order: patient recall to assess evidence of root maturation (41%); patient recall to assess symptoms and vitality (25%); re-entry to ensure dentin remineralization (25%); payment to practitioner for a second appointment (6%); and provides low-cost treatment for patients needing access to care (3%) (Fig. 7).

Root canal revascularization via blood clotting in necrotic young teeth has been reported in the literature through documented case reports. A major aspect of this technique is usage of disinfecting irrigants such as sodium hypochlorite and chlorhexidine followed by the placement of a special antibiotic

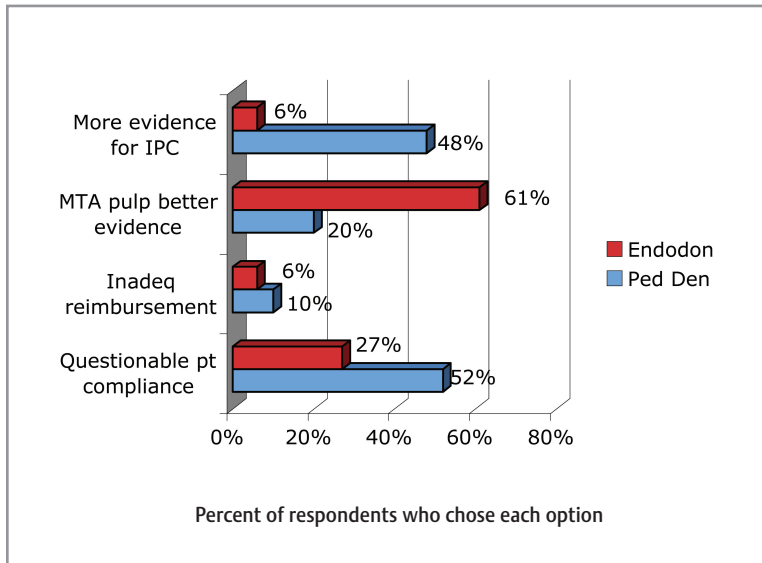


Figure 6. Comparison by specialty of responses to the question: What is your main reason for not performing stepwise excavation in a permanent tooth with an open apex?

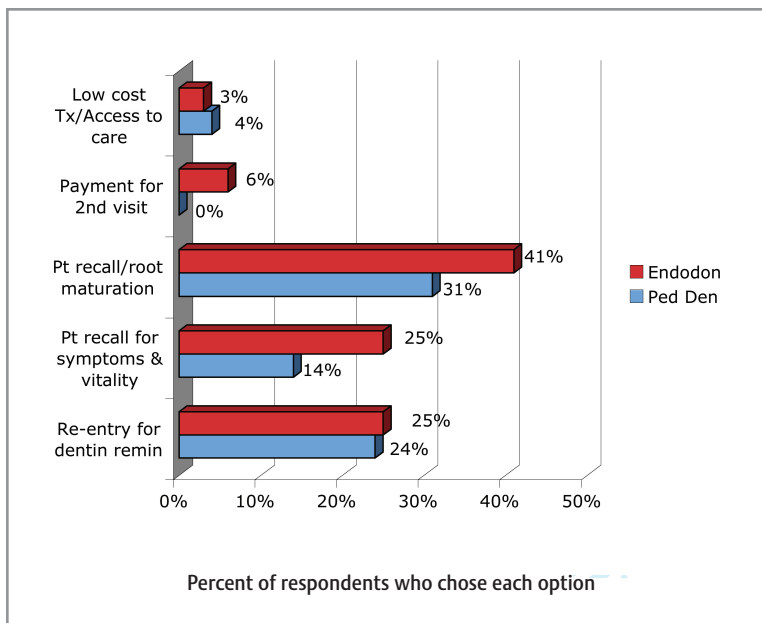


Figure 7. Comparison by specialty of responses to the question: Which of the following would be your strongest argument for performing stepwise caries excavation in young permanent teeth?

mixture. Respondents' opinions expressed through the ARS indicated that the vast majority of pediatric dentists (87%) and endodontists (86%) agreed or strongly agreed that this will be a viable treatment modality for permanent teeth with apical periodontitis within the next 10 years. When asked to choose from a list their major concerns about the procedures, pediatric dentists gave the following responses in descending order: no major concerns at this time (34%); current evidence

is based primarily on case reports (33%); unpredictability (18%); complex case selection criteria (13%); and use of antibiotic paste within the canal (2%). Endodontists gave slightly different ordering to their choices: no major concerns at this time (32%); unpredictability (26%); current evidence is based primarily on case reports (16%); use of antibiotic paste within the canal (14%); and complex case selection criteria (12%). The greatest disagreement between the 2 groups came when asked whether general dentists should perform such procedures if properly educated and trained. Pediatric dentists were favorably inclined, with 74% agreeing or strongly agreeing compared with only 45% of endodontists.

Regeneration of pulp tissue involves tissue engineering therapies by using stem cells, growth factors, and gene therapies. Although this exciting concept is at its early stages of development, the American Association of Endodontists has made regenerative endodontics and revascularization high priority areas for further investigation. ARS questions asked for opinions about whether, from a public health perspective, the future use of stem cells for pulp regeneration in permanent teeth would be an acceptable treatment. Endodontists were more likely to agree or strongly agree at 64%, compared with pediatric dentists at 37%. This question had the highest percentage of uncommitted responders, with 33% of pediatric dentists and 21% of endodontists choosing neutral as a response. Finally, the ARS asked for opinions from an ethical standpoint whether they believed the future use of stem cells for pulp regeneration in permanent teeth would be an acceptable treatment. All of the endodontists (100%) and 96% of pediatric dentists agreed or strongly agreed.

Discussion

Evidence of a merging level of agreement between pediatric dentists and endodontists concerning important issues addressed by the presenters was needed for the symposium planning committee's goal to be met for the collaborative production of pulp therapy guidelines.

Pretest responses indicated significant differences in opinions between pediatric dentists and endodontists concerning the acceptability of most of the pulp therapy treatments under consideration. Beginning with primary tooth pulpotomy agents and formocresol in particular, the vast majority of pediatric dentists initially viewed formocresol pulpotomy as an acceptable pulp treatment for cariously involved primary teeth. Although the pretest question did not ask respondents to choose formocresol from among other pulpotomy agents, as did the ARS questions, 80% of

the pediatric dentists favored its use at that point. Comparing the large number of positive responses initially to formocresol with the ARS responses appears to indicate a changing attitude by pediatric dentists. In the post-symposium ARS questions, only 20% chose formocresol as the best treatment for a primary tooth with reversible pulpitis, and only 15% chose it as the recommended medicament for primary tooth pulpotomy. The way the questions were phrased does not allow direct comparisons between presymposium and postsymposium responses, but these results certainly appear to suggest that formocresol lost popularity. The trend away from formocresol would place pediatric dentists more in agreement with endodontists, who did not favor formocresol either pre- or post-symposium.

There was a different trend apparent when pediatric dentists were asked to comment on the safety of formocresol. Their responses to ARS questions about its documented danger to the patient and whether its potential as a carcinogen should contraindicate its use indicated that they do not believe the case that formocresol is dangerous has been made; only 5% of pediatric dentists and 18% of endodontists agreed. They did appear convinced, however, that it will be replaced because it is too controversial. In that respect, they were in complete agreement with the endodontists. When applying these data to the production of practice guidelines, it is probably most important that the 2 groups be together in their opinions about the need to find and endorse a replacement for formocresol.

Continuing with the issue of primary tooth pulp therapy and with respect to agents used for pulpotomy, post-symposium ARS data indicated that pediatric dentists and endodontists are unified in their overwhelming favor of MTA as the pulpotomy agent of choice. This finding is interesting in light of the fact that there are few well-designed studies examining MTA as a primary tooth pulpotomy agent, even though those studies that are available report positive outcomes in favor of MTA. A second option being examined to replace formocresol pulpotomy as the treatment of choice for cariously involved primary teeth is IPT. Pretest data indicated poor acceptance by the pediatric dentistry respondents, with less than one third agreeing that it was an acceptable substitute technique for pulpotomy. Their post-symposium ARS responses appeared to indicate a marked trend toward a more positive attitude about IPT for primary teeth. More than half would stop caries excavation and perform an IPT rather than a pulpotomy, and 75% agreed that there is evidence that IPT is as successful as pulpotomy in primary teeth. Endodontists started out more positively than pediatric dentists about the procedure for primary teeth and remained that way. The gap between them narrowed, however, as pediatric dentists more frequently expressed positive opinions in their responses after the symposium.

The issue where pediatric dentists and endodontists have the most potential to both be treating the same kinds of teeth is the management of cariously involved young permanent teeth with immature or open apices. This is also the issue

where there has previously been the most divergence of opinion between the 2 groups concerning the appropriateness of IPT for these teeth. The pretest question responses bore out this divergence. Almost all of the pediatric dentists (94%) opined that IPT was an acceptable technique for the "asymptomatic cariously involved young permanent tooth," compared with only approximately two thirds of the endodontists.

Most pediatric dentists and endodontists, however, agreed to a pretest question concerning reversible symptoms of pulpitis contraindicating IPT. By the end of the conference, their opinions about whether such symptoms were a contraindication to IPT changed dramatically. The post-symposium ARS question was worded exactly the same way as in the pretest. Only 8% of endodontists and 7% of pediatric dentists agreed that symptoms of reversible pulpitis were a contraindication to IPT, indicating agreement on this important diagnostic issue.

The IPT procedure in permanent teeth presented at the symposium was the variant called stepwise excavation. The variant involves 2 appointments and aims to eventually remove all affected dentin rather than leave a small amount in the tooth as is performed in the 1-appointment IPT. The procedure has not received wide exposure in the United States because most of the publications on its use and success have appeared in journals not widely read by the practicing community. The post-symposium ARS questions dealt mainly with the stepwise excavation version of IPT and appeared to indicate similar favorable agreement on its use in permanent teeth by both pediatric dentists and endodontists.

It is this topic of the more conservative, cost-effective treatment modality of IPT for cariously involved young permanent teeth that is the most important issue for which the 2 communities must reach agreement and formulate practice guidelines with common language and intent. Many children and young adults who have the highest risk for caries and lesions and who are candidates for IPT have either no payer sources or sources with limited participation by individuals who perform endodontic treatment (general dentists and endodontists). In fact, many cariously involved teeth in these young individuals have open apices and are simply not candidates for complete endodontic treatment. They need to be treated with the more complex and lengthy procedure of vital pulpotomy to obtain root closure followed by complete root canal treatment. The length of time involved in completing the 2 procedures might make them impractical for patients on some payment programs such as Medicaid, where their eligibility might vary during the time period required. The issue of access to care mandates that the 2 groups be unified in agreeing that IPT is an evidence-based and appropriate pulp therapy modality for young permanent teeth with immature or open apices.

Conclusions

In summary, what do endodontists and pediatric dentists agree on? These survey data appear to indicate that the pediatric dentistry and endodontic communities alike agree that formocresol will be replaced as a primary tooth pulpotomy agent, that MTA is the overwhelming first choice to take its place, that IPT in primary teeth holds hope as a replacement for pulpotomy, and that IPT is an acceptable pulp therapy technique for cariously involved young permanent teeth with open apices. In addition, both the endodontists and pediatric dentists believe that pulp revascularization and regeneration will be potentially new exciting treatment modalities in the near future.

Conflict of Interest: N. Sue Seale, DDS, MSD, reports no financial interests or potential conflicts of interest. Gerald N. Glickman, DDS, MS, reports no financial interests or potential conflicts of interests.

Copyright © 2008 American Academy of Pediatric Dentistry and American Association of Endodontists.

This article is being published concurrently in *Journal of Endodontics* July 2008;34:7S. The articles are identical. Either citation can be used when citing this article.