

Conference Paper



Diagnosis Dilemmas in Vital Pulp Therapy: Treatment for the Toothache Is Changing, Especially in Young, Immature Teeth

Joe H. Camp, DDS, MSD

Abstract: *The literature is almost devoid of scientific studies of diagnosis of pulpal pathology in primary and permanent teeth with open apices. Most reports are empirical or retrospective studies without adequate prior knowledge of preexisting conditions or histologic findings leading to the necessity of pulpal procedures. Appropriate diagnostic tests and their effectiveness are documented for both groups. This article reviews the available literature and current techniques of indirect pulp therapy, pulp capping, and pulpotomy for primary teeth and permanent teeth with open apex. The apical barrier with mineral trioxide aggregate followed by root strengthening with bonded composite is reviewed. (Pediatr Dent 2008;30:197-205)*

KEYWORDS: DIAGNOSIS, PULP, PULP CAPPING, PULPOTOMY

Diagnosis in primary and young, permanent, immature teeth varies greatly from that in fully formed permanent teeth. Most of the diagnostic tests used in conventional endodontic therapy are of very little or no value in primary teeth and of limited value in permanent immature teeth. While admittedly poor for diagnosing the degree of inflammation in this group of teeth, diagnostic tests must be performed to obtain as much information as possible before arriving at treatment options.

Diagnostic literature based on scientific studies is almost nonexistent. Most outcome reports are supported by empirical treatment and anecdotal case reports.¹ Many outcome studies are conducted retrospectively on the basis of clinical signs and symptoms and make assumptions regarding the pulpal status before treatment without histologic or bacterial data to support the preoperative diagnosis. Without histologic examination an accurate determination of the extent of inflammation is impossible.² Correlation between clinical symptoms and histopathologic conditions is poor and complicates diagnosis of pulpal health in exposed pulps of children.³

Many of our treatments are based on our diagnosis of the root development stage. Consequently, to properly diagnose and treat primary and young permanent teeth, it is necessary to have a thorough knowledge of normal root formation and the differences between developing and fully formed teeth.

The decision to render conservative vital treatment to allow root formation completion or more radical treatment

such as root canal therapy might hinge on our diagnosis of root development.

According to Orban,⁴ the tooth root's development begins after enamel and dentin formation has reached the cemento-enamel junction (CEJ). Hertwig's epithelial root sheath is formed by the epithelial dental organ, with one tube for each of the future roots. As root formation proceeds apically, each root is wide open, diverging apically and limited by the epithelial diaphragm. Each root's internal surface is lined by odontoblasts. Once root length is established, the sheath disappears, whereas dentin deposition is continued until root formation is completed.

Depending on each root's external anatomy, differentiation into multiple canals might occur. During this formative stage, communication exists between the canals in the form of isthmuses. As growth continues, the opposing walls meet and coalesce, and islands of dentin are formed, which eventually expand to divide the root into separate canals. Continued dentin deposition narrows the canals, and the apex is eventually closed with dentin and cementum, creating apical convergence. Isthmuses and fins extending toward the root's center might persist in fully formed teeth.

In permanent teeth, root formation is not completed until 1–4 years after eruption into the oral cavity. Because of the shorter roots of primary teeth, root formation is completed faster than for permanent teeth. Because the faciolingual width of most roots and canals is greater than the mesiodistal width, apical closure cannot usually be determined radiographically. The x-ray beam is exposed in the faciolingual plane, but the radiograph is read mesiodistally. Because of this anatomy, with the exception of the maxillary central and lateral incisors

Dr. Camp in private practice, Charlotte, N.C., and adjunct professor, Department of Endodontics, University of North Carolina, School of Dentistry, Chapel Hill, N.C. Correspond with Dr. Camp at joecamp@carolina.rr.com

and some single canal lower premolars, radiographs cannot determine apical closure. Therefore, the clinician must rely on time to determine root closure in all other teeth to prevent treatment protocols that cannot be successfully completed without apical convergence.⁵

During this formative period, treatments should be oriented toward maintenance of vitality to allow completion of root formation. Further deposition of dentin will strengthen the roots' thin dentinal walls and help diminish future root fracture.

The root canals of primary teeth differ greatly from those of permanent teeth, and treatment is complicated by apical resorption to allow for eruption of the succeeding teeth. At the time of root length completion, the root canals roughly correspond to the external anatomy's form and shape. At this time, resorption of the roots begins and, combined with additional dentin deposition internally, might significantly change the number, size, and shape of the canals within the primary roots. Continued physiologic, apical resorption of the roots makes the teeth progressively shorter. In addition, resorption on the roots' internal surfaces adjacent to the forming permanent tooth might open other communications with the periapical tissues. These factors complicate establishment of working lengths if root canal therapy is necessary.

In the primary anterior teeth (incisors and canines), the permanent tooth buds lie apically and lingually near the primary roots. Resorption is initiated on the primary root's lingual surface. This causes the apical foramen to move coronally, resulting in a difference in the apical foramen and the anatomic apex and complicating determination of root canal length. One study demonstrated that half of the primary incisor's root might be resorbed lingually before it becomes obvious on a radiograph.⁶ Primary anterior teeth have one simple root canal and rarely have lateral or accessory canals.

The primary molar teeth normally have the same number and position of roots and root canals as the corresponding permanent teeth. At root length completion, most roots have

only 1 canal, but continued deposition of dentin might divide the root into 2 or more canals.⁷⁻⁹ During this time, communication exists between the canals in the form of isthmuses or fins (Fig. 1). Secondary dentin deposition contributes to this change in morphology.^{10,11} Like the permanent molars, most variations occur in the mesial roots of mandibular molars and facial roots of the maxillary molars. Also, these variations are usually in the facial to lingual plane and cannot be visualized on radiographs.^{7,9}

Accessory and lateral canals and apical ramifications of the pulp are common in primary molars.⁸ In addition, other communications between the pulp and the periapical tissues are formed by physiologic resorption of the internal surfaces of the roots adjacent to the permanent tooth buds.

Diagnosis of Pulpal Status in Primary Teeth

As with any dental procedure, a thorough medical history must be completed, and any implications related to treatment must be considered. A child with systemic disease might necessitate different treatment than a healthy one.

The examination should begin with a thorough history and characteristics of any pain, because these are often important in helping to determine pulpal status and eventual treatment. Whereas pain usually accompanies pulpal inflammation, extensive problems might arise without any history of pain. If possible, a distinction between provoked and spontaneous pain should be ascertained. Provoked pain that ceases after removal of the causative stimulation is usually reversible and indicative of minor inflammatory changes. Stimuli include thermal, chemical, and mechanical irritants and many times are due to deep caries, faulty restorations, soreness around a primary tooth nearing exfoliation, or an erupting permanent tooth.

Spontaneous pain is a constant or throbbing pain that occurs without stimulation or continues long after the causative factor has been removed. In a well-controlled histologic study of primary teeth with deep carious lesions, Guthrie et al¹²

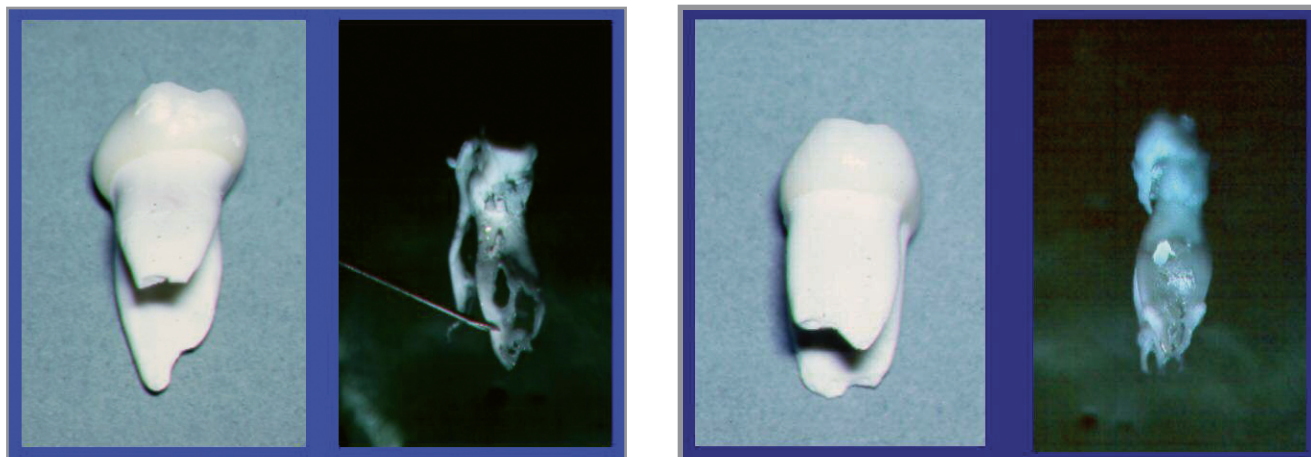


Figure 1. Silicone models of the pulps of 2 primary mandibular second molars. Note the communication between the facial and lingual canals in the mesial roots.

demonstrated that a history of spontaneous toothache is usually associated with extensive degenerative changes extending into the root canals. Primary teeth with a history of spontaneous pain should not receive vital pulpal treatments and are candidates for pulpectomy or extraction.

The clinical examination might produce evidence of pulpal pathosis. Redness, swelling, fluctuance, severe dental decay, defective or missing restorations, and draining parulis might indicate pulpal involvement. Percussion sensitivity might be valuable to the diagnosis, but it is complicated by the reliability of the child's response because of the psychological aspects involved. Tooth mobility might be present normally because of physiologic resorption, and many pulpally involved teeth have no mobility.

Electric pulp tests are not valid in primary teeth.¹ Laser Doppler flowmetry might be of greater help in determining vitality, but this equipment has not been perfected, and the price is prohibitive.¹³

Thermal tests are usually not conducted on primary teeth because of their unreliability.^{1,5}

After the clinical examination, radiographs of good quality are essential. Like permanent teeth, periapical radiolucencies appear at the apices in primary anterior teeth. In primary molars, pathologic changes are most often apparent in the bifurcation or trifurcation areas. Consequently, bite-wing radiographs are often best to observe pathologic changes in posterior primary teeth. Pathologic bone and root resorptions are signs of advanced pulpal pathosis that has spread into the periapical tissues and is usually treatable only with extraction.

Mild, chronic pulpal irritation such as seen in caries might stimulate the deposition of tertiary reactionary dentin over the pulp.⁵ With acute or rapid onset as the disease reaches the pulp, calcified masses might form away from the exposure site. Such calcified masses are always indicative of advanced pulpal degeneration extending into the root canals.¹⁴ Primary teeth with such calcified masses are candidates for only pulpectomy or extraction (Fig. 2).

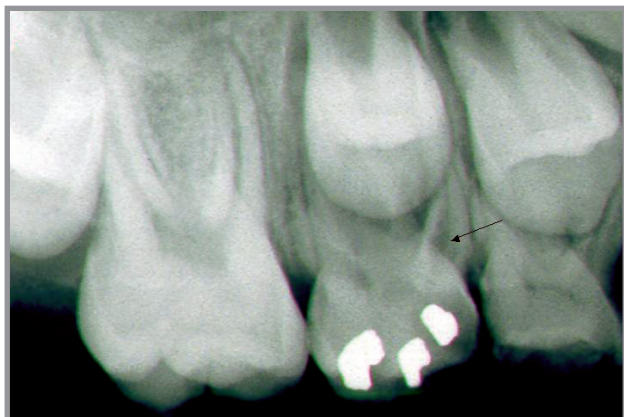

Figure 3. Internal resorption (arrow), as seen in this primary maxillary second molar, will always be perforated and a candidate for extraction. Note the perforated root after extraction and the periodontal probe in the resorptive perforation.

Internal resorption in primary teeth is always associated with extensive inflammation.¹² Because of the thinness of the primary molar roots, if internal resorption can be seen radiographically, a perforation usually exists, and the tooth must be extracted (Fig. 3).

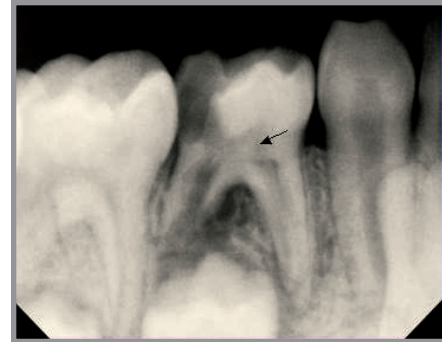
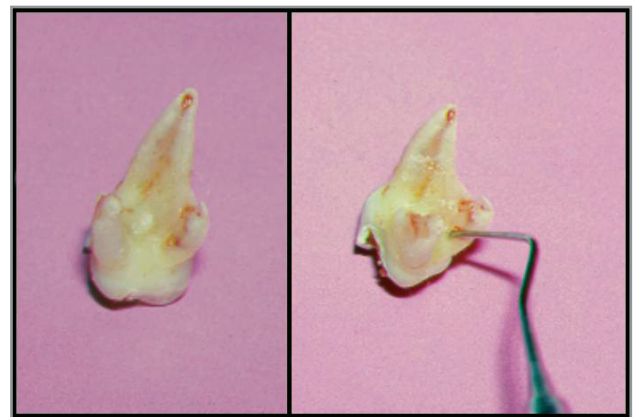


Figure 2. Calcified masses within the pulp (arrow), which form away from the exposure site, and internal resorption (as in this primary mandibular first molar) are indicative of advanced degeneration.

Interpretation of radiographs of primary teeth is always complicated by the presence of the succedaneous tooth and surrounding follicle. Misinterpretation of the follicle can easily lead to an erroneous diagnosis of periapical pathology. Superimposition of the permanent tooth might obscure visibility of the furca and roots of the primary tooth, causing misdiagnosis. Added to this is the normal physiologic resorption process.

Radiographs might also reveal evidence of: previous pulpal treatment; calcification changes in pulp chambers and root canals; oversized canals indicative of cessation of root formation and pulpal necrosis; and after trauma, root fractures, bone fractures, displacement of teeth, imbedded tooth fragments, or foreign bodies in soft tissues.

The size of a pulpal exposure and the amount and color of hemorrhage have been reported as important factors in diagnosing the extent of inflammation under a carious lesion.



Although all carious exposures are accompanied by pulpal inflammation, the larger the exposure, the more likely it is to be widespread or necrotic.

Excessive^{2,5,14,15} or deep purple¹⁵ colored hemorrhage is evidence of extensive inflammation, and these teeth are candidates for pulpectomy or extraction. Hemorrhage that cannot be controlled within 1–2 minutes by light pressure with a damp cotton pellet at an exposure site indicates more extensive treatment is necessary. The same is true after removal of tissue when doing a pulpotomy. A pulpectomy or extraction would then be indicated.

In addition to the aforementioned tests and observations when dealing with traumatic injuries to the primary teeth, other factors must be considered.

Studies have shown that 1 in 3 children receive traumatic injuries to the primary dentition.^{16,17} Because of the less dense bone and shorter roots as compared with permanent teeth, most injuries are displacements rather than fractures. Such injuries might heal normally without sequelae by formation of an amorphous diffuse calcification histologically resembling osteodentin, formation of a partial or complete obliteration of the canal,^{18,19} or result in pulpal necrosis.

In a study of 545 traumatized primary maxillary incisors, Borum and Andreasen²⁰ found that 53 percent of subjects developed pulpal necrosis, and 25 percent developed pulp canal obliteration. The factors found to influence development of pulp necrosis were age of the patient, degree of displacement and loosening, and concurrent crown fracture. Calcific obliteration of the canal was influenced by tooth displacement and amount of root resorption. Crown fracture decreased canal obliteration. They also pointed out that no well-established treatment guidelines exist concerning healing processes and complications in primary teeth.

It has been suggested that the proximity to the succedaneous tooth is an important factor when deciding on treatment for the injured primary tooth. The treatment least likely to damage the permanent tooth should be chosen.^{1,20} Conflicting data exist regarding treatment of primary injuries. Studies have shown no relationship between treating injured primary teeth compared with extraction regarding disturbance of the permanent teeth.^{16,21} Others have shown a tendency toward more extensive disturbances in the mineralization when injured primary teeth were retained.²²

Near universal agreement exists that avulsed primary incisors should not be replanted because of the possibility of danger to the permanent tooth bud.¹

Roughly half of traumatized primary teeth presenting for treatment develop transient or permanent discoloration. These colors vary from yellow to dark gray and usually become evident 1–3 weeks after trauma. Primary teeth with yellow discoloration frequently have radiographic signs of pulp canal calcification and have a low incidence of pulpal necrosis.^{20,23}

Injured primary teeth with dark gray discoloration are reported to have necrotic pulps in 50–82 percent of the cases.

Conversely, necrosis of the pulp occurred in teeth with no discoloration in approximately 25 percent of injured primary incisors.^{20,23-25} Attempts to correlate discoloration to pathologic, radiographic, and histologic changes in the pulps of injured primary incisors present mixed findings. Color change of the tooth alone without other findings is not a reliable indicator of pulpal health.²⁶ Diagnosis of pulp necrosis in primary incisors is primarily based on dark gray color change and radiographic evidence of periapical pathology or lack of root formation (Fig. 4).¹ Schröder et al²⁵ reported development of periapical osteitis in 82 percent of gray discolorations within 1 month. Andreasen and Riis²⁷ have shown that pulp necrosis and periapical inflammation of 6 weeks' duration did not lead to developmental disturbances of permanent teeth. Thus, when diagnosis cannot be established, it is justifiable to wait for further developments.

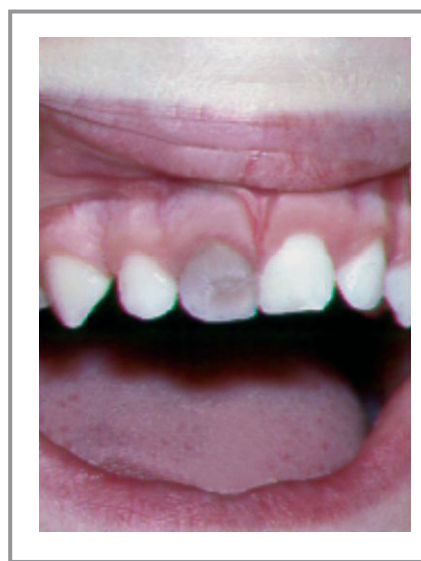

Figure 4. The dark gray discoloration of the crown of this primary maxillary central incisor is indicative of pulpal necrosis.

Diagnosis of Pulpal Status in Permanent Immature Teeth

In teeth with incomplete root formation, correct pulpal and periapical diagnosis is of paramount importance before proceeding with any endodontic treatment because of the devastating result of loss of vitality. Every attempt should be made to preserve the vitality of these immature teeth until maturation has occurred. Loss of pulpal vitality before completion of dentin deposition leaves a weak root more prone to fracture as a result of the thin dentinal walls.

In a 4-year study, Cvek²⁸ noted a significant increase in cervical root fractures in treated immature teeth compared with those with completed roots. In immature teeth, the frequency of fractures was dependent on the stage of root development, ranging from 77 percent in teeth with the least to 28 percent in teeth with the most developed roots.²⁸ Thus, even if treatment is successful, prognosis for prolonged retention of the tooth is

greatly diminished. Loss of vitality before completion of root length will lead to a poorer crown-to-root ratio, with possible periodontal breakdown as a result of increased mobility. Therefore, all treatments in this group of teeth are oriented toward vital procedures. If these more conservative procedures fail, the tooth can still be treated with apexification, apical barrier techniques, or conventional root canal treatment.

Although numerous scientific studies have been reported on the treatment of permanent teeth with immature apices, the literature is almost devoid in the area of diagnosis of pulpal status in this group of teeth.

The diagnosis begins with a thorough medical history and any implications related to the anticipated treatment. The dental history and characteristics of associated pain might be helpful in determining pulpal status. History of any traumatic injury to the facial area should be explored in depth and recorded for future medical, dental, legal, and insurance purposes.

The nature, type, length, and distinction between provoked and spontaneous pain are recorded. Provoked pain caused by thermal, chemical, or mechanical irritants usually indicates pulpal inflammation of a lesser degree and is often reversible. Spontaneous pain, on the other hand, is usually associated with widespread, extensive, degenerative, irreversible pulpal inflammation or necrosis.

The medical and dental histories are followed by a thorough clinical examination. Any areas of redness, swelling, fluctuance, tissue tenderness, dental decay, defective or missing restorations, or fractured or mobile teeth are noted. Presence of discolored crowns or a parulis might indicate pulpal necrosis. The alignment of the teeth, including any infrapositioned or suprapositioned teeth, might provide valuable information.

Electric pulp tests and thermal tests are of limited value because of the varied responses as roots mature. In addition, invalid data might be obtained as a result of the often unreliable responses from children because of fear, management problems, and inability to understand or communicate accurately. Consequently, most diagnoses are made on observation of clinical symptoms and radiographic evidence of pathosis.

Numerous studies²⁹⁻³² have reported the unreliability of electric pulp tests in permanent teeth with open and developing apices. Inconsistent results ranging from 11 percent in 6- to 11-year-olds with completely open apices²⁹ to 79 percent in older children³¹ have been reported. It is also possible to obtain a false-positive in teeth with liquefaction necrosis.³³ Thus, electric pulp tests are of little value during the period of root formation, because the data are not reliable.

Electric and thermal tests were shown to be unreliable after traumatic injury to a tooth, and no response might be elicited even after circulation has been restored.^{34,35} The potential for healing is greater with incomplete root development than in fully formed teeth.

Laser Doppler flowmetry has been reported to be very reliable for diagnosing pulpal vitality.^{13,36,37} In a very detailed

histologic and radiographic study of revitalization of dogs' teeth after reimplantation, Yanpiset et al³⁶ were able to make a correct diagnosis 84 percent of the time. In nonvital pulps, the histologic study proved to be accurate in 95 percent of cases, whereas in vital ones the data were correct 74 percent of the time. This significant difference in readings was observed at as early as 4 weeks. Although the authors pointed out the validity of determining nonvital teeth, they cautioned against relying solely on this test and would only initiate pulpal therapy after observing other signs of pathology.

It has also been shown that blood pigment within a discolored tooth crown interferes with laser light transmission.³⁸ This limitation is significant, because discoloration after trauma is frequent. Also, this equipment has not been perfected for routine dental diagnosis and is cost-prohibitive for the practicing dentist.

Thermal testing with ice and ethyl chloride are of limited value diagnostically. Ice and ethyl chloride have consistently been reported to be inferior to carbon dioxide snow²⁹⁻³² and dichlorodifluoromethane (DDM).^{31,39} Researchers have shown carbon dioxide snow to consistently give positive responses near 100 percent even with open apices.²⁹⁻³²

Thermal tests with heat in permanent teeth with developing apices are of limited value because of inconsistent responses³² and are rarely performed.

Radiographic examination and interpretation are key elements in the diagnosis of pulpal pathology in teeth with developing apices. Good quality periapical radiographs of any involved teeth are used to assess root development and discover periapical rarefaction and root resorption. After traumatic injury, radiographs are essential to determine the presence of fractured bone and roots, displaced teeth, and imbedded foreign objects.

In posterior teeth, bite-wing radiographs are also necessary to detect caries, proximity of lesions to the pulp, previous pulpal treatments, and quality of any restorations.

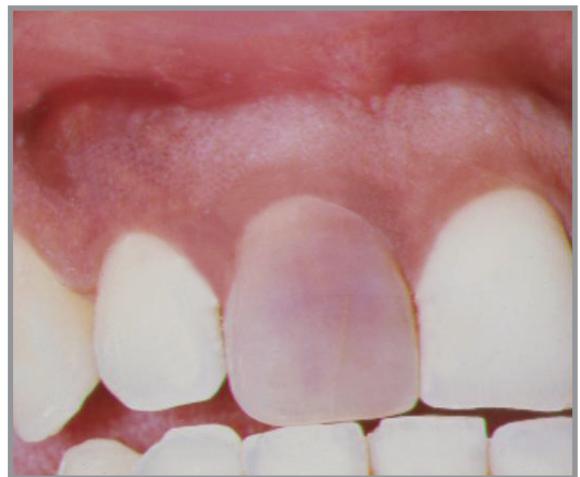

Figure 5. Dark gray discoloration of the crown of this permanent maxillary central incisor indicates pulpal necrosis.

Discoloration of a tooth crown after trauma is a common sequela and one of the foremost diagnostic indicators.⁴⁰⁻⁴² Yellow discoloration is usually indicative of pulp space calcification, and a gray color usually signifies pulpal necrosis (Fig. 5).⁴⁰

Transient coronal discoloration has been reported⁴² in 4 percent of teeth after luxation injuries as a result of vascular damage and hemorrhage immediately after injury. In these cases, it was speculated that pulpal healing depends on the bacterial status. With bacterial infection, healing is unlikely. In this group of teeth, determination of bacterial status could not be ascertained on the basis of coronal discoloration, loss of pulpal sensibility, or periapical rarefaction.⁴²

Transient apical breakdown occurs after displacement injuries and might lead to misdiagnosis.^{42,43} The development of transient periapical radiolucency—together with coronal

discoloration, negative electric pulp test, and cold response up to 4 months—was shown to subsequently regain the original color and normal pulpal responses.⁴³ Transient apical breakdown apparently is linked to the repair process in the pulp and periapical tissues and returns to normal when healing is complete.⁴² Bone loss, which produces the radiolucency, eventually heals with new bone.

Universal agreement exists that immature teeth have the greatest potential to heal after trauma or caries, particularly when the apical foramen is wide open. This group of teeth also has the greatest chance of misdiagnosis and mistreatment. To avoid mistakes, treatment must not be undertaken on the basis of negative responses to pulp testing. Radiographic and symptomatic assessment is currently the principal diagnostic criterion. The following factors are key in making the diagnostic

determination: symptoms of irreversible pulpitis or apical periodontitis; clinical signs of periradicular infection including swelling, tenderness to percussion, mobility, or parulis formation; radiographically detectable bone loss; progressive root resorption; and arrested root development compared with other adjacent teeth.⁴⁴

If doubtful, do not start treatment. Keep the patient under close observation and continue to reassess the diagnostic criteria until a definitive diagnosis can be established.

The treatment of primary and young permanent teeth has changed dramatically in recent years as new materials have been developed and researched. The use of calcium hydroxide (for decades the standard for pulp protection), pulp capping, and pulpotomy procedures in permanent teeth is being replaced with composite resins^{45,46} and mineral trioxide aggregate (MTA) (ProRoot; Dentsply Tulsa Dental Specialties, Tulsa, Okla). Pulp capping with resin composites in monkeys produced the lowest incidence of bacterial microleakage, pulpal inflammation, and incidence of pulpal necrosis when compared with calcium hydroxide and glass ionomer cement.⁴⁶

When compared with calcium hydroxide, MTA produced significantly more dentinal bridging in a shorter time with significantly less inflammation and less pulpal necrosis.⁴⁷⁻⁴⁹ MTA has been shown to be cementoconductive, with attachment of cementoblasts to the material.⁴⁹ Sarkar et al⁵⁰ studied the interactions of MTA, a synthetic tissue fluid, and dentin

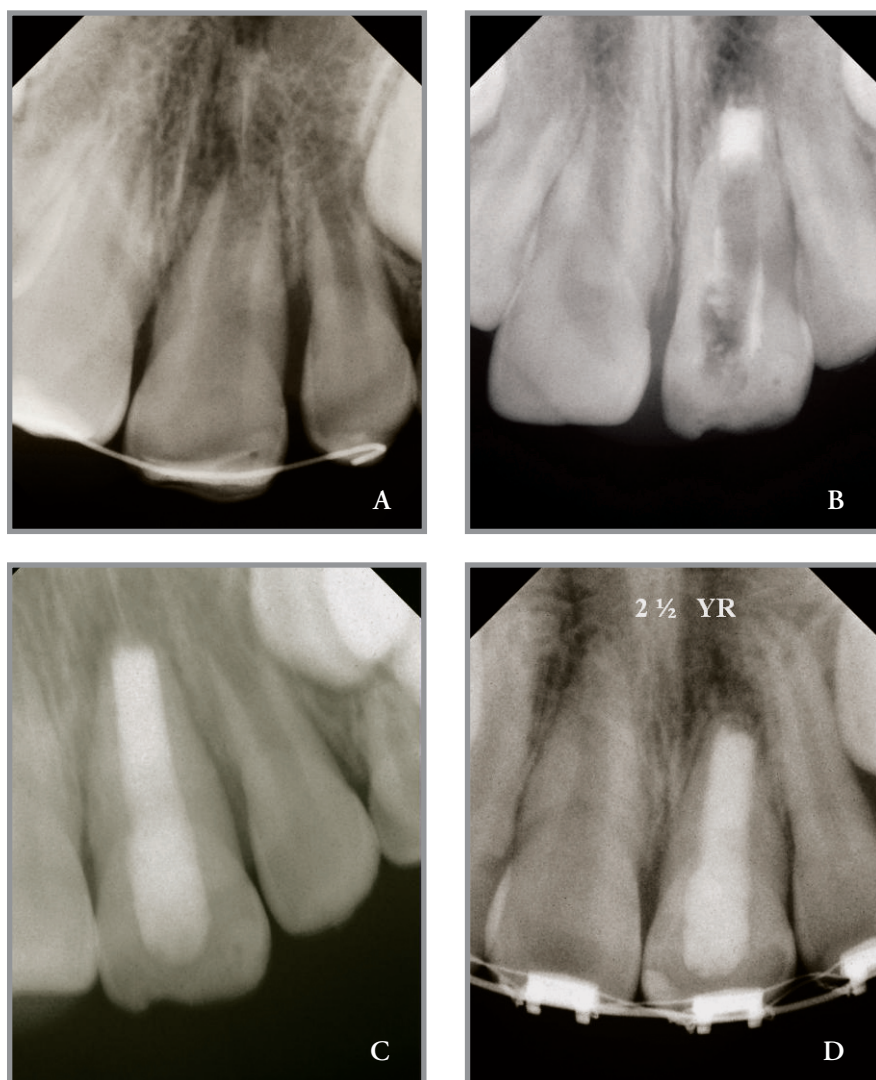


Figure 6. Apical barrier with MTA and strengthening of the thin root with bonded composite. (A) Preoperative radiograph of permanent maxillary left central incisor. The pulp is necrotic, and the apex is open. (B) 4-mm plug of MTA placed at the apex. (C) Remainder of canal restored with bonded composite resin. (D) Two-and-a-half-year follow-up showing covering of MTA with cementum and healing of a periapical lesion.

of extracted teeth. They concluded that calcium from the MTA reacted with phosphate in tissue fluid, producing hydroxyapatite. The sealing ability, biocompatibility, and dentinogenic activity of the material occur because of these physiochemical reactions.

Once considered taboo, vital pulpal treatment of symptomatic permanent teeth with MTA has been reported^{5,51,52} to be successful, allowing continued root development. Stronger roots with greatly improved prognosis for permanent retention are now possible.

Loss of pulpal vitality in open apex teeth in the past led to protracted treatment and often ended in early tooth loss caused by fracture of weak roots. Apical barrier techniques with MTA now allow timely completion of apexification and have eliminated the use of calcium hydroxide, except as a temporary canal disinfectant. The use of MTA as an apical barrier has become the standard for treatment of the open apex pulpless tooth (Fig. 6). The development of bonded composite techniques now allows strengthening of these weak roots to levels of intact, fully formed roots and has virtually ended root fractures (Fig. 6C).⁵³⁻⁵⁶

Revascularization of teeth with necrotic infected canals has been reported by using combinations of antibiotics.^{57,58} The canals are accessed and disinfected with copious irrigation of sodium hypochlorite. The canals are not instrumented. A paste of metronidazole, ciprofloxacin, and minocycline is placed in the canals and left for 1 month. The tooth is re-entered, and endodontic files are inserted through the apices to stimulate bleeding to produce a blood clot at the level of the CEJ. After clotting, MTA is placed over the blood clot, and a permanent external seal is placed. The clot is then revascularized, producing thickening of the canal walls and apical closure.

Stem cell research holds great hope for the future, with the aim of healing impaired dental tissues including dentin, pulp, cementum, and periodontal tissues. By stimulating the body's intrinsic capacities, we will be able to regenerate tissues, allowing further development of teeth and bone or possibly the formation of new teeth to replace those ravaged by decay or lost to traumatic injuries.

References

- Flores MT, Holan G, Borum M, Andreasen JO. Injuries to the primary dentition. In: Andreasen JO, Andreasen F, Andersson L, eds. Textbook and color atlas of traumatic injuries to the teeth. 4th ed. Oxford, UK: Blackwell Munksgaard, 2007.
- Starkey PE. Management of deep caries of pulpally involved teeth in children. In: Goldman HM, Forrest SP, Byrd DL, et al, eds. Current therapy in dentistry. vol 3. St. Louis, MO: Mosby, 1968.
- Mass E, Zilberman U, Fuks AB. Partial pulpotomy: another treatment option for cariously exposed permanent molars. *J Dent Child* 1995;62:342-5.
- Orban BJ. ed. Oral histology and embryology. 4th ed. St Louis, MO: CV Mosby Co, 1957.
- Camp JH, Fuks AB. Pediatric endodontics: endodontic treatment for the primary and young, permanent dentition. In: Cohen S, Hargreaves K, eds. Pathways of the pulp. 9th ed. St Louis, MO: Mosby, 2006:822-82.
- Kamijo Y. Studies on morphological change in the alveolar region of the jaw bone with development of the permanent tooth from the standpoint of clinical anatomy. *Bull Tokyo Dent Coll* 1967;8:41.
- Zurcher E. The anatomy of the root canals of the teeth of the deciduous dentition and of the first permanent molars. New York: William Wood & Co, 1925.
- Hibbard E, Ireland RL. Morphology of the root canals of the primary molar teeth. *J Dent Child* 1957;24:250.
- Finn SB. Morphology of the primary teeth. In: Finn SB, Caldwell RC, Cheraskin E, et al, eds. Clinical pedodontics. 3rd ed. Philadelphia: WB Saunders, 1967.
- Ireland RL. Secondary dentin formation in deciduous teeth. *J Am Dent Assoc* 1941;28:1626.
- Bevelander G, Benzer D. Morphology and incidence in secondary dentin in human teeth. *J Am Dent Assoc* 1943; 30:1079.
- Guthrie TJ, McDonald RE, Mitchell DF. Dental hemo-gram. *J Dent Res* 1965;44:678-82.
- Evans D, Reid J, Strang R, Stirrups D. A comparison of laser Doppler flowmetry with other methods of assessing the vitality of traumatized anterior teeth. *Endod Dent Traumatol* 1999;15:284-90.
- McDonald RE, Avery DR. Treatment of deep caries, vital pulp exposure, and pulpless teeth in children. In: McDonald RE, Avery DR, eds. Dentistry for the child and adolescent. 7th ed. St Louis, MO: Mosby, 1999.
- Pinkham JR. Diagnosis. In: Pinkham JR, ed. Pediatric dentistry: infancy through adolescence. Philadelphia: WB Saunders, 1988.
- Andreasen JO, Ravn JJ. Epidemiology of traumatic dental injuries to primary and permanent teeth in a Danish population sample. *Int J Oral Surg* 1972;1:235-9.
- Glendor U. On dental trauma in children and adolescents: incidence, risk, treatment, time, and cost. *Swed Dent J* 2000;140(Suppl):1-52.
- Robertson A, Lundgren T, Andreasen JO, Dietz W, Hoyer I, Noren JG. Pulp calcifications in traumatized primary incisors: a morphologic and inductive analysis study. *Eur J Oral Sci* 1997;105:196-206.
- Holan G. Tube like mineralizations in the dental pulp of traumatized primary incisors. *Endod Dent Traumatol* 1998;14:279-84.
- Borum MK, Andreasen JO. Sequelae of trauma to primary maxillary incisors: I—complications in the primary dentition. *Endod Dent Traumatol* 1998;14:31-44.

21. Andreasen JO, Ravn JJ. The effect of traumatic injuries to primary teeth on their permanent successors: II—a clinical and radiographic follow-up study of 213 teeth. *Scand J Dent Res* 1971;79:284–94.
22. Selliset N. The significance of traumatized primary incisors on the development and eruption of permanent teeth. *Eur Orthodont Soc Trans* 1970;46:443.
23. Holan G, Fuks AB. The diagnosis value of coronal dark-gray discoloration in primary teeth following traumatic injuries. *Pediatr Dent* 1996;18:224–7.
24. Holan G. Development of clinical and radiographic signs associated with dark discolored primary incisors following traumatic injuries: a prospective controlled study. *Dent Traumatol* 2004;20:276–87.
25. Schröder U, Wennberg E, Granath LE, Moller H. Traumatized primary incisors: follow-up program based on frequency of periapical osteitis related to tooth color. *Swed Dent J* 1977;1:95–8.
26. Croll TP, Pascon EA, Langeland K. Traumatically injured primary incisors: a clinical and histological study. *J Dent Child* 1987;54:401–22.
27. Andreasen JO, Riis I. Influence of pulp necrosis and periapical inflammation of primary teeth and their permanent successors: combined macroscopic and histological study in monkeys. *Int J Oral Surg* 1978;7:178–87.
28. Cvek M. Prognosis of luxated non-vital maxillary incisors treated with calcium hydroxide and filled with gutta-percha: a retrospective clinical study. *Endod Dent Traumatol* 1992;8:45–55.
29. Klein H. Pulp responses to electric pulp stimulator in the developing permanent anterior dentition. *J Dent Child* 1978;45:199–202.
30. Fulling HJ, Andreasen JO. Influence of maturation status and tooth type of permanent teeth upon electrometric and thermal pulp testing procedures. *Scand J Dent Res* 1976;84:286–90.
31. Fuss Z, Trowbridge H, Bender IB, Rickoff B. Assessment of reliability of electrical and thermal pulp testing agents. *J Endod* 1986;12:301–5.
32. Fulling HJ, Andreasen JO. Influence of splints and temporary crowns upon electric and thermal pulp-testing procedures. *Scand J Dent Res* 1976;84:291–6.
33. Ehrmann EH. Pulp testers and pulp testing with particular reference to the use of dry ice. *Aust Dent J* 1977;22:272–9.
34. Ohman A. Healing and sensitivity to pain in young replanted human teeth: an experimental clinical and histologic study. *Odontol Tidskr* 1965;73:166–227.
35. Bhaskar SN, Rappaport HM. Dental vitality tests and pulp status. *J Am Dent Assoc* 1973;86:409–11.
36. Yanpiset K, Vongsavan N, Sigurdsson A, Trope M. Efficacy of laser Doppler flowmetry for the diagnosis of revascularization of reimplanted immature dog teeth. *Dent Traumatol* 2001;17:63–70.
37. Sigurdsson A. Pulpal diagnosis. *Endod Top* 2003;5:12–25.
38. Heithersay GS, Hirsch RS. Tooth discoloration and resolution following a luxation injury: Significance of blood pigment in dentin to laser Doppler flowmetry readings. *Quintessence Int* 1993;24:669–76.
39. Karibe H, Ohide Y, Kohno H, et al. Study on thermal pulp testing of immature permanent teeth. *Shigaku Odontol* 1989;77:1006–13.
40. Bakland LK. Endodontic considerations in dental trauma. In: Ingle JI, Bakland LK, eds. *Endodontics*. 5th ed. Hamilton, Ontario, Canada: BC Decker Inc, 2002, 795–843.
41. Jacobsen I. Criteria for diagnosis of pulpal necrosis in traumatized permanent incisors. *Scand J Dent Res* 1980;88:306–12.
42. Andreasen F. Transient apical breakdown and its relation to color and sensibility changes. *Endod Dent Traumatol* 1986;2:9–19.
43. Cohenca N, Karni S, Rotstein I. Transient apical breakdown following tooth luxation. *Dent Traumatol* 2003;19:289–91.
44. Mackie IC, Hill FJ. A clinical guide to the endodontic treatment of nonvital immature permanent teeth. *Br Dent J* 1999;186:54–8.
45. Cox CF, Suzuki S. Re-evaluating pulpal protection: calcium hydroxide liners vs cohesive hybridization. *J Am Dent Assoc* 1994;125:823–31.
46. Murray PE, Hafez AA, Smith AJ, Cox CF. Identification of hierarchical factors to guide clinical decision making for successful long-term pulp capping. *Quintessence Int* 2003;34:61–70.
47. Junn DJ, McMillan P, Bakland LK, Torabinejad M. Quantitative assessment of dentin bridge formation following pulp-capping with mineral trioxide aggregate (MTA). *J Endod* 1998;24:278.
48. Pitt-Ford TR, Torabinejad M, Abedi HR, Bakland LK, Kariyawasam SP. Using mineral trioxide aggregate as a pulp-capping material. *J Am Dent Assoc* 1996;127:1491–4.
49. Thomson TS, Berry JE, Somerman MJ, Kirkwood KL. Cementoblasts maintain expression of osteocalcin in the presence of mineral trioxide aggregate. *J Endod* 2003;29:407–12.
50. Sarkar NK, Caicedo R, Ritwik R, Moiseyeva R, Kawashima I. Physicochemical basis of the biologic properties of mineral trioxide aggregate. *J Endod* 2005;31:97–100.
51. Schmitt D, Lee J, Bogen G. Multifaceted use of Pro Root MTA root canal repair material. *Pediatr Dent* 2001;23:326–30.

52. Mejare I, Cvek M. Partial pulpotomy in young permanent teeth with deep carious lesions. *Endod Dent Traumatol* 1993;9:238–42.
53. Hernandez R, Bader S, Boston D, Trope M. Resistance to fracture of endodontically treated premolars restored with new generation dentin bonding systems. *Int Endod J* 1994;27:281–4.
54. Katebzadeh N, Dalton BC, Trope M. Strengthening immature teeth during and after apexification. *J Endod* 1998;24:256–9.
55. Lawley GR, Schindler WG, Walker WA, Kolodrubetz D. Evaluation of ultrasonically placed MTA and fracture resistance intracanal composite resin in a model of apexification. *J Endod* 2004;30:167–72.
56. Goldberg F, Kaplan A, Roitman M, Manfre S, Picca M. Reinforcement effect of a resin glass ionomer in the restoration of immature roots in vitro. *Dent Traumatol* 2002;18:70–2.
57. Iwaya SI, Ikawa M, Kubota M. Revascularization of an immature permanent tooth with apical periodontitis and sinus tract. *Dent Traumatol* 2001;17:185–7.
58. Banchs F, Trope M. Revascularization of immature permanent teeth with apical periodontitis: new technique protocol? *J Endod* 2004;30:196–200.

Conflict of Interest: Joe H. Camp, DDS, MSD, is the University Clinical Consultant for Dentsply Tulsa Dental Specialties, a part-time, paid position.

Copyright © 2008 American Academy of Pediatric Dentistry and American Association of Endodontists.

This article is being published concurrently in *Journal of Endodontics* July 2008;34:7S. The articles are identical. Either citation can be used when citing this article.